

1p36 Microdeletion Syndrome: A Case Report

Pınar Zengin AKKUŞ¹, [MD]

Yavuz ŞAHİN², [MD]

Eda UTINE¹, [MD]

Koray BODUROĞLU¹, [MD]

1 Department of Pediatrics, Department of Pediatric Genetics,

2 Department of Medical Genetics at Hacettepe University, Faculty of Medicine

* *Corresponding Author: Pınar Zengin Akkuş, MD, Hacettepe University Faculty of Medicine, Department of Pediatrics, Department of Pediatric Genetics, Sıhhiye, 06100 Ankara, Turkey*

e-mail pinarzengin@hacettepe.edu.tr

Received 31 March 2014; accepted 11 April 2014; published online 28 April 2014

ABSTRACT

1p36 deletion syndrome is one of the most common microdeletion syndromes with an estimated prevalence of 1 in 5000. A 3-year-old girl with intellectual disability and facial anomalies was admitted to the Genetics Outpatient Clinic. The patient was born to consanguineous parents. She had seizures and growth retardation, behavioral problems including aggression and self-injurious behavior. On physical examination, she had low body weight, short stature, and dysmorphic facial characteristics including microcephaly, prominent forehead, deep set eyes, straight eyebrows and micrognathia. Ophthalmologic, auditory and cardiac examinations were normal. Facial dysmorphic features and intellectual disability suggested presence of 1p36 microdeletion syndrome, and this was confirmed by karyotype analysis and fluorescence in situ hybridization (FISH): 46,XX,del (1) (p36.3) (CDC2L1,CEB108-). The condition is caused by a deletion with variable breakpoints at the distal tip of the short arm of chromosome. The deletion may at times be detected by high resolution karyotype, but mostly, FISH analysis is required for definitive diagnosis.

Key words: 1p36 microdeletion, intellectual disability, dysmorphic features

Introduction

1p36 microdeletion syndrome is one of the most common deletion syndromes and can be observed in 1 out of 5000 live births (1). The deletion may occur at variable breakpoints at the distal tip of the short arm of chromosome 1 (2). Herein, we report on a patient who was admitted to genetics department with dysmorphic facial appearance and intellectual disability at 3 years of age, and was diagnosed with 1p36 microdeletion syndrome. This syndrome is a clinically recognizable entity and is a common cause of intellectual disability.

Case Presentation

The patient was born subsequent to a term gestation from second degree consanguineous parents with a birth weight of 2600 gr. Both parents and her brother were healthy and of average height. No other important diseases were known in other members of the family.

The past history revealed that she had seizures and developmental retardation, evident by the age

of 3 months. She was learned to sit with support at 1.5 years and without support at 2 years of age. At 3 years of age, she did not have any comprehensible word. By this age, she was noted to have behavioral abnormality, and was self-injurious and aggressive.

On physical examination at admission, the anthropometric measures were as follows; weight 9.5 kg (below 3rd centile), height 86 cm (3rd centile), and head circumference 43 cm (below 3rd centile). She had dysmorphic facial characteristics including microcephaly, prominent forehead, deep set eyes, straight eyebrows and micrognathia (Figure 1). Ophthalmologic, auditory and cardiac examinations were normal.

Characteristic facial appearance and intellectual disability suggested 1p36 deletion syndrome. Karyotype analysis was performed on GTG-banded metaphase spreads prepared from phytohemagglutinine (PHA) -stimulated peripheral blood lymphocytes after standard culture and chromosome

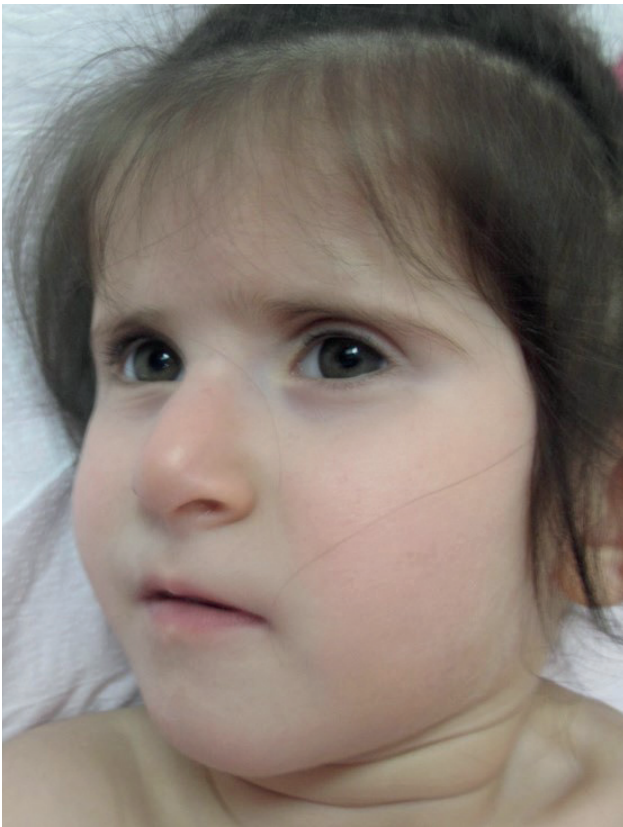

Figure 1. Facial characteristics of the patient. (Consent of the family was obtained for the publication of the photo of the patient.)

preparation techniques. Chromosome analysis was done in 20 metaphases with a resolution of 550 bands, which revealed 46,XX. Fluorescence *in situ* hybridization (FISH) was performed as previously described (3) using commercial probes for 1p36 (Abbott Vysis LSI 1p36 Microdeletion Region Probe, Abbott Molecular Inc. Des Plaines, IL). FISH revealed absence of the terminal signal at the short arm of chromosome 1 (Figure 2), confirming the clinical diagnosis of 1p36 microdeletion. Final molecular karyotype was 46,XX.ish del (1) (p36.3) (CDC2L1-,CEB108-).

The patient was directed to rehabilitation and special education programs. A systematic long-term clinical follow-up was planned. Genetic counseling about this sporadic disorder was provided to the family.

Discussion

The patients with 1p36 microdeletion syndrome have facial and developmental characteristics that are easily recognizable, as it is in the present patient.

Microbrachycephaly, straight eyebrows, epicanthal folds, deeply set eyes, wide and depressed

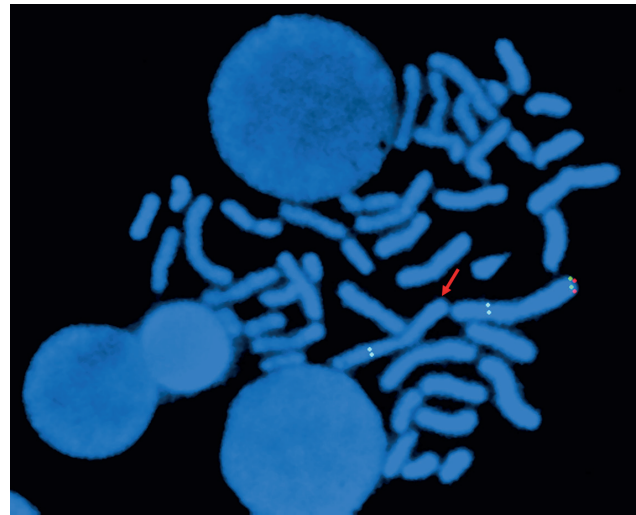


Figure 1. Fluorescence *in situ* hybridization (FISH) analysis showing the deletion in 1p36 region (arrow).

nasal bridge, large and late-closing anterior fontanel, prominent forehead, midface hypoplasia, long philtrum, pointed chin and posteriorly rotated low set ears constitute the typical craniofacial abnormalities of the syndrome (1-2). The present patient had dysmorphic craniofacial features including microcephaly, prominent forehead, deep set eyes, straight eyebrows and micrognathia.

Variable degree of intellectual disability is present in all cases, being severe in majority of cases (2). During neonatal period, 95% of patients have hypotonia, and related feeding problems such as poor sucking, frequent vomiting and gastroesophageal reflux. Starting early in her past history, our patient had marked hypotonia with delayed gross motor developmental steps. All patients have global developmental delay, and language is severely affected. Particularly, expressive language is absent in 75%, usually limited to a few isolated words (17%) or at the level of two-word phrases (8%) (4).

Neurological manifestations of the disorder may also include early onset seizures (44-58%), infantile spasms (20%), and EEG abnormalities, besides developmental delay. Central nervous system anomalies, including enlarged lateral ventricles, cortical atrophy, enlarged subarachnoid space, diffuse brain atrophy, and hypoplasia/thinning or total/partial absence of corpus callosum, may be present in 88% of cases (2). Behavioral abnormalities such as biting hands and wrists (30%), temper tantrums (22%), stereotypic behaviors like hand washing, flapping, head-shaking, banging and rocking (34%), hyperphagia (13%) and reduced social interactions are reported in 50% of cases (4). Seizures, verbal developmental delay,

self-injurious behavior and aggressiveness were the neurological findings present in our patient.

In our patient ophthalmologic, auditory and cardiac examinations were normal and she had no skeletal or genitourinary abnormalities. However, congenital heart defects are commonly seen (71%) in 1p36 microdeletion, such as atrial septal defects (28%), cardiomyopathy (27%), ventricular septal defects (23%), patent ductus arteriosus (12.8%), valvular abnormalities (20.5%), tetralogy of Fallot (7.7%), coarctation of aorta (5.1%) and Ebstein anomaly (2%) (1,2,4). Skeletal anomalies observed in this syndrome may include delayed bone age, rib anomalies (16%), scoliosis (16%), congenital hip dysplasia, valgus deformity of femoral neck, calcaneovalgus, phalangeal hypoplasia of hands (3%), and lower limb asymmetry (1,2,4). Ophthalmologic abnormalities (52%) like strabismus, hypermetropia, myopia, astigmatism, cataract, optic nerve coloboma, hearing loss (47%), renal abnormalities (22%), and genitourinary malformations (25%) such as cryptorchidism, hypospadias, scrotal hypoplasia, micropenis, hypertrophy of clitoris and labia majora have previously been reported in patients with 1p36 deletion syndrome (1,2,4). Hypothyroidism, anal abnormalities, hiatal hernia, pyloric stenosis, abnormal pulmonary segmentation and sacral/coccygeal dimples were also encountered in some of the previously reported cases (1).

1p36 microdeletion syndrome is mostly due to *de novo* terminal deletion, caused by variable breakpoints at the distal tip of the short arm of chromosome 1 (5). There are no correlations between the size of the deletion and the severity of the clinical

characteristics and symptoms (1). Pure terminal deletions, interstitial deletions, complex chromosome rearrangements and derivative chromosomes without common breakpoints were previously reported (6).

Karyotype analysis should be done when the characteristic combination of clinical features described above are detected. In some cases deletion is large enough to be detected by high-resolution karyotype analysis. However, usually there is a need for FISH or array comparative genomic hybridization (aCGH) analysis (1). The deletion usually occurs sporadically, however, karyotype and FISH analyses should be ordered, in case there are two affected siblings. Prenatal testing is indicated for families who had a child with this syndrome or if a parent is a known carrier of chromosome rearrangement.

Management of a patient diagnosed with 1p36 deletion syndrome should include regular measurement of growth parameters, and examinations by cardiology, neurology audiology and ophthalmology, with subsequent follow-up visits planned as required. Patients should also be evaluated for seizures, renal and skeletal abnormalities. Early intervention for intellectual disability, especially for language skills, is essential. Patients should be assigned to special education programs as early as possible. Seizure disorder should be anticipated. In the majority of cases seizures are easily controlled by antiepileptic drugs. Feeding problems should be evaluated and treated appropriately. Early diagnosis, early interventions and appropriate rehabilitation programs are effective for skeletal abnormalities and motor development.

REFERENCES

- [1] **Jones KL:** 1p36 deletion syndrome. In Smith's recognizable patterns of human malformation. 7th edition. Philadelphia, Elsevier Saunders; 2013:.84-5
- [2] **GeneReviews:** 1p36 Deletion Syndrome. <http://www.ncbi.nlm.nih.gov/books/NBK1191/>.
- [3] **Vermeesch JR, Thoelen R, Salden I, et al.** Mosaicism del (8p) /inv dup (8p) in a dysmorphic female infant: a mosaic formed by a meiotic error at the 8p OR gene and an independent terminal deletion event. *J Med Genet* 2003; 40: e93.
- [4] **Battaglia A, Hoyme HE, Dallapiccola B, et al.** Further delineation of deletion 1p36 syndrome in 60 patients: a recognizable phenotype and common cause of developmental delay and mental retardation. *Pediatrics* 2008; 121:404.
- [5] **Heilstedt HA, Ballif BC, Howard LA, et al.** Physical map of 1p36, placement of breakpoints in monosomy 1p36, and clinical characterization of the syndrome. *Am J Hum Genet* 2003; 72:1200.
- [6] **Gajacka M, Mackay KL, Shaffer LG.** Monosomy 1p36 deletion syndrome. *Am J Med Genet C Semin Med Genet* 2007; 145C:346.

