

## Anaesthesia for an Intracranial Aneurysm Clipping in A 93 Year Old Patient

Sennur UZUN<sup>1\*</sup>, [MD]

Ilkay ISIKAY<sup>2</sup>, [MD]

1 Assoc Prof, Hacettepe University Faculty of Medicine Anesthesiology and Reanimation Department, Sıhhiye, Ankara, Turkey,

2 Instructor of Neurosurgery, Hacettepe University Faculty of Medicine Neurosurgery Department, Sıhhiye, Ankara, Turkey

\* Corresponding Author: Sennur Uzun, MD, Hacettepe University Faculty of Medicine, Anesthesiology and Reanimation Department, Ankara, Turkey, 06100.

e-mail: sennuruzun1@gmail.com

Received 7 April 2016; accepted 20 April 2016; published online 25 April 2016

### ABSTRACT

The incidence of subarachnoid hemorrhage from cerebral aneurysm rupture increases with age. Primary predictors of long-term outcome in elderly patients with aneurysmal subarachnoid hemorrhage depend on the general clinical condition at the time of admission and the patient's age. As the incidence of aneurysmal rupture increases with advancing age, clipping decision should be made according to angiographic characteristics, World Federation of Neurological Surgeons (WFNS) grade at admission and the presence of comorbidities. In this case report, a 93 year old, male patient with a ruptured intracranial aneurysm at the middle cerebral artery bifurcation has been discussed in respect to anaesthetic management.

**Key words:** aneurysm, geriatric anaesthesia, neuroanaesthesia

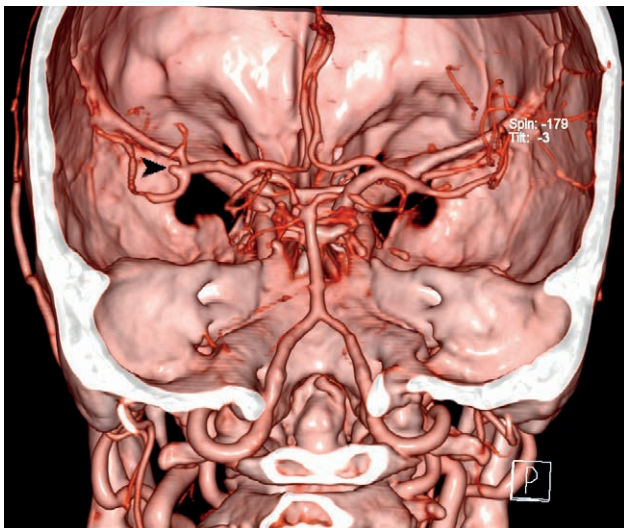
### Introduction

As the population ages, care of elderly patients becomes increasingly important. The incidence of subarachnoid hemorrhage from cerebral aneurysm rupture increases from 15/100,000 to 78/100,000 at the ages 30–59 and 70–88, respectively. Although the comorbidities found in elderly patients complicate the treatment, age is an independent risk factor for poor outcome after aneurysmal rupture [1]. Primary predictors of long-term outcome in elderly patients with aneurysmal subarachnoid hemorrhage depend on the general clinical condition at the time of admission and the patient's age. In a study of 165 patients aged between 70–90 years, Park et al. showed that a significantly greater proportion of patients younger than 75 years of age had favorable modified Rankin Scale (scale for measuring the degree of disability or dependence in the daily activities of people who have suffered a stroke or other causes of neurological disability, mRS, 0–6) outcome after aneurysm rupture treatment [2]. Treatment modalities, namely surgical clipping and endovascular coiling had no effect on the outcomes of the patients [2]. In this case report, we present aneurysmal clipping of a 93 year old patient who was admitted to the emergency department with somnolence and slurred speech.

### Case presentation

In this case report, a 93 year old (50 kg, 170 cm), male patient with an intracranial aneurysm at the middle cerebral artery (figure 1) has been discussed in respect to anaesthetic management. He was admitted to the hospital with somnolence and slurred speech and was evaluated with an angiographic computed tomography which revealed left sided subarachnoid bleeding secondary to the rupture of the middle cerebral artery aneurysm. The patient suffered from hypertension controlled with antihypertensive drugs. Cardiologic consultation did not reveal any additional disease. An echocardiography was performed and global ejection fraction was 60%. He was uncooperative at the operating theatre and unable to talk.

After standard monitorisation with electrocardiogram, pulse oxymetre and non-invasive blood pressure, anaesthesia was induced with 100 mg propofol, 30 mg rocuronium and 25 µg fentanyl. After the intubation, subclavian catheter (7 Fr) and invasive radial artery catheter was introduced and the temperature was monitored. Before the skull pin, a scalp block was performed with 150 mg lidocaine. Anaesthesia was maintained with sevoflurane (1.5, MAC 0.8) and remifentanyl infusion (0.06 µg/kg/min). The anaesthesia and surgery duration were



**Figure 1.** 3D Computed tomography

290 and 250 minutes respectively. The anaesthesia period was stable without any complications. One pack of erythrocyte concentration (300 cc) was transfused as the control hemoglobin was 9 gr/dl during the closure of the dura. Sugammadex 200 mg was used for reversal of the neuromuscular blocking drug. Metamizole (1 gr) and paracetamol (1 gr) were administered for postoperative pain relief. After the extubation, he was transferred to neurosurgery intensive care unit. His early post-operative course was uneventful and he was discharged on the 7<sup>th</sup> postoperative day with mRS score of 2.

## Discussion

As life expectancy increases, the proportion of elderly individuals in community also increases and leads medical care professionals to focus on this age group. With advanced age, the brain becomes more fragile and loses its elasticity. When compared to other locations it is easier to clip middle cerebral artery (MCA) aneurysm since the need for brain retraction is less. In conservative management of patients after an aneurysm rupture the leading cause of death is rebleeding within 3 weeks of the initial bleed. Therefore, early surgical obliteration of ruptured MCA aneurysms gives the patient the best chance for a favorable outcome as we did

Preoperative grade and computed tomographic findings are predictors of favorable outcomes in the 8<sup>th</sup> and 9<sup>th</sup> decades [3]. Advanced age itself does not affect the outcome of the elderly patients who undergo clipping surgery for aneurysmal subarachnoid hemorrhage [4].

The suitable treatment for a safe and effective closure of a ruptured aneurysm in elderly patients

should be decided according to the angiographic characteristics and comorbidity, rather than the patient's age. Park J [2] reported that among elderly patients with a good WFNS (World Federation of Neurosurgical Societies) grade, no statistically significant difference was found in respect to favorable 1-year outcome between the coiling and clipping group. Surgical clipping and endovascular coiling achieved a favorable 1-year outcome in 81.4% and 85.7% of the patients aged 70–75 years with a good WFNS grade, respectively, and 48.3% and 60.6% of the patients > 75 years with a good WFNS grade, respectively [2].

Although endovascular obliteration has become a major form of treatment for elderly patients with aneurysmal subarachnoid hemorrhage (SAH) [5], not all ruptured aneurysms can be treated with an endovascular approach because of tortuous vessels, allergic reaction to contrast medium, and other factors [6]. Additionally, some reports have indicated that clipping surgery achieves better results than coil embolization [7]. Therefore surgical clipping is still an important treatment method for obliteration of a ruptured aneurysm in elderly patients [6]. The percentage of the elderly patients undergoing surgical treatments varied from 7 to 30% of all aneurysmal SAH patients [8].

Geriatric anaesthesia (anaesthesia for patients over 65 year old) is challenging for most of the anaesthetists. This patient group has co-morbidities complicating the primary surgical condition and the anaesthetic management. Our patient had only hypertension which was under control with medication. We performed a scalp block before the placement of skull pins in order to prevent a haemodynamic response to it which prevented the tension response. Geriatric patients are more sensitive to anaesthetic agents. Less medication is usually required to achieve a desired clinical effect and drug effect is often prolonged. Doses of the anaesthesia induction drugs should be adjusted keeping in mind the diminished need and they should be given very slowly. Induction agents doses used for this patient was very low, especially the fentanyl dose (25 µg). Additional to routine neuro-anaesthetic management, we did a scalp block to attenuate the haemodynamic response to skull pin to decrease the need of narcotic medication.

PaO<sub>2</sub> decreases progressively with age because of ventilation-perfusion mismatch and anatomical shunt. Postoperative respiratory complications are most common in geriatric patients. This patient

did not have any pulmonary complication postoperatively. Maintenance of body temperature pre-, intra-, and postoperatively is essential. Shivering may increase oxygen demand above respiratory capacity [9]. Elderly patients take more time to recover from general anaesthesia especially if they were disoriented perioperatively. We heated the patient during the operation by bair-hugger, the temperature was kept between 35.5–36°C.

In a patient with a ruptured aneurysm, the decision of surgery should be taken according to the preoperative general health status and available comorbidities. As the aneurysmal rupture incidence increases with advancing age, clipping decisions should be made according to angiographic characteristics, WFNS at admission and the accompanying diseases.

## REFERENCES

- [1] **Park JH, Kim YI, Lim CY.** Clinical outcomes of treatment for intracranial aneurysm in elderly patients. *J Cerebrovasc Endovasc Neurosurg.* 2014; 16(3): 193-199.
- [2] **Park J, Woo H, Kang D, Kim Y.** Critical age affecting 1-year functional outcome in elderly patients aged  $\geq 70$  years with aneurysmal subarachnoid hemorrhage. *Acta Neurochir* 2014; 156: 1655–1661.
- [3] **Bradac GB, Bergui M, Fontanella M.** Endovascular treatment of cerebral aneurysms in elderly patients. *Neuroradiology* 2005; 47:938–941
- [4] **Proust F, Gérardin E, Derrey S, Lesvèque S, Ramos S, Langlois O, et al.** Interdisciplinary treatment of ruptured cerebral aneurysms in elderly patients. *J Neurosurg* 2010; 112: 1200–1207.
- [5] **Fridriksson S, Hillman J, Saeveland H, Brandt L.** Intracranial aneurysm surgery in the 8th and 9th decades of life: Impact on population-based management. *Neurosurgery* 1995; 37(4):627-632.
- [6] **Hamada J, Morioka M, Miura M, Fujioka S, Marubayashi T, Ushio Y.** Management Outcome for Ruptured Anterior Circulation Aneurysms With a Hunt and Hess Clinical Grade of III in Patients in the 9th Decade of Life. *Surg Neurol* 2001; 56: 294-300.
- [7] **Jain R, Deveikis J, Thompson BG.** Endovascular Management of Poor-Grade Aneurysmal Subarachnoid Hemorrhage in the Geriatric Population. *AJNR* 2004; 25: 596-600.
- [8] **Horiuchi T, Tsutsumi K, Ito K, Hongo K.** Results of clipping surgery for aneurysmal subarachnoid hemorrhage in the ninth and tenth decades of life. *Journal of clinical neuroscience* 2014; 21: 1576-1569.
- [9] **Sturiale CL, Brinjikji W, Murad MH, Lanzino G.** Treatment of Intracranial Aneurysms in Elderly Patients. A Systematic Review and Meta-Analysis. *Stroke* 2013; 44: 1897-1902.

