

Phrenic Nerve Damage After Atrial Fibrillation Ablation Using Second Generation Cryoballoon

Hikmet Yorgun ¹, [MD]
ORCID: 0000-0001-7673-229X

Yusuf Ziya Şener ^{1,*}, [MD]
ORCID: 0000-0001-5151-5133

Metin Okşul ¹, [MD]
ORCID: 0000-0002-4759-4868

Uğur Canpolat ¹, [MD]
ORCID: 0000-0002-4250-170

Banu Evrenos ¹, [MD] ⁶
ORCID: 0000-0003-1425-7432

Ahmet Hakan Ateş ¹, [MD]
ORCID: 0000-0001-5414-7268

Kudret Aytemir ¹, [MD]
ORCID: 0000-0001-9279-8424

¹ Hacettepe University Faculty of Medicine, Cardiology
Department

*Corresponding Author: Yusuf Ziya ŞENER

Resident at Hacettepe University Faculty of Medicine,
Cardiology Department

Address: Hacettepe University Faculty of Medicine,
Cardiology Department, Sıhhiye, ANKARA /TURKEY
e-mail: yzsener@yahoo.com.tr

Phone Number: +90 5058598853 , +90 3123051781

DOI:10.32552/2019.ActaMedica.335

ABSTRACT

Objective: Cryoballoon ablation is a safe alternative to radiofrequency ablation in the treatment of atrial fibrillation. However, phrenic nerve damage is a bothersome complication of the procedure. In this study, we aimed to establish the incidence of phrenic nerve damage during cryoballoon ablation and define the characteristics of affected patients.

Material and Methods: In this retrospective analysis, all patients with atrial fibrillation that underwent cryoballoon ablation between 2013 and 2018 were included into the study. Characteristics and outcomes of patients complicated with phrenic nerve damage were evaluated. Phrenic nerve damage was detected by palpation of diaphragm contractions or observation of reduced diaphragm motility by fluoroscopy during the procedure.

Results: Totally 653 patients were included in the study. Phrenic nerve damage was detected in 3.5% (23/653) of the patients. Median age of the patients with PNP was 56 (25-78) years and 10 patients (43.4 %) were male. The most common ablation site related with phrenic nerve damage was right superior pulmonary vein (18 patients, 78%). Transient phrenic nerve damage was observed in 16 patients (69%) of the patients which resolved within 24 hours after the procedure. In the remaining 5 patients (21%) diaphragmatic contraction was recovered at the 6th month control visit. In 2 patients (10%), phrenic nerve paralysis was still present >1 year visit.

Conclusion: Phrenic nerve damage is not a rare complication of cryoballoon ablation despite all the preventive maneuvers during the procedure and technological developments. However, most of the phrenic nerve damage recovered during the follow-up.

Keywords: Atrial fibrillation, cryoballoon ablation, phrenic nerve damage

Received: 19 December 2018, Accepted: 11 March 2019,
Published online: 30 March 2019

INTRODUCTION

Atrial fibrillation (AF) is the most common chronic arrhythmia all around the world and is an important cause of cardiovascular morbidity and mortality. Isolation of pulmonary vein ostiums by cryoballoon (CB) ablation technique is a safe and effective treatment strategy in patients with both paroxysmal and persistent AF who have ongoing symptoms despite

antiarrhythmic drugs. Developments in technology and increased operator experience improved the outcomes of AF ablation [1].

Phrenic nerve damage (PND) is not a rare complication of CB ablation in patients with AF. PND incidence is reported as 3-11% despite precautions including pacing the phrenic nerve during ablation

and evaluation of diaphragmatic contraction by palpation. PND usually develops on the course of right superior pulmonary vein (RSPV) ablation due to the close anatomical relationship with phrenic nerve but it is reported that it can also occur during the ablation of right inferior pulmonary vein and during left sided ablations [2, 3]. Preclinical studies demonstrated that the main underlying pathological mechanism of PND is Wallerian degeneration. Therefore, PND is a reversible complication in general [3]. Age and the cryoballoon diameter were shown to be associated with the development of PND [4].

In the light of these data, in this study, we aimed to present our single center experience in terms of PND development and characteristics after second generation CB ablation for AF.

MATERIAL and METHODS

Study Population

In this retrospective analysis, all patients with the diagnosis of AF who underwent CB based ablation between January 2013 and June 2018 were scanned

from electronic database. Patients in whom PND developed during or after the ablation procedure were included in the analysis.

Transthoracic and transesophageal echocardiography was performed before the procedure in all patients. Cardiac computed tomography was also performed to assess pulmonary vein anatomy.

Figure 1

a) Right phrenic nerve injury related right hemidiaphragm paralysis is seen in a male patient. PND persisted one year after the procedure.

b) Left hemidiaphragm paralysis secondary to left PNI related with left atrial appendage isolation by cryoballoon ablation. PND resolved during the first year after ablation.

PND was established by the reduced motility of hemidiaphragm detected by palpation during high output pacing of phrenic nerve or noted by radiologically with fluoroscopic views during ablation procedure or chest x-ray after the procedure (Figure -1).

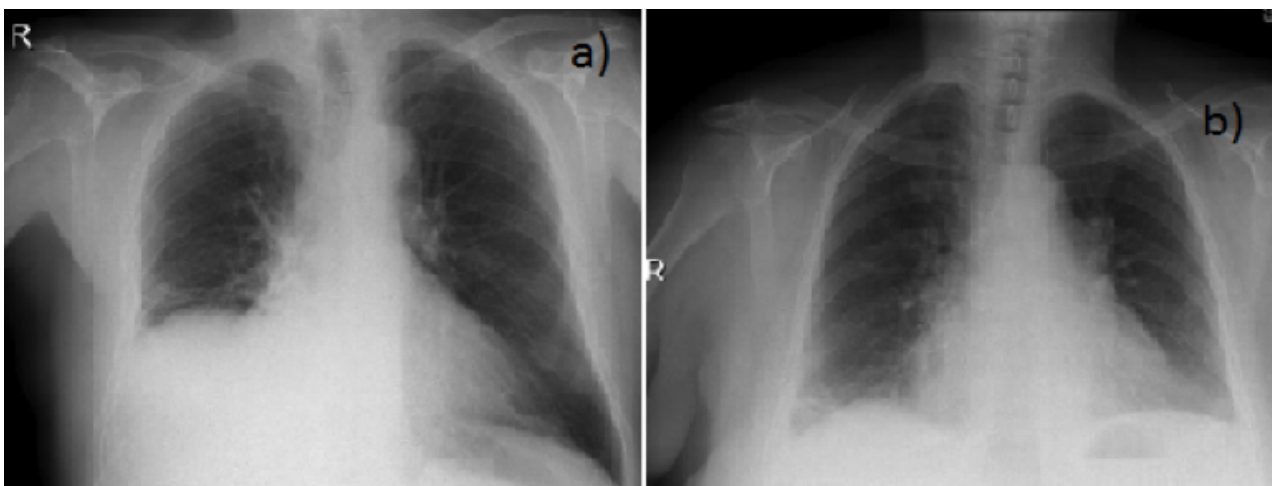


Figure -1

a) Right phrenic nerve injury related right hemidiaphragm paralysis is seen in a male patient. PND persisted one year after the procedure.

b) Left hemidiaphragm paralysis secondary to left PNI related with left atrial appendage isolation by cryoballoon ablation. PND resolved during the first year after ablation.

Cryoballoon Ablation Procedure

Ablation was performed under deep sedation using boluses of midazolam and fentanyl in all patients. Oxygen saturation and electrocardiogram (ECG) were monitored non-invasively throughout the procedure. Right femoral vein and left femoral vein / artery punctures were performed with Seldinger technique. A 6 Fr steerable decapolar catheter was placed into the coronary sinus. Single transseptal puncture was performed under fluoroscopic guidance using a modified Brockenbrough technique

(BRK-1 transeptal needle, St. Jude Medical, St. Paul, MN, USA) and an 8.5 Fr transeptal sheath (Fast-Cath transeptal guiding introducer, St. Jude Medical, St. Paul, MN, USA) was placed into the left atrium (LA). Unfractionated heparin was administered immediately following transeptal puncture at doses adjusted to achieve and maintain an ACT of at least 300 sec. The transeptal sheath was exchanged over a guidewire (0.032 in., 180 cm Super Stiff, St. Jude Medical, St. Paul, MN, USA) for a 12 Fr steerable

sheath (Flexcath Advance, Medtronic, Minneapolis, MN, USA). A 15 or 20 mm circular mapping catheter (Achieve, Medtronic, Minneapolis, MN, USA) was used in all patients to guide the CB within the LA and to attempt real-time recordings from the targeted pulmonary vein (PV). The balloon was inflated in the LA and then directed toward the PV ostia.

Assessment of balloon occlusion was performed by injecting contrast agent through the catheter's central lumen. The duration of each freezing cycle was 180-240 seconds. A bonus freeze was applied in case of PV isolation beyond 60 seconds.

Monitoring Phrenic Nerve Function

The 6 Fr decapolar catheter was placed in the superior vena cava (SVC) to pace the right phrenic nerve with a 2000-msec cycle and a 10-mA output during ablation of the right-sided PVs to prevent PNP. Capture was detected by both observations under fluoroscopy and manual palpation of the abdomen. In the case of phrenic nerve injury (PNP), cryoenergy application was aborted immediately and the balloon was deflated to avoid further damage to the nerve. Diaphragmatic contractions were followed-up for 30 minutes. No additional cryoenergy application was performed to the vein.

In patients with left atrial appendage (LAA) isolation, the left phrenic nerve, because of its neighboring to the LAA, was monitored in all patients. The left phrenic nerve was constantly paced from the LAA using circular mapping catheter throughout the freezing cycle. Also direct palpation of the left hemi-diaphragmatic excursion was performed during phrenic nerve stimulation. In the absence of the capture for left phrenic nerve by circular mapping catheter before freezing, we preferred to use monitoring with fluoroscopy during spontaneous breathing.

In patients with an arrhythmogenic SVC, SVC isolation using CB was also attempted. In such cases, Achieve catheter was placed in the SVC ostium and after inflation of the CB at the SVC-right atrium

border, a prolapsus movement was done with the Achieve catheter and right phrenic nerve was paced from Achieve catheter.

Definition of Phrenic Nerve Damage

PND was classified into 3 groups according to the time until recovery in the diaphragmatic contractile functions. Phrenic nerve injury was defined as any degree of decrease in diaphragmatic movement which was resolved prior to the end of the procedure. Phrenic nerve palsy was defined as loss of diaphragmatic movement evaluated by exhalation and inhalation under fluoroscopy or X-ray which revealed elevated diaphragm lasting less than 3 months and. Phrenic nerve paralysis was defined as palsy lasting > 3 months [5].

Statistical Analysis

Categorical variables are expressed as absolute and relative frequencies. Continuous variables are expressed as mean \pm SD or median and range as appropriate. SPSS version 22.0 program was used for statistical analysis.

RESULTS

Totally 653 patients were included in the analysis. Pulmonary vein isolation was performed in all patients as a routine part of atrial fibrillation ablation. Additionally, left atrial appendage (LAA) isolation was performed in 115 (17.6%) patients while SVC isolation was performed in 19 (2.9%) patients. PND was detected in 3.5% (23/653) of the whole study population. PND developed in 2 (1.7%) patients with LAA isolation and in only 1 (5.2%) patient with SVC isolation. Median age of the patients with PND was 56 (25-78) years and 10 patients (43.4 %) were male. Mean left atrium diameter was 38.5 ± 5.8 mm. Nine patients had hypertension and 3 patients had structural heart disease (Table 1).

Table 1. Baseline characteristics of patients with PND

Age (years), median (min-max)	56 (25-78)
Gender, n (male %)	10 (43.4%)
Hypertension, n (%)	9 (39.1%)
LA (mm), (mean \pm sd)	38.5 ± 5.8
EF (%), (mean \pm sd)	60.8 ± 6.5
Structrual heart disease, n (%);	3 (0.13%)
-HCMP	2 (0.087%)
-DCMP	1(0.043%)
DCMP: Dilated cardiomyopathy; HCMP: Hypertrophic cardiomyopathy; EF: Ejection fraction; LA: Left atrium; PND: Phrenic nerve damage	

Table 2. Characteristics of patients with phrenic nerve damage

Patient No	Age / Gender	Ablation site related with PNP	Duration of PND	Application Number	Application Time	Recurrence
Case 1	25 / Male	RSPV	Persistent	Second	174 sec	No
Case 2	43 / Female	RSPV	Transient	First	130 sec	No
Case 3	70 / Male	RSPV	Persistent	Second	175 sec	No
Case 4	56 / Female	SVC	Transient	Second	230 sec	No
Case 5	63 / Male	LAA	Transient	First	45 sec	Yes
Case 6	53 / Male	RSPV	Transient	Second	194 sec	Yes
Case 7	78 / Female	LAA	Persistent	First	50 sec	No
Case 8	56 / Male	RSPV	Persistent	First	90 sec	Yes
Case 9	68 / Female	RSPV	Persistent	First	55. sec	No
Case 10	35/ Male	RIPV	Transient	First	30 sec	No
Case 11	49 / Female	RSPV	Transient	Second	210 sec	No
Case 12	73 / Female	RSPV	Transient	Second	290 sec	No
Case 13	67 / Female	RSPV	Transient	First	68 sec	No
Case 14	60 / Female	RSPV	Transient	First	115 sec	No
Case 15	46 / Male	RSPV	Transient	Second	275 sec	Yes
Case 16	74 / Female	RSPV	Transient	First	200 sec	No
Case 17	64 / Male	RSPV	Persistent	First	100 sec	No
Case 18	52 / Male	RSPV	Transient	Second	200 sec	No
Case 19	32/ Female	RSPV	Transient	Second	240 sec	No
Case 20	70 / Female	RIPV	Persistent	Second	230 sec	No
Case 21	52 / Male	RSPV	Transient	Second	280 sec	No
Case 22	40 / Female	RSPV	Transient	Second	210 sec	No
Case 23	69 / Female	RSPV	Transient	First	20 sec	Yes

*Abbreviations: RSPV: Right superior pulmonary vein; RIPV: Right inferior pulmonary vein; LAA: Left atrial appendage; LIPV: Left inferior pulmonary vein; SVC: Superior vena cava

PND was occurred mostly during the ablation of RSPV (18 cases) while other associated ablation sites were left atrial appendage (2 cases), superior vena cava (1 case), right inferior pulmonary vein (2 cases) (Table 2). PND was transient (resolved during the procedure) in 16 (69.5%) of the patients. PN palsy was occurred in 7 patients and 3 patients recovered during hospitalization. PN palsy / paralysis was resolved in 2 patients during the 1 year period after the procedure and 2 patients are still in our follow-up with ongoing diaphragma paralysis. Five of the 7 patients with PN palsy / paralysis was related with the ablation of RSPV while other 2 cases were associated with left atrial appendage ablation. PND occurred during the second application in 12 (52%) cases and during the first application in the remaining 11 (48%) cases. PND was developed during the first CB application in 4 patients with PN paralysis while it was during second CB application in the remaining cases. Median time of PND development was 175 (20-290) seconds. This time was 100 (50-230) seconds in patients with PN paralysis while it was 197 (20-290) seconds in PN injury group. Atrial fibrillation recurrence developed in only one patient in the PN injury group and in 4 patients in the PN palsy / paralysis group.

DISCUSSION

Pulmonary vein isolation is a safe and an effective treatment option for drug resistant AF. PND is a well defined complication of CB ablation as a result of close anatomic relationship between pulmonary veins and phrenic nerve [6]. Phrenic nerves originate from 3rd and 5th cervical spinal nerve roots and innervates diaphragm. It is the only nerve that brings motor stimulus to diaphragm. Right phrenic nerve lies over vena cava superior and it is located so closely to the RSPV. The neighborhood of RSPV and right phrenic nerve is the main cause of PND in patients underwent CB ablation [7].

The incidence of PND is reported approximately 6% (1.7%-24.4%) in the literature [8]. Most of patients recover from PND and only less than 0.4% of patients suffer from PN palsy / paralysis and related symptoms 1 year after the procedure [9]. In our cohort, PND incidence was consistent with literature and slightly lower from mean reported incidence rates. Increased operator experience high patient volume may play role in the lower PND incidence in our center.

There are some predictors of PND occurrence during CB ablation. Patients with persistent AF are more prone to PND development. Horizontal and coronal diameter of RSPV ostium and balloon position relative to the cardiac shadow are also predictors of PND development [6]. However, there are still some maneuvers to prevent PND during CB ablation. A single 28 mm balloon use, proximal seal technique and using compound motor action potential decreases the PND development [10-13].

PND is usually transient in patients who underwent CB ablation. Most of the patients recover from PND during the procedure which were defined as PN injury. PND resolves in the 78% of patients during the following 11 months [14]. Similar to previous reports, in most of our patients, PN injury developed which was resolved prior to the end of the procedure. This was mostly due to the termination of the CB ablation when any decrease in diaphragmatic movement observed. Only in a minority of the patients PN palsy or paralysis developed which mostly resolved during the follow-up. In a post-approval study of patients enrolled in the STOP-AF trial, fewer than 1% of patients had PN paralysis after 12 months [15]. In our study, PN paralysis persisted only in 2 patients 1 year after the procedure.

Although most of reported PND cases are related with RSPV ablation; SVC isolation and LAA isolation is also associated with PND. Right phrenic nerve is adjacent to anterolateral wall of SVC and RSPV ostium. Left phrenic nerve lies over the LAA. So operators should be cautious during the isolation of

SVC and LAA; and phrenic nerve functions should be monitored by pacing in the course of procedure [16].

LIMITATIONS

Although our study group was consisted of a large number of patient cohort, it was a retrospective analysis of a single center which might preclude the assessment of real-world incidence of PND. Moreover, our data reflected the incidence PND from high volume and experienced center. Finally, the effect of several preventive measures on PND development was not assessed in our analysis.

CONCLUSION

CB-based AF ablation is a safe option for drug resistant atrial fibrillation; however, PND is still a major concern especially during RSPV isolation. PND usually resolves during the procedure and most of patients with PN palsy / paralysis recover during the first year after the procedure. Further studies evaluating the effect of different maneuvers on the development of PND is needed to better assess the risk of CB-based AF ablation on PND development.

CONFLICT OF INTEREST

We have not any conflict of interest in this study.



REFERENCES

- [1] Koektuerk B, Yorgun H, Koektuerk O, et al. Cryoballoon ablation for pulmonary vein isolation in patients with atrial fibrillation: preliminary results using novel short-tip cryoballoon. *J Interv Card Electrophysiol* 2016; 47: 91-98.
- [2] Miyazaki S, Hachiya H, Taniguchi H, et al. Prospective Evaluation of Bilateral Diaphragmatic Electromyograms During Cryoballoon Ablation of Atrial Fibrillation. *J Cardiovasc Electrophysiol* 2015; 26: 622-28.
- [3] Andrade JG, Dubuc M, Ferreira J, et al. Histopathology of cryoballoon ablation-induced phrenic nerve injury. *J Cardiovasc Electrophysiol* 2014; 25(2): 187-94.
- [4] Guhl EN, Siddoway D, Adelstein E, et al. Incidence and Predictors of Complications During Cryoballoon Pulmonary Vein Isolation for Atrial Fibrillation. *J Am Heart Assoc* 2016; 5: pii: e003724.
- [5] Valay Parikh, Marcin Kowalski. Comparison of Phrenic Nerve Injury during Atrial Fibrillation Ablation between Different Modalities, Pathophysiology and Management. *Journal of Atrial Fibrillation* 2015; 8: 1314.
- [6] Miyazaki S, Kajiyama T, Watanabe T, et al. Characteristics of Phrenic Nerve Injury During Pulmonary Vein Isolation Using a 28-mm Second-Generation Cryoballoon and Short Freeze Strategy. *J Am Heart Assoc* 2018; 7: pii: e008249.
- [7] Parikh V, Kowalski M. Comparison of Phrenic Nerve Injury during Atrial Fibrillation Ablation between Different Modalities, Pathophysiology and Management. *J Atr Fibrillation*. 2015 Dec 31; 8:1314.
- [8] Mugnai G, Chierchia GB, de Asmundis C, et al. Comparison of pulmonary vein isolation using cryoballoon versus conventional radiofrequency for paroxysmal atrial fibrillation. *Am J Cardiol* 2014; 113: 1509-13.
- [9] Chierchia GB, Mugnai G, Hunuk B, et al. Impact on Clinical Outcome of Premature Interruption of Cryoenergy Delivery Due to Phrenic Nerve Palsy During Second Generation Cryoballoon Ablation for Paroxysmal Atrial Fibrillation. *J Cardiovasc Electrophysiol* 2015; 26: 950-55.
- [10] Su W, Kowal R, Kowalski M, et al. Best practice guide for cryoballoon ablation in atrial fibrillation: the compilation experience of more than 3000 procedures. *Heart Rhythm* 2015; 12: 1658–66.
- [11] Franceschi F, Dubuc M, Guerra PG, et al. Phrenic nerve monitoring with diaphragmatic electromyography during cryoballoon ablation for atrial fibrillation: the first human application. *Heart Rhythm* 2011; 8: 1068–71.
- [12] Kowalski M, Ellenbogen KA, Koneru JN. Prevention of phrenic nerve injury during interventional electrophysiologic procedures. *Heart Rhythm* 2014; 11: 1839–44.
- [13] Ghosh J, Sepahpour A, Chan KH, et al. Immediate balloon deflation for prevention of persistent phrenic nerve palsy during pulmonary vein isolation by balloon cryoablation. *Heart Rhythm* 2013; 10: 646–52.
- [14] Guhl E. N., Siddoway D, Adelstein E, et al. Incidence and Predictors of Complications During Cryoballoon Pulmonary Vein Isolation for Atrial Fibrillation. *J Am Heart Assoc* 2016; 5: e003724.
- [15] Knight BP, Novak P, Sangrigoli R, et al. Second generation cryoballoon ablation in paroxysmal atrial fibrillation patients: 12 month safety and efficacy from the STOP-AF post approval study. *Heart Rhythm* 2016; 13: S111.
- [16] Sacher F, Jais P, Stephenson K, et al. Phrenic nerve injury after catheter ablation of atrial fibrillation. *Indian Pacing Electrophysiol J* 2007; 7: 1-6.

