

## Extra-Spinal Tuberculosis Arthritis: Case Report

Madina Ismayilova<sup>1</sup>, [MD]

ORCID: 0000-0003-1390-043

Tuba Ozkan<sup>2,\*</sup>, [MD]

ORCID: 0000-0002-0419-0214

Faruk Ibrahimoglu<sup>3</sup>, [MD]

ORCID: 0000-0001-6001-0700

1 Department of Internal Medicine, Ozel Oz Istanbul Medical Center, Istanbul, Turkey

2 Department of Internal Medicine, Yahyalı Government Hospital, Istanbul, Turkey

3 Department of Physical Medicine and Rehabilitation, Gelisim University, Istanbul, Turkey

Corresponding Author: Madina Ismayilova, Department of Internal Medicine, Ozel Oz Istanbul Medical Center, Istanbul, Turkey

e-mail: medina\_ismail@yahoo.com

DOI:10.32552/2019.ActaMedica.346

### ABSTRACT

This case is reported to increase physicians' awareness of possibility of tuberculosis (TB) in patients with arthritis, as early diagnosis, specific and adequate treatment can be rewarding for maintaining good joint function.

Keywords: Tuberculosis, arthritis

Received: 23 January 2019, Accepted: 28 March 2019,  
Published online: 30 March 2019

## INTRODUCTION

A large number of Extra-Pulmonary Tuberculosis (EPTB) cases visit the medical facilities every year and extra-spinal tuberculosis arthritis is second to spine [1]. However, minorities of patients with articular tuberculosis have concomitant active pulmonary infection and an absence of pulmonary symptoms or radiographic abnormalities should not exclude the diagnosis. Taking an elaborate medical history as well as performing relevant examinations and investigations for possible TB especially in TB-endemic areas will help expedite the diagnostic process in absence of pulmonary symptoms.

## CASE PRESENTATION

The patient is a 16-year old, Arabian female

presented to our department, complaining of pain of the left hip joint limiting movements lasting about 1 year and a palpable mass at the left side formed during last two months. She denies any medical history and respiratory symptoms.

Physical examination revealed tachycardia, high-grade temperature, arthritis of the left hip and palpable mass at the left upper thigh. The laboratory tests showed leukocytes of 13 000 with 63% segmented neutrophils, 45% lymphocytes, C-reactive protein (CRP) of 65,3 mg/dl (normal range 0-6), erythrocyte sedimentation rate (ESR) of 127 mm/h. The urine qualitative test was normal. Serum uric acid was 4,6 mg/dl (normal range 0-7 mg/dl). Magnetic resonance imaging showed intact spinal cord and massive joint effusion of the left hip joint causing extremely distended capsule and coursing

below the iliopsoas tendon indicative of distended iliopsoas bursa measured as 15x9x6 sm. T2 weighted coronal image at the level of the hip joints demonstrates bone marrow edema of the femoral head and acetabulum (Figure 1).

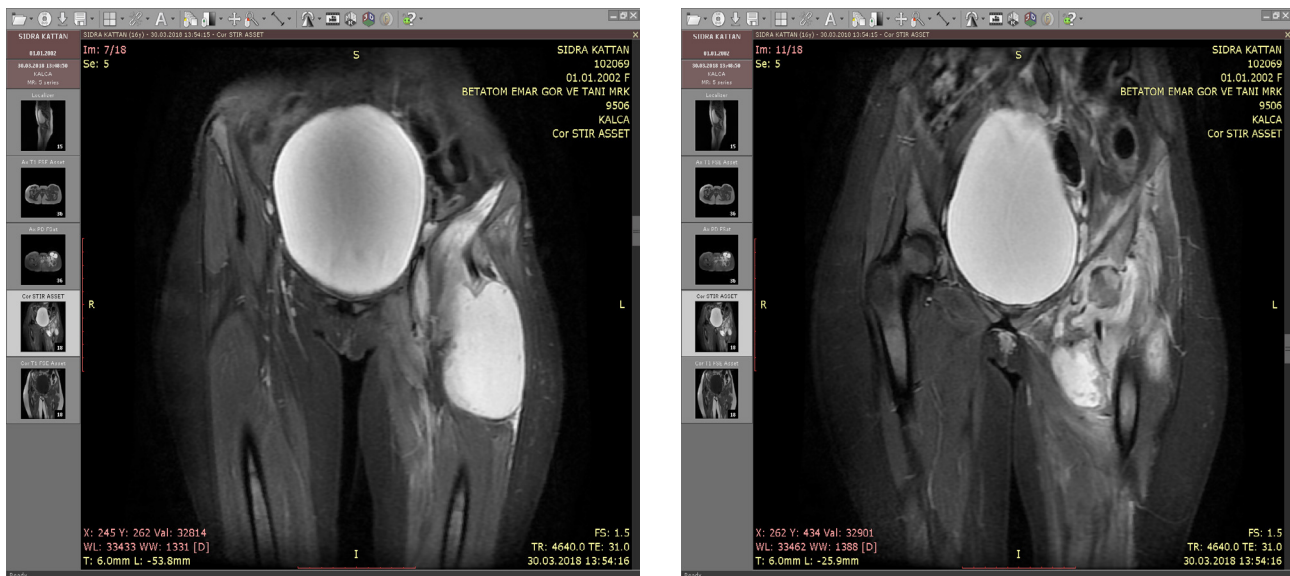


Figure 1. Magnetic resonance imaging showed massive joint effusion of the left hip joint causing extremely distended capsule and coursing below the iliopsoas tendon indicative of distended iliopsoas bursa

A chest radiography was performed, although only bronchial breath sounds without any crepitation were heard during auscultation, X- ray revealed confluent areas of consolidation and nodules that justified our suspicions and further investigation.

A chest computed tomographic scan was performed, showing several small right upper and inferior paratracheal millimetric lymph nodules. The patchy and confluent opacities involved the right upper lob and circumscribed nodules located diffusely throughout right lung were revealed (Figure 2). These findings were interpreted as a possible TB infection.

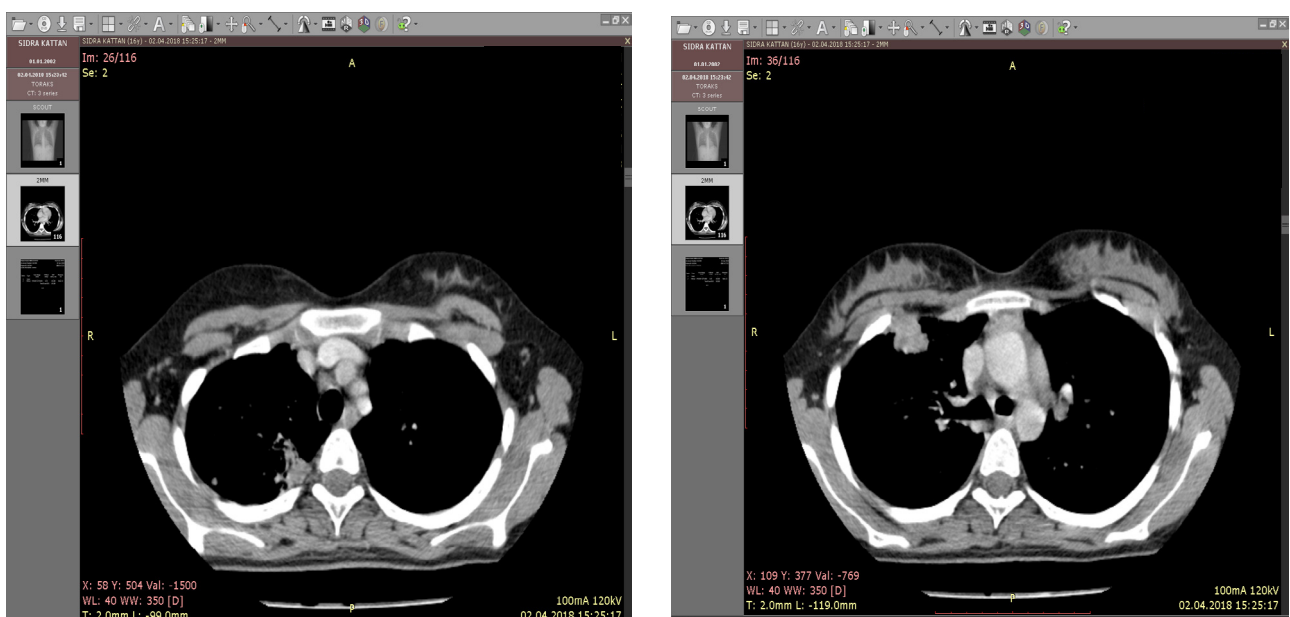


Figure 2. CT showing the patchy and confluent opacities involved the right lung and circumscribed nodules located diffusely throughout right lung

Needle aspiration of the abscess was sent for standard culture and cultures for TB and aspiration cytology evidenced cloudy aspect with more than 50,000 (73% neutrophils; 8% lymphocytes). A tuberculin test done at this time was positive (18 mm). Because the culture results obtained after a longer time and the patient did not produce a sputum bronchoscopy was performed. Although postbronchoscopic sputum sampling was negative for TB the presumptive diagnosis of pulmonary and articular tuberculosis was made, and isoniazid, rifampicin, pyrazinamide, and ethambutol were started. After a month the joint pain and swelling was attenuated. Once the culture for TB yielded a positive result, the patient was referred to an orthopedic specialist.

## DISCUSSION

Tuberculosis is a very prevalent disease in developing countries and multidrug-resistant TB (MDR-TB) and extensive drug-resistant (XDR-TB) remains a public health crisis and a health security threat. Ending the TB epidemic by 2030 is among the health aim of the Sustainable Development Goals. The ongoing civil wars have led to significant damage to the national healthcare system and forced millions to take refuge in neighboring countries, where the majority face wretched conditions. The mentioned circumstances increase the risk of TB development and spreading among refugees and their host communities.

Approximately 10% of extra pulmonary TB involves joints or bone [2]. There are several presentations of osteoarticular TB: Pott's disease, osteomyelitis, peripheral arthritis, bursitis, tenosynovitis and Poncet's disease (PD) [3,4].

PD is an aseptic polyarthritis developing in the

presence of active TB. In contrast to PD, in case of tuberculosis septic arthritis, joint effusions and synovitis with microbiological evidence of the mycobacterium are present. The diagnosis of a TB arthritis is difficult because it can mimic mono-articular rheumatism, fungal arthritis, other granulomatous synovitis and pigmented villo-nodular synovitis [5]. Although the incidence of PD has recently worldwide increased, mainly due to immigration, TB arthritis is still a rare disease that may be overlooked. This may lead to diagnostic delay and significant complications. Crises, including armed conflicts and population displacements, are often associated with up to 20-fold increases in the risk of tuberculosis [6]. Purified protein derivative (PPD) test and IFN-gamma release assays (IGRAs), can be helpful, although can not distinguish between latent and active infection. The absence of positive PPD tests or IGRAs should not exclude a diagnosis. Although the standard antibiotic regimen used to treat pulmonary tuberculosis is widely accepted, the optimal duration of medical therapy for patients presenting with osteoarticular mycobacterial infection is less well defined. The experts recommend that large effusions be drained, and that devitalized tissue and purulence be debrided.

Coordinated efforts to prevent, treat, and limit TB spreading in the highly vulnerable population must be a global health crisis. Such efforts require the engagement of a variety of worldwide partners and are pivotal in promoting the accomplishment of the ambitious targets of WHO's new post-2015 Global TB Strategy, the End TB Strategy.

## CONFLICT OF INTEREST STATEMENT

There are no conflicts of interest.

## REFERENCES

- [1] Malaviya AN, Kotwal PP. Arthritis associated with tuberculosis. *Best Pract Res Clin Rheumatol* 2003; 17: 319-43.
- [2] A.R. Lesic, D.P. Pesut, L. Markovic Denic, et al. The challenge of osteo-articular tuberculosis in the twenty-first century: a 15-year population-based study. *Int J Tuberc Lung Dis* 2010; 14: 1181-86.
- [3] A. Ozgul, O. Baylan, M.A. Taskaynatan, et al. Poncet's disease (tuberculous rheumatism) two case reports and review of the literature. *Int J Tuberc Lung Dis* 2005; 9: 822-24.
- [4] O.P. Seung, W. Sulaiman. Osteoarticular tuberculosis mimicking rheumatoid arthritis. *Mod Rheumatol* 2012; 22: 931-35.
- [5] Shrestha Om. P, Prakash Sitoula, Hosalkar HS, et al. Bone and Joint Tuberculosis. *University of Pennsylvania Orthopedic Journal* 2010; 20: 23-28.
- [6] Kimbrough W, Saliba V, Dahab M, et al. The burden of tuberculosis in crisis-affected populations: a systematic review. *Lancet Infect Dis* 2012; 12(12): 950-65.

