

Our Experience in Hepatoblastoma Surgery

Onder Ozden¹, [MD]

ORCID: 0000-0001-5683-204X

Seref Selcuk Kilic ¹,[MD]

ORCID:0000-0002-1427-0285

Abdullah Ulku ², [MD]

ORCID: 0000-0001-5180-1543

Gülay Sezgin ³,[MD]

ORCID: 0000-0003-2396-5692

Recep Tuncer ¹, [MD]

ORCID: 0000-0003-4670-8461

¹Cukurova University, Department of Pediatric Surgery, Adana, Turkey

² Cukurova University, Department of General Surgery, Adana, Turkey

³Cukurova University, Department of Pediatric Hematology and Oncology, Adana, Turkey

Corresponding Author: Onder Ozden, MD, Asst. Prof. Cukurova University, Department of Pediatric Surgery, Adana, Turkey
Tel: +90 532 3104769
e-mail: drozden@hotmail.com
DOI:10.32552/0.ActaMedica.354

Received:26 April 2019, Accepted: 15 March 2020,
Published online: 30 March 2020

ABSTRACT

Objective: In this study, we aimed to present our patients with hepatoblastoma who had undergone surgery.

Materials and Methods: The patients who had been operated for hepatoblastoma in the last ten years at Çukurova University Hospital were included in the study. The age, gender, complaints, blood alpha-fetoprotein level, whether neoadjuvant chemotherapy was administered, size, stage, surgical findings, distant metastasis, postoperative complications, outcome, and mortality were assessed.

Results: We operated on 22 patients with hepatoblastoma in the last ten years. We could access data of 17 patients. The mean age of the patients was 22 months (4-96 months). 88% of the patients were aged younger than 5 years and 76% younger than 3 years. Seven patients were male, and ten were female. Fourteen patients presented with abdominal distention and swelling. One patient was admitted to the hospital with weight loss, one with diarrhea and one with a fever. In the first evaluation, eight patients were in stage 2 and nine in stage 3 according to the PRETEXT staging. We did not have any stage 1 or 4 patients. Alpha-fetoprotein level levels were high in 16 patients. The mean size of the mass was 11.5 cm at the first evaluation. One patient underwent surgery for trans-arterial chemoembolization since the tumor could not be excised after chemotherapy; we were able to excise the tumor totally following trans-arterial chemoembolization. Two patients had portal vein thrombosis and one was excised during surgery. Seven patients had undergone right, three patients right-expanded, three patients left-expanded, one patient segmental 6-7, and three patients left hepatectomy. Distant metastases were present in two patients (lungs). Mortality occurred in one patient.

Conclusion: Multidisciplinary approach is fundamental in hepatoblastoma and other malignant masses. Not only pediatric oncology but also alternative treatment options such as trans-arterial chemotherapy should be considered.

Keywords: Pediatric, hepatoblastoma, clavien-dindo score

INTRODUCTION

Hepatoblastoma is the most common malignant hepatic tumor in childhood and the third most common solid tumor following nephroblastoma and neuroblastoma in children under three years of age [1,2]. In Western countries, 1.5 / 1.000.000 new cases are seen in children aged 15 years and younger [3]. Historically, it was first described by Willis in 1898. Regarding the treatment of hepatoblastoma,

surgery (complete resection) plays an essential role besides chemotherapy and radiotherapy [4,5]. A better understanding of liver anatomy has reduced surgical complications, and, due to innovations in chemotherapy, overall survival has increased from 35% to 83% [6]. In this study, we aimed to present the results of our patients with hepatoblastoma who had undergone surgery.

MATERIALS and METHODS

We retrospectively evaluated the data of children under 18 years of age who had been operated for hepatoblastoma at Çukurova University Balcalı Hospital. This study was approved by the local ethics committee and was executed under the Declaration of Helsinki prepared by The World Medical Association. The diagnosis of hepatoblastoma was made histopathologically. The patients' data were retrieved from the Cukurova University Registry.

The age at the time of diagnosis, the gender, complaints, the blood alpha-fetoprotein (AFP) level, whether neoadjuvant chemotherapy was administered, chemotherapeutic drugs, the dimensions of the mass, the stage, surgical findings, the presence of distant metastases, follow-up and mortality were evaluated. For evaluation of the complications, the Clavien-Dindo scoring was used [7,8]. The reduction of the mass size of the patients after chemotherapy was also evaluated.

Surgical Technique:

Anatomical resection was the preferred surgical technique for hepatoblastoma. A non-anatomical resection was only performed in patients who were not suitable for anatomical resection. The surgical technique was described as follows: after abdominal exploration, the triangular ligament and ligamentum teres were dissected and cut, and the falciform ligament was ligated. Then, the liver could be mobilized. The short hepatic veins were bound and ligated; the liver was cleaved from the vena cava. The dissection of the portal hilum started with cholecystectomy, and then, the portal hilum was exposed. First, the hepatic artery was double-ligated and cut. Then, the extrahepatic ligation of the portal vein was performed. Last, the hepatic bile duct was exposed, ligated, and cut. After the formation of a demarcation line, parenchymal resection proceeded, and was performed by the clamp-crash technique. The hepatic vein was finally ligated and sutured with nonabsorbable sutures. The operation

was ended after controlling for bleeding and bile leakage.

RESULTS

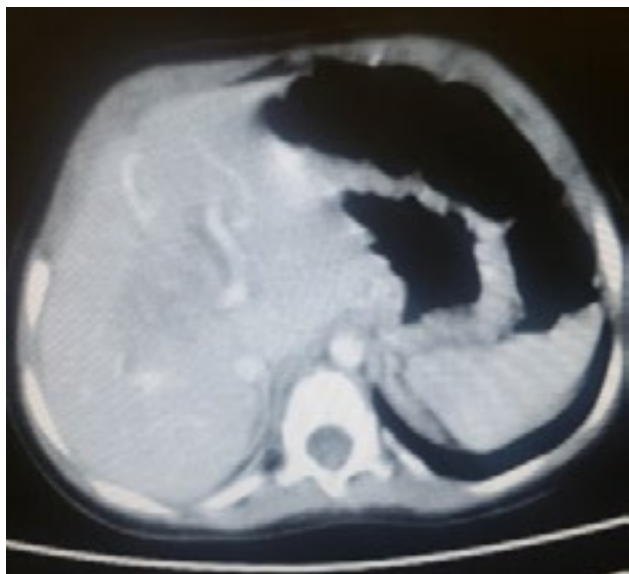
This retrospective study was performed at Çukurova University. Twenty-two children with hepatoblastoma were included in the study. Data of 17 patients were available. Seven patients were male, and 10 were female. The mean age of the patients was 22.4 months (4-96 months).

The complaints during admission to the hospital involved distention in 14 patients, diarrhea in one patient, weight loss in one patient, and fever in one patient. The blood AFP level was elevated in all but one patient. The median AFP value at the time of diagnosis was 37500 ng/ml (47-277000). Histopathological examination of the patient with the normal AFP level was mixed type.

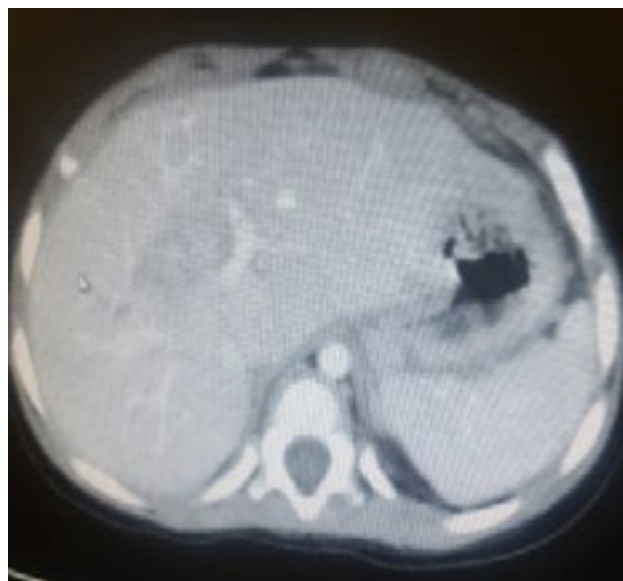
The staging of the patients was performed according to the PRETEXT system. We did not have any stage 1 or 4 patients. Eight patients were in stage 2, and 9 patients were in stage 3 — one of our patients with stage 2 presented with involvement of the caudate lobe. Sixteen of the patients were diagnosed by a tru-cut biopsy performed by the Department of Interventional Radiology.

These 17 patients were operated on following administration of neoadjuvant chemotherapy. One patient was initially operated on without administering neoadjuvant chemotherapy. This patient had mostly cystic tumor in the liver. One patient underwent an emergency operation for hemorrhage after the tru-cut biopsy. Before the emergency operation, the interventional radiologist performed arterial embolization, but the bleeding could not be taken under control and then, tumor excision was successfully performed. The tumor of one patient who received neoadjuvant chemotherapy was not resectable. This patient was administered trans-arterial chemotherapy by the Department of Interventional Radiology. For chemoembolization, 40 microns-30 mg of doxorubicin was administered via the hepatic artery. After trans-arterial chemoembolization (TACE), the patient was re-evaluated and then the tumor was observed for its appropriateness

regarding surgical resection. The tumor was resected totally (Figure 1).



Before TACE



After TACE

Figure 1: Computed tomography images of unresectable tumor before and after TACE

As neoadjuvant chemotherapeutics, 15 patients received cisplatin, 5-fluorouracil, and vincristine. Two patients received cisplatin and Adriamycin. The median number of neoadjuvant chemotherapy cures was 6 (4-10).

The mean tumor diameter was 10 cm (8-16 cm) at the time of diagnosis. The mean tumor diameter following neoadjuvant chemotherapy, but before surgery was 5 cm (3-7 cm). The mean tumor diameter was found to be reduced by 56.1% after receiving neoadjuvant chemotherapy.

Seven patients had undergone a right hepatectomy, three a left hepatectomy, three a right-expanded hepatectomy, three a left-expanded hepatectomy, and one patient had undergone segmentectomy. Anatomical excision was performed in 16 patients. In one patient, however, there was a thrombus in the portal vein together with collateral portal veins. Since a safe anatomical resection could not be performed because of the presence of collateral portal veins, a segmentectomy was performed in this patient. In another patient with hepatoblastoma in the left lobe, a portal venous thrombus located mainly within the left portal vein was identified

during the operation, and then, the thrombus was excised together with the tumor.

The median operation time was 6 hours (4-11 hours). Distant metastases were present in three patients, and all metastases involved the lungs.

Postoperative complications of all patients were recorded according to the Clavien-Dindo Scoring system. The number of patients having Clavien-Dindo grade of 1 was 9, Clavien-Dindo grade of 2 was 7, and Clavien-Dindo grade of 5 was 1; one patient had a fatal outcome.

Liver transplantation was performed in one patient. This patient had initially undergone a right hepatectomy. Then, however, the tumor recurred in the left hepatic lobe. The patient is still followed up uneventfully.

DISCUSSION

Management of hepatoblastoma has shown significant improvement over the last 30 years. The presence of effective chemotherapeutic agents, understanding the anatomy of the liver better, more reliable surgery, together with better anesthesia and

post-operative care, have significant roles in such improvement [9].

Hepatoblastoma is the third most common malignant tumor in children under 3 years of age, and its prevalence in children is 1.5 / 1 000 000 [10]. Several groups were established and published guidelines to improve the treatment of children with this rare tumor and to improve their quality of life. These groups are the International Society of Pediatric Strategy Group (SIOPEL), the Children's Oncology Group (COG), the German Pediatric Hematology-Oncology Group (GPOH), and the Japanese Pediatric Liver Tumor Study Group (JPLT). Especially the SIOPEL guideline is the most extensively followed one [11]. We also follow the guideline of the SIOPEL group regarding the diagnosis, staging, and treatment of hepatoblastoma.

SIOPEL recommends and uses the PRETEXT staging system, whereas COG uses the Evans' staging system [12]. According to the PRETEXT staging system, which is based on radiological imaging before surgery, the liver is divided into four different sectors as lateral (Couinaud segment 2-3), medial (Couinaud segment 4), posterior (Couinaud segment 6-7) and anterior (Couinaud segment 5-8) [13]. According to the involvement of these segments, PRETEXT defines four stages. The Evans' staging system used by the COG group is a post-operative surgical-pathological staging system.

Hepatoblastoma is a chemo-sensitive tumor, and Cisplatin is the most crucial drug for chemotherapy. Chemotherapy can eliminate distant metastasis, reduce mass volume, and convert the tumor features from unresectable to resectable [9,14]. In some studies, it was found that chemotherapy with cisplatin provided tumor volume reduction by 70-90%. In our study, we found that the diameter of the mass was reduced by 50%. Therefore, we also confirmed that neoadjuvant chemotherapy was effective.

From the surgical aspect, SIOPEL and COG are

different. While COG primarily recommends surgery, SIOPEL recommends surgery after neoadjuvant chemotherapy. We also performed a trucut biopsy initially, in accordance with the guideline of SIOPEL. The guidelines do not recommend a non-anatomical or segmental resection for hepatoblastoma [11]. Only in one patient in whom an anatomical resection had been impossible to achieve, a non-anatomical resection was performed. All other patients had undergone anatomical resections, in accordance with the guidelines.

Patients who receive chemotherapy and who are not eligible for surgery may undergo liver transplantation. The overall survival increased from 25% to 90% with liver transplantation in hepatoblastoma [15]. Alternative treatments other than liver transplantation are also available. The most important one among such alternative treatments is TACE. The liver is blooded from two systems, the hepatic artery and the portal vein. The portal vein provides 75-80% of the blood supply to the liver. However, hepatoblastoma maintains its blood supply mainly from the hepatic artery [16,17]. In TACE, a variety of chemotherapeutic agents, mainly Cisplatin or Doxorubicin, are administered directly to the tumor by catheterizing the hepatic artery and selectively intercepting the tumor's artery. TACE may enable resectability of the tumor, a reduction in the need for liver transplantation, and may be used as a bridge to liver transplantation or for palliation [11]. There are some other alternative treatment methods that are commonly used in adult liver tumors, such as ethanol injection, radiofrequency ablation, and laser ablation.

Clavien-Dindo classification is a scoring system that shows the complication status of patients after surgery. This scoring system has seven grades shown under five main titles (Table 1) [7,8]. The distribution of the grades of our patients regarding the Clavien-Dindo classification were presented in Table 1.

Table 1. Clavien- Dindo Scoring system definition and number of the patients

Grades	Definition	Number of the patients
Grade I	Any deviation from the normal postoperative course without the need for pharmacological treatment or surgical, endoscopic and radiological interventions Allowed therapeutic regimens are: drugs as anti-emetics, antipyretics, analgesics, diuretics and electrolytes and physiotherapy. This grade also includes wound infections opened at the bedside.	9
Grade II	Requiring pharmacological treatment with drugs other than such allowed for grade I complications. Blood transfusions and total parenteral nutrition are also included.	7
Grade III	Requiring surgical, endoscopic or radiological intervention	Nil
- IIIa	Intervention not under general anesthesia	Nil
- IIIb	Intervention under general anesthesia	Nil
Grade IV	Life-threatening complication (including CNS complications)* requiring IC/ICU-management	Nil
- IVa	single organ dysfunction (including dialysis)	Nil
- IVb	Multi organ dysfunction	Nil
Grade V	Death of a patient	1

There were no complications requiring endoscopic or radiologic intervention in our study. In our study, in the postoperative period, 41% of the patients required blood transfusion because of low blood hemoglobin levels. This ratio was like the ratios reported in the literature. There were no complications requiring reoperation either. However, this rate was around 10% in the literature [18]. This difference may be explained due to the low number of patients in our study.

This was a retrospective and single-center study. Although the total number of patients was higher than those of single-center studies in the literature, it was too small to allow statistics to be performed. In conclusion, hepatoblastoma is the most common

malignant liver tumor in childhood. Hepatoblastoma patients should be evaluated with a multidisciplinary perspective. According to our complication rates, an anatomical resection may be performed safely. Also, trans-arterial chemoembolization is a method that may be used in patients in whom the tumor cannot be totally removed.



CONFLICT OF INTEREST

There is no conflict of interest for all authors.

FUNDING

No funding was used for this study.



 REFERENCES 

- [1] Chen WJ, Lee JC, Hung WT. Primary malignant tumor of liver in infants and children in Taiwan. *J Pediatr Surg* 1988; 23(5): 457-61.
- [2] Ni YH, Chang MH, Hsu HY, et al. Hepatocellular carcinoma in childhood. Clinical manifestations and prognosis. *Cancer* 1991; 68(8): 1737-41.
- [3] Aronson DC, Czauderna P, Maibach R, et al. The treatment of hepatoblastoma: Its evolution and the current status as per the SIOPEL trials. *J Indian Assoc Pediatr Surg* 2014; 19(4): 201-07.
- [4] Sunil BJ, Palaniappan R, Venkitaraman B, et al. Surgical Resection for Hepatoblastoma-Updated Survival Outcomes. *J Gastrointest Cancer* 2018; 49(4): 493-96.
- [5] Czauderna P, Otte JB, Aronson DC, et al. Guidelines for surgical treatment of hepatoblastoma in the modern era--recommendations from the Childhood Liver Tumour Strategy Group of the International Society of Paediatric Oncology (SIOPEL). *Eur J Cancer* 2005; 41(7): 1031-36.
- [6] Czauderna P, Lopez-Terrada D, Hiyama E, et al. Hepatoblastoma state of the art: pathology, genetics, risk stratification, and chemotherapy. *Curr Opin Pediatr* 2014; 26(1): 19-28.
- [7] Clavien PA, Barkun J, de Oliveira ML, et al. The Clavien-Dindo classification of surgical complications: five-year experience. *Ann Surg* 2009; 250(2): 187-96.
- [8] Dindo D, Demartines N, Clavien PA. Classification of surgical complications: a new proposal with evaluation in a cohort of 6336 patients and results of a survey. *Ann Surg* 2004; 240(2):205-13.
- [9] Douglass EC, Green AA, Wrenn E, et al. Effective cisplatin (DDP) based chemotherapy in the treatment of hepatoblastoma. *Med Pediatr Oncol* 1985; 13(4):187-90.
- [10] Darbari A, Sabin KM, Shapiro CN, Schwarz KB. Epidemiology of primary hepatic malignancies in U.S. children. *Hepatology* 2003; 38(3): 560-66.
- [11] Agarwala S, Gupta A, Bansal D, et al. Management of Hepatoblastoma: ICMR Consensus Document. *Indian J Pediatr* 2017; 84(6): 456-64.
- [12] Ortega JA, Douglass EC, Feusner JH, et al. Randomized comparison of cisplatin/vincristine/fluorouracil and cisplatin/continuous infusion doxorubicin for treatment of pediatric hepatoblastoma: A report from the Children's Cancer Group and the Pediatric Oncology Group. *J Clin Oncol* 2000; 18(14): 2665-75.
- [13] Couinaud C. [Liver lobes and segments: notes on the anatomical architecture and surgery of the liver]. *Presse Med* 1954; 62(33): 709-12.
- [14] Black CT, Cangir A, Choroszy M, et al. Marked response to preoperative high-dose cis-platinum in children with unresectable hepatoblastoma. *J Pediatr Surg* 1991; 26(9): 1070-73.
- [15] Otte JB, Meyers R. PLUTO first report. *Pediatr Transplant* 2010; 14(7): 830-35.
- [16] Guerin F, Gauthier F, Martelli H, et al. Outcome of central hepatectomy for hepatoblastomas. *J Pediatr Surg* 2010; 45(3): 555-63.
- [17] De Ioris M, Brugieres L, Zimmermann A, et al. Hepatoblastoma with a low serum alpha-fetoprotein level at diagnosis: the SIOPEL group experience. *Eur J Cancer* 2008; 44(4): 545-50.
- [18] Busweiler LA, Wijnen MH, Wilde JC, et al. Surgical treatment of childhood hepatoblastoma in the Netherlands (1990-2013). *Pediatr Surg Int* 2017; 33(1): 23-31.

