

# Percutaneous Treatment of Carotid Artery Stenoses with Stents: A Single Center Experience

Ahmet Hakan Ateş\*, [MD]

ORCID:0000-0001-5414-7268

Aysu Başak Özbacı<sup>1</sup>, [MD]

ORCID:0000-0001-9974-5974

Selim Kum<sup>2</sup>, [MD]

ORCID:0000-0001-8329-4603

Mustafa Yenerçağ<sup>3</sup>, [MD]

ORCID:0000-0002-0933-7852

Yusuf Ziya Şener<sup>3</sup>, [MD]

ORCID:0000-0001-5151-5133

Uğur Arslan<sup>3</sup>, [MD]

ORCID:0000-0001-8572-3571

<sup>1</sup> Department of Radiology, University of Health Sciences Samsun Training and Research Hospital, Samsun, Turkey.

<sup>2</sup> Department of Cardiology, University of Health Sciences Ahi Evren Training and Research Hospital, Trabzon, Turkey.

<sup>3</sup> Department of Cardiology, University of Health Sciences Samsun Training and Research Hospital, Samsun, Turkey

\* Correspondence author: Ahmet Hakan Ateş  
Hacettepe University Faculty of Medicine-  
Cardiology Department  
Phone Number: +90 5056818961, +90 3123051781  
E-mail: ahmethakanates@yahoo.com

## ABSTRACT

**Objectives:** The effectiveness of carotid artery stenting for primary and secondary prevention of ischemic stroke has been demonstrated in many studies. In this study, we aimed to present the characteristics and post-procedural clinical outcomes of the patients admitted to our clinic with severe carotid artery disease and revascularized by carotid artery stenting with distal embolic protection system.

**Materials and Methods:** This study was a single center retrospective study. Between Jan 2015 and May 2017 patients undergoing carotid artery stenting procedure were included in the study. Symptomatic cases with more than 50% stenosis and asymptomatic patients with more than 70% carotid stenosis were included.

**Results:** Twenty-five patients were included in the study. 68% of patients were male with a mean age of  $69.3 \pm 15.7$  years. 92% of patients were symptomatic. In all patients, distal embolic protection devices and self-expandable carotid stents were used. All procedures were performed successfully. No mortality or myocardial infarction was observed in any of the patients in whom carotid artery stenting was applied successfully. Five complications were seen related to the procedure. One patient had air embolism, one patient had transient ischemic attack, one patient had stroke, one patient had symptomatic nodal rhythm and the last patient had hyper-perfusion syndrome.

**Conclusion:** Carotid artery stenting is being successfully applied with acceptable complication rates in experienced centers.

**Key words:** Stroke, carotid artery stenosis, carotid artery stenting, clinical outcomes

Received: 10 August 2019, Accepted: 11 September 2019,  
Published online: 30 September 2019

## INTRODUCTION

Acute ischemic stroke is the second most common reason of death and the most common reason of disability in the world [1]. Carotid artery stenosis is responsible for the 25-30% cases with stroke [2]. Survivors of ischemic stroke have also an increased risk of recurrent ischemic events [3]. Atherosclerosis is the most common reason of

carotid artery stenosis and risk of stroke increases with increasing severity of stenosis. Studies reveal that patients with stroke or transient ischemic attack due to carotid artery stenosis and asymptomatic patients with severe carotid artery stenosis get benefit from revascularization procedure either

surgical or percutaneous [4,5].

Carotid endarterectomy (CEA) is the preferred method to treatment of carotid artery stenosis. However due to the risk of surgical procedures such as risk of anesthesia and post-operative long periods of hospital stay; this surgical procedure has some limitations. Carotid artery stenting (CAS) has emerged as a procedure performed only in high risk surgical patients. Recently, the percutaneous technique is referred as an alternative to surgery with class I indication in guidelines [6].

In several studies, CAS and CEA were found similar with respect to restenosis and peri-operative complications. Nowadays, CAS has become a preferred treatment method also in low risk patients [7,8,9].

In our country, CAS procedure has been increasingly performed in several large centers. Here in we presented the results and complications in our patients who underwent CAS due to symptomatic and asymptomatic carotid artery stenosis

## MATERIALS and METHODS

In this study, we included ambulatory patients who admitted to our clinics due to symptomatic or asymptomatic severe carotid artery stenosis and underwent CAS procedure. Symptomatic patients were defined as patients with recent transient ischemic attack or stroke in last 6 months.

Selective conventional carotid angiography was performed to all of these patients to confirm the severity of stenosis. Degree of stenosis was evaluated according to the NASCET criteria. Symptomatic patients with >50% stenosis and asymptomatic patients with >70% stenosis underwent CAS (Figure 1). Exclusion criteria was as follows; a totally occluded carotid artery, patients who were unable to take dual antiplatelet therapy (active bleeding, recent intracranial hemorrhage), Alzheimer disease, chronic renal failure, any type of cancer with life expectancy <1 year and vasculitis. All of the patients were informed about the details of the procedure. Ethical approval was obtained.

Demographic characteristics of the patients were obtained from the hospital records. Electrocardiogram, postero-anterior chest radiography and transthoracic echocardiography were routine performed to

all of the patients. Biochemical tests and complete blood count were also obtained. All of the patients were treated with acetyl salicylic acid (ASA) 300 mg and clopidogrel 600 mg before the procedure and ASA 100 mg daily was continued with clopidogrel 75 mg o.d. thereafter. No sedatives were given to the patients.

CAS procedure was performed transfemorally with 8F sheath and right guiding catheter (Launcher, Medtronic Inc, Minneapolis ABD) or 7F destination long sheath was used for selective cannulation of the common carotid artery. Heparin was applied after sheath introduction. Distal embolic protection device (Emboshield, Abbott, Chicago) was used before stent implantation to all patients. Angiographic anterior and lateral cranial views were obtained and self-expandable stents (Xact, Abbott Vascular) were implanted thereafter (Figure 2). Balloon pre-dilatation was performed to patients, if the stents did not pass the lesion. <30% residual stenosis was accepted optimal after stent implantation. If optimal result was not present, then post-dilatation with a balloon (5-5.5 mm diameter) was performed. 1 mg iv atropin was given just before post-dilatation routinely. Before retrieval of distal embolic protection device, anterior and lateral cranial angiographic views were obtained again to investigate the distal intracranial vessels. Patients were then hospitalized in the intensive care unit for 24 hours. In case of a change of the neurological status, a neurologist was consulted.

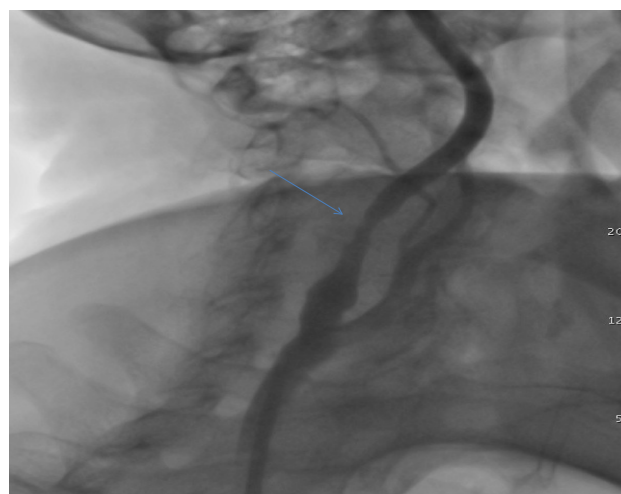


Figure 1. Lesion in the proximal portion of right internal artery which caused stroke

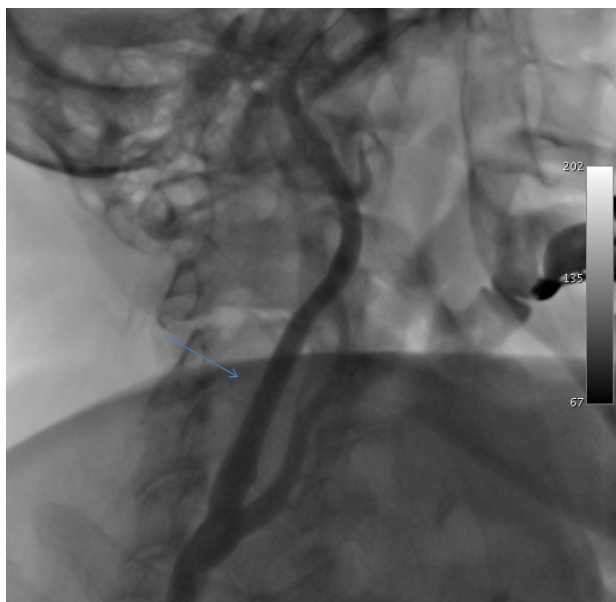


Figure 2. Carotid angiography of the same patient after stent implantation

Patients were followed under hemodynamic monitoring and systolic blood pressure of 100-140 mmHg was intended. Periprocedural cardiovascular or neurologic complications were noted. Renal functions were controlled 48 hour after the procedure in order to detect either contrast induced nephropathy developed. Stroke was defined as >24 hours of neurologic sequela and transient ischemic attack was defined as <24 hours of neurological sequela which was improved completely.

#### Statistical Analysis

Statistical Package for Social Sciences 16 (SPSS, Chicago Illinois, USA) was used for statistical analysis. Continuous variables were defined as mean $\pm$ SD

and parametric variables were defined as n (%).

## RESULTS

Twenty-five patients all of who underwent successfully carotid stent implantation using distal embolic protection device were included. Mean age was 69.3 $\pm$ 15.7 years. Basal characteristics are summarized in Table 1. Two (8%) of the patients were asymptomatic, 12 (48%) had transient ischemic attack (TIA) and 11 (44%) had a stroke history within 6 months. The angiographic findings can be found in Table 2. In three (12%) patients, pre-dilatation was performed and in 14 (56%) patients, post-dilatation was performed due to insufficient expansion of the stent. A total number of 5 (20%) complication was observed. Air embolization in one patient, embolic event in 2 patients, symptomatic nodal rhythm in one patient and hyper-perfusion syndrome in one patient was seen. The neurologic symptoms and signs of the patient with air embolism totally resolved after two hours. One of the 2 embolic events was observed as a transient ischemic attack (TIA) and resolved in 12 hours. Other was a large embolism to middle cerebral artery half an hour after the procedure. Thrombus aspiration was emergently performed with neurology unit and the signs of the patient resolved in two days. In the fourth patient with symptomatic nodal rhythm temporary pacemaker was used but the nodal rhythm did not resolve in 48 hours and a permanent DDDR pacemaker was implanted thereafter. In the last patient with hyper-perfusion syndrome, symptoms resolved at the 7th day of hospitalization and the patient was discharged without an additional neurologic deficit.

Table 1. Basal Characteristics of Patients (n=25)

Age (years)	69,3 ± 15,7
Sex (male)	17 (%68,0)
Hypertension	23 (%92,0)
Diabetes mellitus	14 (%56,0)
Hyperlipidemia	13 (%52,0)
Smoking	15 (%60,0)
Coronary artery disease	9 (%36,0)
Serum creatinine (mg/dl)	0,9 ± 0,2
LVEF (%)	56,4 ± 7,8
Asymptomatic patient	2 (%8,0)
Symptomatic Patient	
Transient ischemic attack	
Stroke	23 (%92,0)
12 (%48,0)	
11 (%44,0)	
Hemoglobin (g/dl)	13,0 ± 1,7
Total cholesterol (mg/dl)	200,4 ± 35,6
LDL cholesterol (mg/dl)	126,7 ± 26,3
HDL cholesterol (mg/dl)	41,9 ± 11,0
Continuous variables were defined as mean±SD and parametric variables were defined as n (%). LVEF: Left ventricular ejection fraction, LDL: Low density cholesterol, HDL: High density cholesterol	

Table 2. Procedural characteristics of the patients (n=25)

Stenosis degree (%)	75,2 ± 13,4
Localization of carotid stenosis (right/left)	14 (%56,0) / 11 (%44,0)
Pre-dilatation of stenosis	3 (%12,0)
Post-dilatation after stenting	14 (%56,0)
Distal protection device	25 (%100)
Mean stent length, mm	35,8 ± 4,9
Proximal stent size, mm	8,4 ± 0,7
Distal stent size, mm	6,6 ± 0,8
Complication	5 (%20,0)

## DISCUSSION

In this study, we investigated our patients who were underwent CAS procedure. Most of the patients were symptomatic (92%) i.e. recent TIA or stroke history. Ischemic stroke, one of the most common disease causing disability and mortality in older ages, is usually caused by the atherosclerotic process in the carotid arteries. Increasing the severity of the stenosis in carotid arteries, risk of ischemic stroke also increases [10].

The incidence of carotid artery stenosis is 0.5% in 6th decade and 10% in the 8th decade [11].

Treatment of this disease surgically by CEA decreased the risk of ischemic stroke by 65% and 83% respectively compared to medical therapy in NASCET and ECST studies [12,13]. CEA is still the first choice of therapy in these patients [14]. However, patients with severe carotid artery stenosis are usually old, have several comorbidities like diabetes mellitus, hypertension, chronic obstructive pulmonary disease and coronary artery disease.

Due to these comorbidities, the surgical risk is also high in patients with carotid artery stenosis.

Similarly, in our study, patients were old with a mean age of  $69,3 \pm 15,7$  years and most of them had comorbidities like coronary artery disease, hypertension and diabetes mellitus.

Percutaneous treatment for carotid artery stenosis was firstly performed with balloon angioplasty in 1980 [15]. Then, stent implantation was started but some negative results were obtained in studies comparing CAS with CEA [16,17,18]. Recently with the development of new medical therapies like clopidogrel and with the development of the stent technology, CAS has been shown to decrease mortality and recurrent ischemic attacks. The clinical results of CAS have also shown similar results like CEA in recent trials [19,20,21,22]. Wholey et al. found 98.8% success of the CAS by collecting data from several centers in 3129 procedures [23]. Shawl et al have also shown 99% success rate in 192 procedures and one major and two minor strokes (2.9%) [24]. EVA-3S trial demonstrated that carotid endarterectomy is better than carotid stenting in terms of death and mortality outcomes at first and sixth months. It is revealed that carotid endarterectomy is related with more pulmonary complications and cranial nerve injury while carotid stenting was related with more frequent local complications[25]. SPACE trial showed that although recurrent ipsilateral stroke rates were similar at 2 years between carotid stenting and endarterectomy groups; the incidence of carotid restenosis was higher in patients with carotid stenting [26]. In our study, success rate was 100% and one minor stroke was observed.

The most important complication of CAS is the cranial embolic events which may occur during or after the procedure. These may develop during the passage of the guidewire, pre-dilatation, stent implantation and most commonly during post-dilatation [27]. Distal and proximal embolic protection devices have been developed to prevent these events. Risk of embolization have decreased from 8% to 2% with

these devices [11,28,29]. Herein, we have also used distal embolic protection devices to prevent embolic events. Besides these embolic complications, some minor complications in the sheath introduction sites like hematoma and pseudoaneurysm may be observed commonly. Two interesting complications occurred during our CAS procedures. One of them was air embolism symptoms of which was resolved completely in two hours and the other was symptomatic nodal rhythm which was treated with permanent pacemaker implantation.

In this study, before post-dilatation of the stents, 1 mg atropin iv was applied routinely in all patients to prevent asystole and severe bradycardia. Similarly in some studies, routine administration of atropine was found beneficial to prevent asystole and bradycardia [30]. Therefore, we may recommend routine use of atropine before post-dilatation.

## CONCLUSION

CAS with distal embolic protection device is being performed successfully in experienced centers with acceptable complication rates as a good alternative to CEA. Herein, we have presented our patients who underwent successful CAS with two interesting complications.

## LIMITATIONS

The most important limitation of this single center retrospective study is the low number of patient enrollment. Besides this no data was present comparing CAS and CEA.

## CONFLICT OF INTEREST

The authors report no relationships that could be construed as a conflict of interest.



## REFERENCES

- [1] Polat N, Elbey MA, Akil E, et al. Karotis artere stent yerleştirme: Tek merkez deneyimi ve Klinik sonuçları. *Dicle Tıp Dergisi* 2014; 41 (4): 685-89.
- [2] Hıdıroğlu M, Çetin L, Kunt A, et al. Karotis arter hastalıklarında karotis endarterektomi erken sonuçları. *Turkish J Thorac Cardiovasc Surg* 2010; 18(3): 190-95.
- [3] Ertem A, Akdemir R, Kılıç H, et al. Karotis Artere Stent Yerleştirmenin Orta Dönem Klinik Sonuçları: Tek Merkez Çalışması. *Sakarya Med J* 2013; 3(2): 65-71.
- [4] Brott TG, Halperin JL, Abbara S, et al. ASA/ACCF/ AHA/ AANN/ AANS/ACR/ASNR/ CNS/SAIP/SCAI/SIR/SNIS/SVM/ SVS guideline on the management of patients with extracranial carotid and vertebral artery disease. A report of the American College of Cardiology Foundation/American Heart Association Task Force on Practice Guidelines, and the American Stroke Association, American Association of Neuroscience Nurses, American Association of Neurological Surgeons, American College of Radiology, American Society of Neuroradiology, Congress of Neurological Surgeons, Society of Atherosclerosis Imaging and Prevention, Society for Cardiovascular Angiography and Interventions, Society of Interventional Radiology, Society of Neuro-Interventional Surgery, Society for Vascular Medicine, and Society for Vascular Surgery. *Circulation* 2011; 24(4): 489-532.
- [5] Tendera M, Aboyans V, Bartelink ML, et al. ESC Guidelines on the diagnosis and treatment of peripheral artery diseases: Document covering atherosclerotic disease of extracranial carotid and vertebral, mesenteric, renal, upper and lower extremity arteries: the Task Force on the Diagnosis and Treatment of Peripheral Artery Diseases of the European Society of Cardiology (ESC). *Eur Heart J* 2011; 32(22): 2851-906.
- [6] Brott TG, Halperin JL, Abbara S, et al. ASA/ACCF/AHA/ AANN/AANS/ACR/ASNR/CNS/ SAIP/SCAI/SIR/SNIS/ SVM/SVS Guideline on the Management of Patients with Extracranial Carotid and Vertebral Artery Disease. *Circulation* 124: e54-e130.
- [7] Eckard DA, Zarnow DM, McPherson CM, et al. Intracranial internal carotid artery angioplasty: technique with clinical and radiographic result and follow-up. *AJR* 1999; 172: 703-07.
- [8] Theron JG, Payelle GG, Coskun O, et al. Carotid artery stenosis: treatment with protected balloon angioplasty and stent placement. *Radiology* 1996; 201(3): 627-36.
- [9] Henry M, Amor M. 9th International course book on Peripheral Vascular Intervention. 1988, Europe Bd: 607-20.
- [10] Go AS, Mozaffarian D, Roger VL, et al. Heart disease and stroke statistics 2013 update: a report from the American Heart Association. *Circulation* 2013; 127(1): e6-e245.
- [11] Phatouros CC, Higashida RT, Malek AM, et al. Carotid artery stent placement for atherosclerotic disease: rationale, technique, and current status. *Radiology* 2000; 217(1): 26-41.
- [12] Barnett HJM, Taylor DW, Haynes RB, et al. Beneficial effect of carotid endarterectomy in symptomatic patients with high-grade carotid stenosis. *N Engl J Med* 1991; 325(7): 445-53.
- [13] Farrell B, A Fraser, P Sandercock, J, et al. Randomised trial of endarterectomy for recently symptomatic carotid stenosis: final results of the MRC European Carotid Surgery Trial (ECST). *Lancet* 1998; 351(9113): 1379-87.
- [14] Kim LK, Yang DC, Swaminathan RV, et al. Comparison of Trends and Outcomes of Carotid Artery Stenting and Endarterectomy in the United States, 2001 to 2010. *Circ Cardiovasc Interv* 2014; 7(5): 692-700.
- [15] Kerber CW, Cromwell LD, Loehden OL. Catheter dilatation of proximal carotid stenosis during distal bifurcation endarterectomy. *AJNR Am J Neuroradiol* 1980; 1(4): 348-49.
- [16] Naylor AR, Bolia A, Abbott RJ, et al. Randomized study of carotid angioplasty and stenting versus carotid endarterectomy: a stopped trial. *J Vasc Surg* 1998; 28(2): 326-34.
- [17] Jordan WD Jr, Schroeder PT, Fisher WS, et al. A comparison of angioplasty with stenting versus endarterectomy for the treatment of carotid artery stenosis. *Ann Vasc Surg* 1997; 11(1): 2-8.
- [18] Ringleb PA, Albenberg J, Brückmann H, et al. 30 day results from the SPACE trial of stent-protected angioplasty versus carotid endarterectomy in symptomatic patients: a randomized non-inferiority trial. *Lancet* 2006; 368(9543): 1239-47.
- [19] Brott TG, Hobson RW, Howard G, et al. Stenting vs endarterectomy For treatment of carotid-artery stenosis. *N Engl J Med* 2010; 363: 11-23.
- [20] Gurm HS, Yadav JS, Fayad P, et al. Long-term results of carotid stenting versus endarterectomy in high-risk patients. *N Engl J Med* 2008; 358(15): 1572-79.
- [21] Gray WA, Hopkins LN, Yadav S, et al. Protected carotid stenting in high-surgical-risk patients: the ARCHER results. *J Vasc Surg* 2006; 44(2): 258-68.
- [22] Ansel GM, Hopkins LN, Jaff MR, et al. Safety and effectiveness of the INVATEC MO.MA proximal cerebral protection device during carotid artery stenting: results from the ARMOUR pivotal trial. *Catheter Cardiovasc Interv* 2010; 76(1): 1-8.
- [23] Wholey MH, Wholey M, Bergeron P, et al. Current global status of carotid artery stent placement. *Cathet Cardiovasc Diagn* 1998; 44(1): 1-6.
- [24] Shawl F, Kadro W, Domanski MJ, et al. Safety and efficacy of elective carotid artery stenting in high-risk patients. *J Am Coll Cardiol* 2000; 35(7): 1721-28.
- [25] Mas JL, Chatellier G, Beyssen B, et al. Endarterectomy versus Stenting in Patients with Symptomatic Severe Carotid Stenosis. *N Engl J Med* 2006; 355(16): 1660-71.
- [26] Eckstein HH, Ringleb P, Albenberg JR, et al. Results of the Stent-Protected Angioplasty versus Carotid Endarterectomy (SPACE) study to treat symptomatic stenoses at 2 years: a multinational, prospective, randomised trial. *Lancet Neurol* 2008; 7(10): 893-02.
- [27] Qureshi AI, Luft AR, Sharma M, et al. Prevention and treatment of thromboembolic and ischemic complications associated with endovascular procedures: Part II-Clinical aspects and recommendations. *Neurosurgery* 2000; 46(6): 1360-75; discussion 1375-6.
- [28] Theron J, Raymond J, Casasco A, et al. Percutaneous Angioplasty of Atherosclerotic and Postsurgical Stenosis of Carotid Arteries. *AJNR Am J Neuroradiol* 1987; 8(3): 495-500.
- [29] Zahn R, Mark B, Niedermaier N, et al. Embolic protection devices for carotid artery stenting: better results than stenting without protection? *Eur Heart J* 2004; 25(17): 1550-58.
- [30] Wholey MH, Jarmolowski CR, Eles G, et al. Endovascular stents for carotid artery occlusive disease. *J Endovasc Surg* 1997; 4(4): 326-38.
- [31]