

Testicular Prosthesis Implantation in Children

Neslihan Çelik¹, [MD]
 Saniye Ekinci², [MD]
 Ibrahim Karnak², [MD]
 Arbay Özden Çiftçi², [MD]
 Feridun Cahit Tanyel², [MD]
 Mehmet Emin Şenocak², [MD]

1. Konya Training and Research Hospital, Department of Pediatric Surgery, Konya, Turkey
 2. Hacettepe University Faculty of Medicine, Department of Pediatric Surgery, Ankara, Turkey
- * Corresponding Author: Saniye Ekinci, Hacettepe University Faculty of Medicine, Department of Pediatric Surgery, Ankara, Turkey
 e-mail: sekinci@hacettepe.edu.tr

Received: 30 March 2017, Accepted: 30 March 2017,
 Published online: 31 March 2017

ABSTRACT

Objective: Testicular prostheses have been used to decrease the psychosocial adverse effects of testicular absence. This clinical study was designed to analyze the patients with testicular prostheses in surgical aspects, early and late postoperative period.

Materials and Methods: The medical records of patients with testicular prostheses over a 10-year period (2000-2010) were evaluated retrospectively in terms of patient characteristics, surgical techniques, early and late postoperative complications.

Results: Eleven patients with mean age of 16.6 years (range 12-20 years) who had gonadectomy due to testicular atrophy, testicular torsion, mixed gonadal dysgenesis, testicular tumor and female pseudo-hermaphroditism underwent insertion of 18 testicular prostheses. Five of the prostheses were serum saline-filled and 6 of them were silicone gel-filled. Nine prostheses were placed by inguinal approach and 9 were placed by scrotal way. There was not any complication during surgeries. The two postoperative complications were wound infection and prosthesis dislodgement. None of the patients experienced systemic side effects secondary to silicone prostheses. Most of the patients with their implants stated contentment about appearance of scrota postoperatively.

Conclusions: Testicular prosthesis insertion increases quality of life by improving body image perception. Thus patients and their families should be informed about testicular prosthesis implantation which is a simple procedure with low morbidity.

Key words: Testicular prostheses, child, body image perception

INTRODUCTION

Testicular prostheses are inserted to improve the impaired body image perception in patients who had gonadectomy due to testicular torsion, trauma, infection, testicular atrophy, testicular tumor or female pseudo-hermaphroditism. Girdansky and Newman implanted the first testicular prosthesis in 1941 which was a mixture of cobalt, chromium and molybdenum. Thereafter acrylic, glass, metacrylate and polyurethane foam based testicular prostheses were fabricated [1, 2]. Lattimer implanted silicone gel-filled testicular prostheses in 1973 as a revolutionary innovation [3, 4]. Since then these prostheses have been used widely all over the world. However, the production of silicone gel filled testis prostheses have been terminated in United States

of America (USA) in 1995, because of the claimed risk of connective tissue disorders, autoimmune diseases and cancer secondary to silicone gel-filled breast implants. Although cancer development has been shown in only few animal researches and there is no certain evidence about connective tissue and autoimmune disease development secondary to silicone gel filled implants, serum saline-filled prostheses are preferred in USA. However, silicone gel filled testicular prostheses are still used widely in other countries [5-7]. The effects of prostheses on impaired body image perception in men have been recently investigated but there is limited information about psychosocial evaluation of male children without testes and the importance of testicular



Figure 1. The appearance of the right sided testicular implant patient before left prosthesis was inserted.

implants in psychosocial development of these patients [5, 8, 9].

This clinical study is designed to evaluate gonadectomy indications, patient and implant characteristics, surgical techniques, and complications, changes in body image perception of the adolescents and young adults who underwent testicular implantation.

MATERIALS and METHODS

The medical records of testicular prostheses inserted patients were examined retrospectively considering the primary disease, age of patients at the time of gonadectomy and prosthesis insertion, the type and size of the prosthesis, surgical technique, antibiotic prophylaxis and the complications. This study was approved by Hacettepe University Ethics Commission with application number of 410.01-3287.

RESULTS

The 18 prostheses were implanted into 11 patients' scrotum between 2000 and 2010 at Hacettepe University Medical Faculty, Department of Pediatric Surgery. The mean age of the patients was 16,6 years (range 12-20 years). The indications for gonadectomy were bilateral testicular atrophy (n=3), testicular torsion (n=3), female pseudo-hermaphroditism (n=2), unilateral testicular atrophy (n=1), mixed

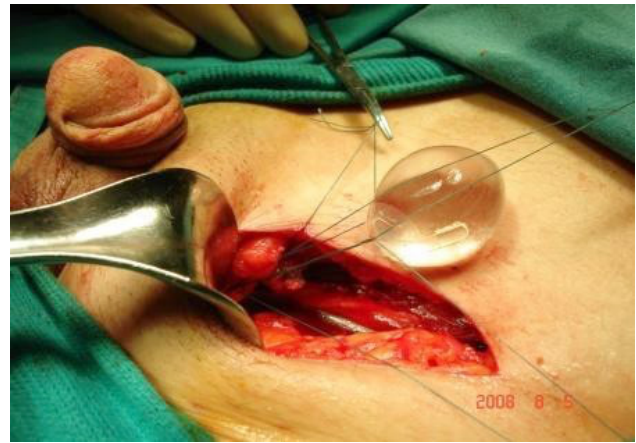


Figure 2. Inguinal incision and fixation of the prosthesis to the Dartos Fascia.

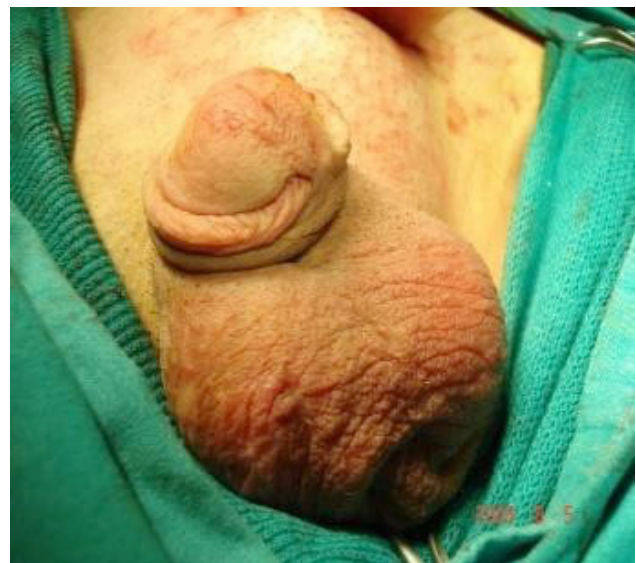

Figure 3. Postoperative picture

gonadal dysgenesis (n=1) and endodermal sinus tumor (n=1). Five of the prostheses were saline-filled and 6 of them were silicone gel-filled. There was no information about the type of 7 prostheses. Nine prostheses were placed by inguinal approach and 9 were placed by scrotal approach. In scrotal approach the prosthesis was inserted into the scrotum by a scrotal incision and fixed to the Dartos Fascia by 3-0 polyglactin suture. In inguinal approach the prosthesis was inserted into the scrotum through an inguinal incision. A scrotal pouch was created by finger dissection and the prosthesis was fixed to the Dartos Fascia by 3-0 polyglactin suture (Figure 1, 2 and 3). There was no complication during operations. None of the patients had antibiotic prophylaxis. Postoperatively 7 patients were given sulbactam-ampicillin, 3 were given trimethoprim-sulfamethoxazole and 1 was given amoxicillin-clavulonate including oral antibiotics for 1-week period. The two

Table. Results of 18 prostheses of 11 patients between 2000 and 2010.

Patient number	Age at orchiectomy (year)	Age at testicular implantation (year)	Orchiectomy indication	Implant side	Incision	Type of prosthesis	Complication
1	1	17	Bilateral testicular atrophy	Bilateral	Scrotal	Serum saline-filled silicone	-
2	2	16	Bilateral testicular atrophy	Bilateral	Inguinal	No data	Migration (right),
	2	18			Scrotal		Scrotal pain and discomfort
3	16	16 (synchronous)	Unilateral testicular atrophy	Right	Scrotal	Serum saline-filled silicone	-
4	No data	20	Female	Bilateral	Scrotal	Silicone gel-filled	-
5	12	16	Mixed gonadal dysgenesis	Right Left	Inguinal Scrotal	Serum saline-filled	-
6	No data No data	18 18	Female pseudohermaphroditism	Right Left	Inguinal Inguinal	No data	-
7	14	14 (synchronous)	Testicular torsion	Right	Inguinal	Silicone gel-filled	-
8	4	17	Testicular tumor	Left	Scrotal	Silicone gel-filled	Extrusion of prosthesis after surgical site
	17	17 (synchronous)	Bilateral testicular atrophy	Right	Inguinal	No data	-
	17	17 (synchronous)		Left	Inguinal		
10	13	14	Testicular torsion	Left	Scrotal	Silicone gel-filled	-
11	12	12 (2 months)	Testicular torsion	Left	Inguinal	Silicone gel-filled	-

postoperative complications were wound infection and prosthesis dislodgement. A 17-year-old boy who had orchiectomy because of tumor 13 years before the testicular implantation by scrotal incision experienced wound infection. He was administered antibiotics and the infected prosthesis was removed. The other patient with preoperative scrotal hypoplasia had dislodgement of prosthesis. This patient complained of scrotal pain and discomfort due to relatively large prostheses when compared to his hypoplastic scrotum. He had an operation because of the dislodged right prosthesis which was migrated to inguinal region. Eventually he had a trauma leading to loss of scrotal tissue and his left implant was removed. Re-implantation of the left prosthesis is postponed until enough scrotal volume is

obtained by the help of tissue expanders. The data including the age of patient during orchiectomy and implantation, the orchiectomy indication, the side, type and size of the prosthesis, the operation technique and the complications are presented at Table. All patients agreed that chance of providing the normal appearance of scrotum was important. Four patients stated that they found their prostheses inappropriate. The causes for dissatisfaction were firmness of prosthesis, smaller/bigger, rounder shape and inferior location of the implant with the comparison of normal testis. Seven patients, three of who thought that they had inappropriate prostheses, indicated their contentment and found implantation advisable for the similar patients.

DISCUSSION

The testicular prostheses are inserted to improve body image perception in patients with gonadectomy because of testicular torsion, trauma, infection, testicular atrophy, testicular tumor and female pseudo-hermaphroditism to provide the normal scrotal appearance. The ideal testicular implant should be similar to normal testis considering the size, shape, consistency and made of a biochemically inert material. It should be non-carcinogenic and should not cause excessive tissue reaction. The silicone is considerably an inert material which is strong and sterilized easily. Besides there is not any apparent association between silicone and cancer [5, 8]. Presently, there are silicone gel-filled, serum saline-filled, silicone encapsulated and silicone elastomer testicular implants in use. There are some suspected associations between the silicone gel-filled prostheses and connective tissue disorders or autoimmune diseases. But there is not any certain cause and effect relation between these implants and diseases [5-8, 10-16]. In this study, six prostheses were silicone gel-filled and silicone encapsulated and the other 5 were serum saline-filled and silicone encapsulated. Patients did not experience sign or symptom indicating connective tissue disorders, autoimmune diseases or any tumor. However, because of the claimed risks, children with testicular prostheses should be followed up and patients with any sign or symptom indicating systemic disease or tumor should be evaluated with specific laboratory and radiological investigations. The prosthesis insertion can be done at the time of gonadectomy or later. Some authors offer early implantation to prevent the embracement, humiliating experiences and psychosocial trauma due to absence of the testis [10]. In young children, this approach may necessitate the replacement of the previous prosthesis by a proper adult size one when the patient reaches puberty. Some authors recommend to postpone the implantation until adolescence and use tissue expanders when the scrotal volume is not enough to insert a proper size prosthesis [5, 8, 9, 18-24]. In this study, the mean age of the patients was 16.6 years (range 12-20 years). None of the patients stated embracement or humiliating experience before having implants during preoperative evaluation but all of them denoted that having normal appearance at both testes was important

for them and they denied any concern about delay of implantation until adolescence. However, this delay led the insertion of an adult size prosthesis into a hypoplastic scrotum which caused chronic pain and discomfort in one patient. Eventually he was re-operated because of migration of his right prosthesis superiorly one year after implantation. Some patients had traumatic scrotal tissue loss on the left side and his implant was removed. Re-implantation for the left side is postponed till enough scrotal volume is obtained by the help of tissue expanders. The scrotal widening by using the tissue expanders or sequential operations with prostheses in increasing size should be the preferred techniques in patients with hypoplastic scrotum in order to place appropriate size testicular implant. The migration of prosthesis can be prevented by placing a purse-string suture into the neck of scrotum. Moreover, Bukowski stated that by fixation of implant together with the purse-string suture placed superiorly to the Dartos Fascia may prevent scrotal skin damage [3]. Usually the surgeons prefer placement of testicular prostheses by scrotal incision because it is easier than inguinal approach. On the other hand, since surgical site infection and expulsion of the implants from scrotal skin are frequent complications of scrotal approach, some surgeons prefer inguinal or low inguinal/suprapubic incisions. Nine of the prostheses were inserted by scrotal incision according to the choice of consultant surgeon in our study. One of these patients who had his implantation 13 years after orchiectomy due to a testicular tumor had infection and dehiscence one month after the operation and his prosthesis was removed. The prosthesis insertion can be done at the same time with orchiectomy by inguinal incision technique without a second incision. The supra-scrotal incision technique can be used when the implantation is postponed. This approach provides insertion of the prosthesis without dissection of fibrotic tissues and decreases the risk of infection and dehiscence at the incision site [5, 8, 25-28]. In this series, there was a patient who experienced surgical site infection although he had oral antibiotics for 1 week postoperatively and application of general rules to prevent surgical site infections. Antibiotic wash outs including the incision site and prosthesis and parenteral antibiotic

prophylaxis may be recommended for prevention of infection [8]. The follow up visits one month and 6 months after the operation are recommended to check the incision and capsule development and/or migration of implant respectively. Sudden onset pain or discomfort may be signs of implant damage and ultrasonographic examination is mandatory to confirm the integrity of implant [29, 30]. None of our patients experienced implant damage. According to literature the most frequent and obvious complaints of the patients with testicular prostheses are inappropriate size, shape and placement of the implants [5, 8, 9]. Four of the patients in our study stated some complaints about their prostheses as being harder, smaller/bigger, more round in shape and too much inferior placement with the comparison of normal testes. According to patient-implant data the firmness of the prostheses did not refer to the type of the prosthesis. Since the aim of insertion of testicular prosthesis is to improve the body image perception, the selection of the implant resembling normal testicular feeling, shape, size and weight and the placement of the implant appropriately into the scrotum are very important. Unfortunately, there is not enough data about the psychosocial status of the patients before and after testicular implantation. Moreover, most studies examine the child, adolescent and adult patients together. Zilbermen and his colleagues reported a series of 19 testicular prostheses patients with mean age of 19.4 years (range 15-44 years) via questionnaires and reported

no encountered problems about their sexual experiences [9]. Definitely emotional status of children with testicular prosthesis needs to be studied more [17]. None of the patients in this study searched psychiatric support but help of child and adolescent psychiatrists may improve the psychosocial status of the patients who need testicular prosthesis implantation. The patients and their families should be informed properly about the advantages and probable early and late complications of testicular prostheses implantation.

CONCLUSIONS

The testicular implants can be inserted by simple surgical techniques. The complications and morbidity can be minimized by proper surgical techniques. Testicular prosthesis implantation improves body image perception in boys with gonadectomy for different reasons. Although long-term follow-up is mandatory because of the claimed risk of systemic diseases and possible carcinogenic effect of silicone implants, patients and their families should be informed that there is not any certain cause and effect relation between these implants and certain diseases.

CONFLICT of INTEREST

None

REFERENCES

- [1] Baumrucker GO. Testicular prosthesis for an intracapsular orchiectomy. *J Urol* 1957; 77:756.
- [2] Girdansky J, Newman HF. Use of a vitallium testicular implant. *Am J Surg* 1941; 53:514.
- [3] Lattimer JK, Vakili BF, Smith AM, et al. A natural-feeling testicular prosthesis. *J Urol* 1973; 110:81.
- [4] Puranik SR, Mencia LF, Gilbert MG. Artificial testicles in children: A new silastic gel testicular prosthesis. *J Urol* 1973; 109:735.
- [5] Bukowsky TP: Testicular Prosthesis. In: Carson III Cc. editor. *Urologic Prosthesis: The Complete Practical Guide to Devices, Their Implantation, and Patient Follow Up*. Totowa, NJ: Humana Press; 2002. p. 141-54.
- [6] Randall T. Penile, testicular, other silicone implants soon will undergo FDA review. *JAMA* 1992; 267:2578-9.
- [7] Shapiro E. Update in pediatric urology: Highlights from the annual meeting of the American Academy of Pediatrics Section on Urology. *Rev Urol* 2001; 3:10-7.
- [8] Bodiwala D, Summerton DJ, Terry TR. Testicular prostheses: Development and modern usage. *Ann R Coll Surg Engl* 2007; 89:349-53.
- [9] Zilberman D, Winkler H, Kleinmann N, et al. Testicular prostheses insertion of following testicular loss or atrophy during early childhood – technical aspects and evaluation of patient satisfaction. *J Pediatr Urol* 2007; 3:461-5.
- [10] Barrett DM, O'Sullivan DC, Malizia AA, et al. Particle shedding and migration from silicone genitourinary prosthetic devices. *J Urol* 1991; 146:319-22.
- [11] Henderson J, Culkin D, Mata J, et al. Analysis of immunological alterations associated with testicular prostheses. *J Urol* 1995; 154:1748-51.
- [12] Oppenheimer BS, Oppenheimer ET, Danishefsky I, et al. Further studies of polymers as carcinogenic agents in animals. *Cancer Res* 1955; 15:333-40.
- [13] Pidutti R, Morelas A. Silicone gel-filled testicular prosthesis and systemic disease. *Urology* 1993; 42:155-7.
- [14] Abbondanzo SL, Young VL, Wei MQ, et al. Silicone gel-filled breast and testicular implant capsules: A histologic and immunophenotypic study. *Mod Pathol* 1999; 12:706-13.
- [15] Doherty AP, Mannion EM, Moss J, Ockrim JL, Christmas TJ. Spread of silicone to inguinal lymph nodes from a leaking testicular

- prosthesis: a cause for chronic fatigue? *BJU Int* 2000; 86:1090.
- [16] Turek PJ, Master VA. Safety and effectiveness of a new saline filled testicular prosthesis. *J Urol* 2004; 172:1427-30.
- [17] Elder JS, Keating MA, Duckett JW. Infant testicular prosthesis. *J Urol* 1989; 141:1413-5.
- [18] Antao B, Mackinnon E. Simple placement of prosthetic testes in children. *Pediatr Surgery Int* 2006; 22:422-4.
- [19] Beer M, Kay R. Testicular prostheses. *Urol Clin North Am* 1989; 16:133-8.
- [20] Kogan SJ, Hadziselimovic F, Howards SS, et al. Editors. *Adult and Pediatric Urology*. Philadelphia: Lippincott Williams & Wilkins; 2002. p. 2613-4.
- [21] Lattimer JK, Stalneckner MC. Tissue expansion of underdeveloped scrotum to accommodate large testicular prosthesis. A technique. *Urology* 1989; 33:6-9.
- [22] Lawrentschuk N, Webb DR. Inserting testicular prostheses: A new surgical technique for difficult cases. *BJU Int* 2005; 95:1111-4.
- [23] Libman JL, Pippi-Salle JL, Chan TK. The use of a suprascrotal or "wink" incision for placing a testicular prosthesis. *BJU Int* 2006; 98:1051-3.
- [24] Simms MS, Huq S, Mellon JK. Testicular prostheses: a new technique for insertion. *BJU Int* 2004; 93:179.
- [25] Marshall S. Potential problems with testicular prostheses. *Urology* 1986; 28:388-90.
- [26] Kogan S. The clinical utility of testicular prosthesis placement in children with genital and testicular disorders. *Transl Androl Urol* 2014; 3(4):391-7.
- [27] Mohammed A, Yassin M, Hendry D, et al. Contemporary practice of testicular prosthesis insertion. *Arab J Urol* 2015; 13(4):282-6.
- [28] Bush NC, Bagrodia A. Initial results for combined orchiectomy and prosthesis exchange for unsalvageable testicular torsion in adolescents: description of intravaginal prosthesis placement at orchiectomy. *J Urol* 2012; 188:1424-8.
- [29] Floyd MJ, Williams H, Agarwal SK, et al. Unilateral spontaneous rupture of a testicular implant thirteen years after bilateral insertion: A case report. *J Med Case Reports* 2010; 4:341.
- [30] Semelka R, Anderson M, Hricak H. Prosthetic testicle: appearance at MR imaging. *Radiology* 1989; 173:561-2.

