

Incidental Detection of a Rare Coronary Anomaly During Catheter Ablation for Premature Ventricular Complexes: All in One Coronary Ostium

Yusuf Ziya Şener¹, [MD]
ORCID: 0000-0001-5151-5133

Uğur Canpolat¹, [MD]
ORCID: 0000-0002-4250-1706

Hikmet Yorgun¹, [MD]
ORCID: 0000-0001-7673-229X

Tuncay Hazırolan², [MD]
ORCID: 0000-0003-0620-2140

Kudret Aytemir¹, [MD]
ORCID: 0000-0001-9279-8424

¹Hacettepe University Faculty of Medicine, Cardiology Department

²Hacettepe University Faculty of Medicine, Radiology Department

Corresponding Author: Yusuf Ziya Şener
Hacettepe University Faculty of Medicine, Cardiology Department, Sıhhiye, Ankara / Turkey.
E-mail: yzsener@yahoo.com.tr

<https://doi.org/10.32552/2021.ActaMedica.550>

Received: 28 December 2020, Accepted: 8 April 2021,
Published online: 20 September 2021

ABSTRACT

Single coronary artery is a rare congenital anomaly associated with sudden cardiac death even though most of the cases are asymptomatic. Cardiac computerized tomography angiography plays an essential role in establishing the diagnosis of single coronary artery and designating the arterial course. Being aware of coronary anomaly is crucial in some cases scheduled for catheter ablation of premature ventricular complex neighboring to coronary arteries to prevent radiofrequency ablation related vascular injury.

Keywords: Coronary anomaly, single coronary artery, premature ventricular complex

INTRODUCTION

Single coronary artery (SCA) is defined as the origination of both right and left coronary arteries from a single coronary ostium. SCA is a rare congenital anomaly, and it is usually associated with other cardiac malformations, including tetralogy of Fallot, truncus arteriosus, and pulmonary artery atresia. Although most of the SCA patients are asymptomatic, symptomatic cases may present with a broad spectrum of symptoms such as chest pain, palpitation, syncope, and sudden cardiac death [1]. Association between the single coronary artery and premature ventricular complexes (PVCs)

is still debated, and it is reported in a patient with SCA who underwent catheter ablation for PVCs [2].

Herein, we reported a male patient who underwent catheter ablation for drug-resistant symptomatic PVCs and diagnosed SCA during the ablation procedure.

CASE

A 36-year-old male was admitted to our hospital with the complaint of intermittent palpitations

and exertional dyspnea despite using propafenone 300 mg/day. Past medical and family history was unremarkable. The ECG showed sinus rhythm with bigeminy monomorphic PVCs. Transthoracic echocardiography showed normal left and right ventricular functions without any structural abnormality. 24-hour Holter monitorization revealed ~10,000 monomorphic PVCs/day. The treadmill exercise test was negative for ischemic ECG changes and no increment in PVCs during the test. Thus, he underwent catheter ablation for PVCs and coronary angiography. In the 3D electroanatomic mapping system (CARTO-3 system, Biosense Webster, Diamond Bar, CA, USA), early ventricular activation during PVCs was found at the anteroseptal of the right ventricular outflow tract and terminated by ablation of this region.

During coronary angiography after ablation, left coronary ostium couldn't be found (Figure 1A), and aortography showed a single coronary ostium originating from right sinus Valsalva. Contrast media was given from the right coronary ostium by 6F right Judkins catheter, and all coronary arteries were separately visualized (Figure 1B&C).

Coronary anatomy has been delineated in detail by cardiac CTA, which demonstrated a separate three coronary vessels arising from just 4mm distal to the single ostium, a right coronary artery with a normal course, the left circumflex artery with the retro aortic course, and left anterior descending artery with prepulmonic course (Figure 2A&B). The clinical follow-up was recommended, and he has been discharged uneventfully.

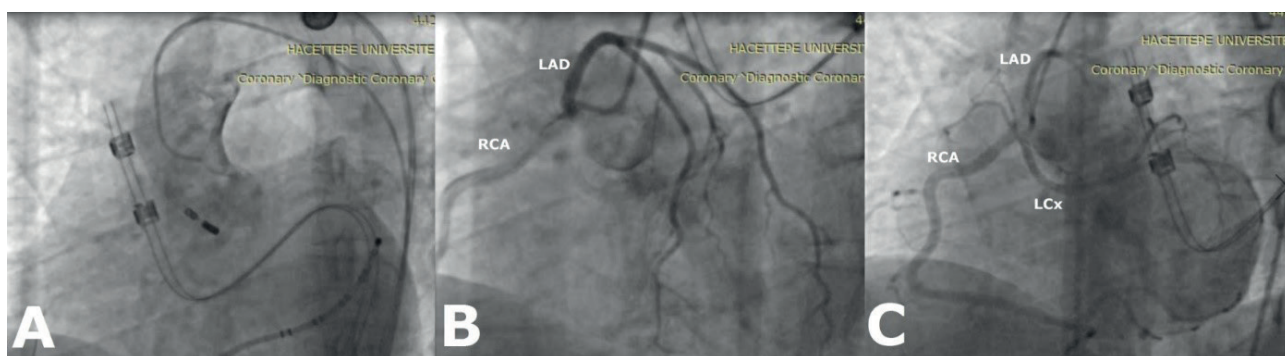


Figure 1. (A) Contrast injection into the aorta revealed no left coronary ostium. (B & C) Contrast media injection from right coronary ostium by 6F right Judkins catheter and all coronary arteries were separately visualized.

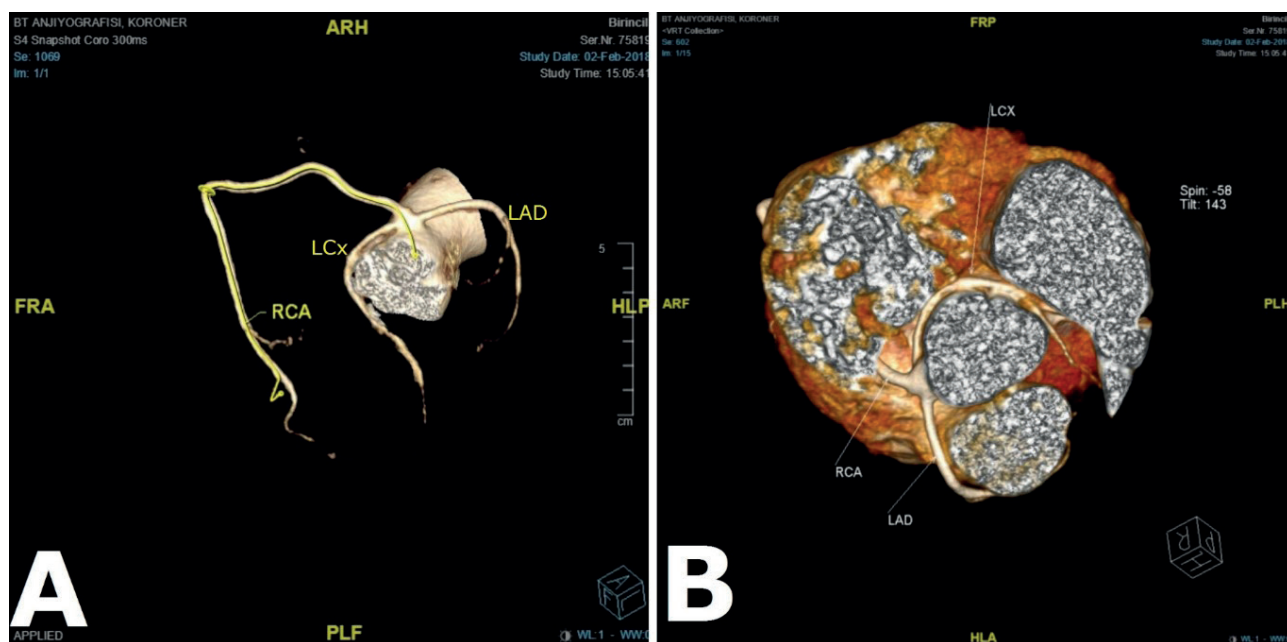


Figure 2. (A) Cardiac computerized tomography demonstrated a three separate coronary artery arising just 4 mm distal to the right coronary ostium. (B) Retroaortic course of the left circumflex artery and prepulmonic course of the left anterior descending artery was shown.

DISCUSSION

Coronary artery anomaly is a rare entity, and its prevalence is reported between 0.21% to 5.79%. SCA accounts for less than 3% of the coronary artery anomalies, and its prevalence ranges between 0.024–0.066% in patients with structurally normal hearts [3]. SCA is classified into three main types according to the Lipton classification. Type 1 SCA refers to the single coronary artery streaming like the right coronary artery and then continuing into the left circumflex and left anterior descending artery. Type 2 is the most common, and SCA is divided into right and left main coronary arteries, and left circumflex artery originates from the left main artery afterward. In Type 3 SCA, the main coronary artery trunk branches into left anterior descending, circumflex, and right coronary arteries separately [4]. The presence of proximal intramyocardial course, acute take-off angle of an anomalous coronary artery, slit-like orifice, and aberrant route of a coronary artery causing compression between great vessels during exercise are well-defined factors related to myocardial ischemia, sudden cardiac death, and worse prognosis [5].

Diagnosis of coronary artery anomalies was challenging before the cardiac CT era. Fluoroscopy-guided angiography may help confirm the diagnosis of coronary anomalies, but it does not give sufficient information about the coronary arteries' anatomical course. Cardiac CT angiography ensures detailed data about coronary artery course, such as anatomic relationships with other vascular

structures, which are essential for management and predicting prognosis [6].

Coronary artery injury may develop during catheter ablation, and anatomical proximity is a significant risk factor for vascular injury. The anteroseptal site of the right ventricular outflow tract (RVOT) is adjacent to the left coronary cusp, while the posteroseptal site of RVOT is adjacent to the right coronary cusp. Therefore patients with ventricular arrhythmias originating from the areas mentioned above have higher vascular injury risk. Epicardial ablation also carries a higher vascular injury risk than endocardial procedures [7].

CONCLUSION

According to the Lipton classification; our case was defined as an R-III type single coronary artery, and vascular damage did not occur during the ablation procedure. Single coronary artery anomaly is rare, and it may lead to arrhythmias and sudden cardiac death. Cardiac CT angiography is useful for diagnosing the SCA and determining the course of the coronary artery. Detecting coronary anomalies is vital to avoid coronary artery injury during catheter ablation procedures.

CONFLICT of INTEREST

H.Y. and K.A.: Proctoring and lecturer for Medtronic, Abbott, and Biosense Websters. The other authors have nothing to disclose.

REFERENCES

- [1] Elbadawi A, Baig B, Elgendy IY, et al. Single Coronary Artery Anomaly: A Case Report and Review of Literature. *Cardiol Ther.* 2018; 7(1): 119-123.
- [2] Fu F, Jin H, Feng Y. A rare case of single right coronary artery with congenital absence of left coronary artery in an adult: a case report. *J Cardiothorac Surg.* 2015; 10: 57.
- [3] Panduranga P, Riyami AA. Single coronary artery from right aortic sinus in a very elderly patient. *J Saudi Heart Assoc.* 2016 Oct;28(4):257-60. doi: 10.1016/j.jsha.2016.03.004.
- [4] Lipton MJ, Barry WH, Obrez I, et al. Isolated single coronary artery: diagnosis, angiographic classification and clinical significance. *Radiology* 1979; 130: 39–47.
- [5] Angelini P, Walmsley RP, Libreros A, et al. Symptomatic anomalous origination of the left coronary artery from the opposite sinus of Valsalva. Clinical presentations, diagnosis, and surgical repair. *Tex Heart Inst J* 2006; 33: 171–9.
- [6] Gleeson T, Thiessen R, Wood D, et al. Single coronary artery from the right aortic sinus of Valsalva with anomalous prepulmonic course of the left coronary artery. *Can J Cardiol.* 2009; 25(4): e136-e138.
- [7] Roberts-Thomson KC, Steven D, Seiler J, et al. Coronary artery injury due to catheter ablation in adults: presentations and outcomes. *Circulation.* 2009; 120(15): 1465-73.