

## Ophthalmic Manifestations of ANCA-Associated Vasculitis

Merve İnanç Tekin<sup>1</sup>, [MD]

ORCID: 0000-0002-9930-7680

Müge Pınar Çakar Özdağ<sup>2</sup>, [MD]

ORCID: 0000-0002-5714-7172

### ABSTRACT

Ocular manifestations in antineutrophil cytoplasmic antibody-associated vasculitis can be associated with the general or limited form of disease and can even occur in the absence of systemic disease. Ocular manifestations of associated vasculitis can be the first symptom of previously not manifested or undiagnosed systemic disease, allowing ophthalmologists to contribute to the diagnosis. Although its ocular findings are variable and nonspecific, the presence of necrotizing changes and peripheral corneal involvement accompanying scleral inflammation are important clues suggesting systemic vasculitis, especially associated vasculitis. The disease may affect all layers of the eye; scleritis and orbital involvement being the most common. Conjunctivitis, episcleritis, peripheral ulcerative keratitis, uveitis and retinal vasculitis are other ocular findings that may be observed during the disease course.

Ocular involvement is most commonly seen in granulomatosis with polyangiitis followed by eosinophilic granulomatosis with polyangiitis and microscopic polyangiitis. Due to the high morbidity and mortality of associated vasculitis, it is very important to recognize the ocular manifestations of vasculitis as a sign of the underlying systemic disease and an indicator for the disease activity. Treatment varies depending on the location and severity of the ocular involvement. Although localized medical and surgical treatments can help to manage associated ocular disease, systemic immunosuppressive medications are often required to control the underlying disease. With the increasing availability and use of biological agents, prognosis has improved in patients with severe ocular complications. Rituximab appears to be useful in inducing remission and controlling relapses in patients with ocular involvement of associated vasculitis, particularly in cyclophosphamide resistant cases. A multidisciplinary approach in the diagnosis, treatment and follow-up of patients with associated vasculitis is required in order to achieve successful results.

**Keywords:** Antineutrophil cytoplasmic antibody-associated vasculitis, conjunctivitis, episcleritis, uveitis, peripheral ulcerative keratitis, retinal vasculitis, scleritis.

<sup>1</sup>Ulucanlar Eye Training and Research Hospital, Ophthalmology Department, Ankara, Turkey.

<sup>2</sup>Health Sciences University Ulucanlar Eye Training and Research Hospital, Ophthalmology Department, Ankara, Turkey.

Corresponding Author: Merve İnanç Tekin  
Ulucanlar Eye Training and Research Hospital,  
Ophthalmology Department, Ankara, Turkey.  
E-mail: mrvn88@hotmail.com

<https://doi.org/10.32552/2021.ActaMedica.551>

Received: 28 December 2020, Accepted: 18 April 2021,  
Published online: 20 November 2021

## INTRODUCTION

Antineutrophil cytoplasmic antibody (ANCA)-associated vasculitis (AAV) are a group of autoimmune, potentially life-threatening diseases, characterized by necrotizing vasculitis that affects small to medium-sized vessels in multiple organs [1,2]. AAV comprises three distinct disease phenotypes as granulomatosis with polyangiitis (GPA, formerly Wegener's granulomatosis), microscopic polyangiitis (MPA), and eosinophilic granulomatosis with polyangiitis (EGPA, formerly Churg-Strauss syndrome). AAVs are systemic diseases with variable clinical expression. The classical triad of GPA consists of necrotizing granulomatous vasculitis of the upper and lower respiratory tracts, focal segmental glomerulonephritis, and necrotizing vasculitis of small arteries and veins [3]. MPA is a systemic necrotizing non-granulomatous vasculitis that primarily affects the small vessels of the kidneys and lungs. EGPA is characterized by the constellation of asthma, hypereosinophilia, and eosinophilic extravascular granulomas [4].

Previous literature on ocular findings of AAV reported a frequency of ocular involvement which is between 16% and 20% [5-7]. There are conflicting results regarding gender preponderance. While a male predominance of 56.5% to 62.5% has been reported in some studies [5,8], a female predominance of 51% to 72.2% has been reported in others [6,7].

Ocular manifestations in AAV can be associated with the limited or general form of AAV and can even occur in the absence of systemic disease in people of all ages, including children. The limited form of disease can be ANCA negative and in such cases, ophthalmologist may contribute to the diagnosis of the disease. Ocular involvement is most commonly seen in GPA followed by EGPA and MPA [9,10]. Although orbital disease and scleritis have been reported as the most common presentation forms, all aspects of the eye and orbit can be involved and, AAV can also manifest as conjunctivitis, peripheral ulcerative keratitis, uveitis, and retinal vasculitis. [8,11,12].

Watkins et al [8] reported that patients with ocular manifestations of AAV experienced 2.75-fold higher mortality than patients with other inflammatory eye diseases. Therefore, the ability to recognize ocular manifestations of vasculitis and associating

them with the underlying systemic disease is very important in order to prevent morbidity and mortality. This review describes the ocular and orbital manifestations of AAV. However, it should be kept in mind that most of the findings described herein are not pathognomonic for AAV and can also be seen in other vasculitic, inflammatory or infectious processes.

### Conjunctival Manifestations

Conjunctivitis is common and may be ulcerative, necrotic, and/or cicatricial [13]. In a review of 1,286 patients with systemic necrotizing vasculitis, ocular involvement was present in 214 (16.6%) patients, and conjunctivitis was the most widely documented manifestation of ocular presentation [5]. Conjunctival disease is usually bilateral and symptoms often include ocular redness, foreign body sensation, blurred vision, and possibly bloody tears. In the early phase of the disease, conjunctival hyperemia is the most common finding at presentation; conjunctival granulomas may also be seen in few cases. With the progression of the disease cicatrizing conjunctivitis may result in symblepharon, entropion with an inturning eyelid and trichiasis with eyelashes directed against the globe [14,15]. Ocular exposure, which can also be exacerbated by the tear deficiency caused by loss of the mucin-producing conjunctival goblet cells and destruction of lacrimal glands, may also occur. Conjunctival biopsy showing evidence of necrosis and occlusive vasculitis may be helpful in diagnosis [16]. The differential diagnosis includes allergic and infectious conjunctivitis. More severe cicatrizing conjunctivitis can also be observed in diseases such as ocular cicatricial pemphigoid and trachoma. Generally, aqueous tear replacement is used in the treatment. Surgical interventions, including removal of scar tissue, separation of adhesions, and ocular surface reconstruction with mucosa or amniotic membrane grafts, are required in cases with scarring [17].

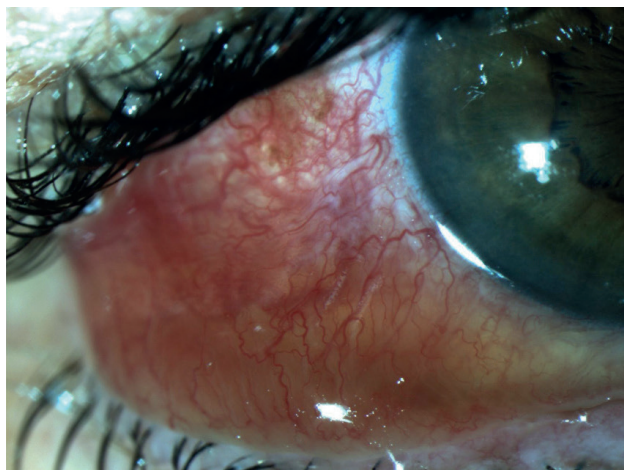
### Episcleral and Scleral Manifestations

The sclera, due to its high collagen content, is particularly susceptible to being affected by granulomatosis, and scleritis as well as episcleritis can be seen in each of these diseases. In a cohort of 1171 AAV cases, scleritis was found in 22%

and episcleritis in 21% of patients with ocular involvement [7]. The main clinical manifestation of episcleritis is ocular redness. It can be unilateral or bilateral, diffuse, sectoral or nodular, and the lesions are mobile. There are dilated blood vessels extending radially from the corneoscleral limbus, and the redness blanches with topical application of 2.5% phenylephrine drops. These clinical findings help us to differentiate it from the scleritis. Systemic associations such as AAV have been reported in about one third of cases [18]. Bilateral involvement and recurrent symptoms are more frequently observed in these cases.

In contrast to episcleritis, scleritis, particularly when necrotizing, can cause significant ocular morbidity with severe vision loss if not adequately treated [19]. The suggestive features of scleritis consist specific crisscross or network vasodilation pattern of the deep vessels of the sclera on slit-lamp examination, while in episcleritis congested vessels follow the usual radial pattern [20,21] (Figure 1). It often presents with deeper, intense pain and photophobia. The redness is not mobile and does not blanch with phenylephrine drops as mentioned before. In patients with scleritis, GPA is the second most common systemic disease following rheumatoid arthritis [22,23].

Scleral inflammation that affects the adjacent cornea is highly suggestive of an underlying systemic vasculitis, of which GPA is the most common [19,24]. (Figure 2) In addition, in patients with GPA having scleritis, complications including intraocular uveitis, glaucoma, optic nerve edema, and retinal or choroidal distortion may also occur [25]. Furthermore, it should be kept in mind that

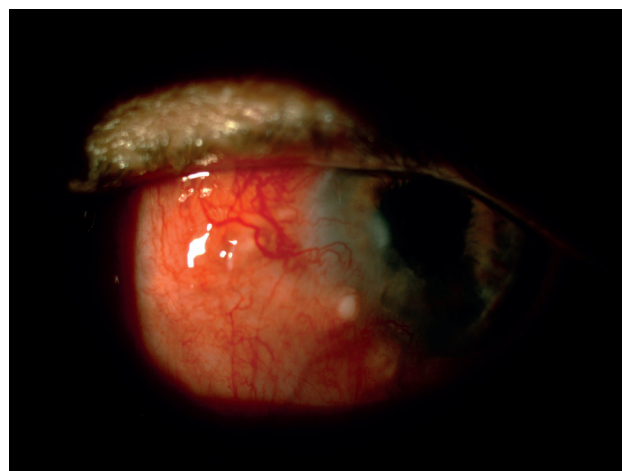


**Figure 1.** The patient presenting with recurrent diffuse scleritis attacks first, was diagnosed with GPA.

ocular manifestations, particularly necrotizing scleritis, can be an indicator for both morbidity and mortality unless appropriate systemic treatment is initiated [26]. Mortality has been reported to be as high as 54% in patients with necrotizing scleritis who are not undergoing immunosuppressive therapy [27].

### Corneal Manifestations

Peripheral ulcerative keratitis (PUK), which is the most important corneal complication of AAV, is the result of an immune-mediated obstructive necrotizing vasculitis of the anterior ciliary arteries as shown in histopathological examinations. The lesions usually are found within 2 mm of corneoscleral limbus, and the adjacent limbal tissue. Due to the shared blood supply, PUK is often accompanied by scleritis, particularly with necrotizing type, and both characterize systemic vasculitis [28,29]. As keratolysis progresses, the affected corneal stroma may become thinner enough to cause corneal perforation, either spontaneously or with minor ocular trauma [30]. In one series, imminent or overt corneal perforation was reported to occur in one third of patients with PUK [31]. In another series of patients with scleritis associated PUK, 100% were in danger of perforation [32]. The presenting complaints are pain, injection, photophobia and decreased vision due to corneal opacities or induced astigmatism. The definitive treatment of PUK is systemic immunosuppression, but local treatments should be added as an adjunctive treatment. As corneal epithelial destruction is common, topical antibiotic coverage, aggressive tear replacement and matrix



**Figure 2.** Scleritis affecting the peripheral adjacent cornea is highly suggestive for systemic vasculitis including GPA.

metalloproteinase inhibitors can be applied [30]. Tissue adhesives may be used to manage small corneal perforations. Larger corneal defects however, require the use of corneal patch grafts or therapeutic corneal transplants [33].

### Uveal Manifestations

Although the isolated form of uveitis is not common, intraocular inflammation has been reported in patients with AAV. Uveitis associated with AAV is nonspecific and can be anterior, intermediate, or posterior, with or without vitritis [34,35]. Uveitis, particularly anterior uveitis, typically occurs secondary to keratitis or scleritis rather than to be a primary involvement. Watkins et al. determined uveitis in 17.9% of patients with AAV in their study and half of these cases had coexisting scleritis, suggesting that uveitis was often a secondary phenomenon [8]. However, a case with granulomatous panuveitis as the first sign of GPA has also been reported [36]. In a recent study, Gheita et al. reported that RF positivity may raise suspicion for uveitis and there is a remarkable relationship between uveitis and disease activity in GPA patients [37].

### Retinovascular Manifestations

The retina was the least involved part compared to other eye components. Retinal manifestations in AAV include chorioretinitis, macular edema, retinitis with cotton wool spots, acute retinal necrosis, retinal vasculitis, central retinal artery/vein occlusion and exudative retinal detachment [38]. In a study of 1286 patients with systemic necrotizing vasculitis, only 5 patients with retinal vasculitis were identified [5]. In another series of 140 patients with GPA evaluated at the Mayo Clinic over a 16-year period, 40 patients had ocular involvement, of which 4 (2.9%) had retinal vasculitis [39]. It has been reported that the most common cause of AAV associated retinal vasculitis is GPA rather than MPA and EGPA [40]. The most common presenting ocular symptoms were blurry vision and floaters. AAV affects small-to-medium size retinal vessel; either artery/arteriole, vein/venule, capillary alone or combined and manifests as vessel wall staining and/or leakage on the fundus fluorescein angiography (FFA). Vascular changes include damage to the vessel wall by fibrinoid necrosis, granulomatous inflammation or cicatricial

arterial changes. The involved artery/arteriole may be attenuated with uneven thickness. AAV etiology should be considered when a combination of retinal and choroidal vasculitis with both artery and vein involvement is encountered in the clinic [40].

Several case reports of branch or central retinal vein occlusion (RVO) have also been reported in patients with GPA and EGPA. Possible mechanisms involved in the etiopathogenesis of RVO associated with AAV are focal necrotizing vasculitis of the retinal vessels, subclinical inflammation of the lamina or retrolamina parts of the optic nerve, and compression of the central retinal vein by extracapillary granulomatous lesions [34,41,42]. The diagnosis is usually confirmed by FFA, which shows delayed or incomplete filling in the distribution of the involved blood vessel or irregular leakage in areas of ischemia. Treatment includes intraocular injections of anti-vascular endothelial growth factor (VEGF) agents and panretinal laser photocoagulation, thereby reducing the release of VEGF from ischemic tissues [40].

### Orbital Manifestations

Orbital involvement is one of the most common presentations of GPA, reported in 15-60% of cases [43,44] and can be bilateral in 14-58% of cases [45,46]. Granulomatous inflammation of the orbital soft tissues may develop primarily or be associated with inflammation of the paranasal spaces [47]. Infiltrations of soft tissues in the orbit are manifested as swelling of the eyelids, epiphora, proptosis, restricted eye movements, diplopia, and visual distortion. The epiphora can be the result of canalicular and, nasolacrimal duct involvement, or exposure due to marked proptosis. Diplopia can be caused by many reasons such as direct mass effect on the globe, infiltration of extraocular muscles, vasculitis involving extraocular muscles, and cranial nerve involvement. While cranial nerve palsy was reported in one fifth of patients, external ophthalmoplegia is a less common finding of GPA [48]. Orbital pseudotumor which has been reported at a rate of 6-15%, may have high risk of blindness despite aggressive treatment [49]. Retrobulbar granulomatous masses can compress the optic nerve and vessels, causing irreversible visual impairment and atrophy of the optic nerve. Large masses can also cause to the destruction of the orbital bone structures [44,50]. Ismailova et al.



divided the patients with GPA into three groups according to the variant of orbital involvement: those with orbital mass without primary lacrimal gland involvement, those with lacrimal gland involvement, and those with extraocular myositis. They suggested that patients with orbital masses without lacrimal gland involvement are characterized by a higher rate of systemic disease, and that more aggressive immunosuppression is required even in the presence of localized disease [51]. Imaging modalities such as ultrasound, CT or MRI are all helpful in characterizing the size, extent, treatment response of the lesion, excluding other diseases in differential diagnosis, assessing the risk of optic nerve entrapment, and planning surgery if indicated. Also, when there is a doubt about the diagnosis of AAV, the orbit can serve as a tissue of source for histopathological diagnosis (Figure 3).

### Treatment

Selection of systemic therapy depends on the extent of disease, the rate of progression, the response to therapy, and the side effects. Induction therapy with corticosteroids and cyclophosphamide (CYC) has traditionally been used, improving the survival rate from 10% to 80% [52,53]. It has been shown that rituximab (RTX) therapy which is a monoclonal antibody against CD-20 antigen is not inferior to CYC for the induction of remission in severe AAV and may be superior in recurrent disease (RAVE study) [54,55]. Several case reports and case series also illustrate the potential efficacy of RTX in the treatment of patients with GPA with ocular involvement refractory to CYC, including PUK, scleritis and idiopathic orbital inflammation [56-

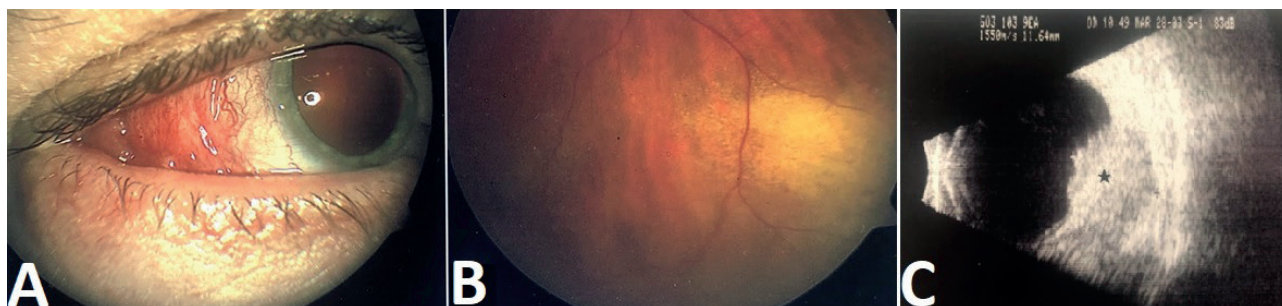
58]. A recent study by Ahmed et al. confirmed that both CYC and RTX were effective in inducing the remission of GPA-associated scleritis and uveitis. Moreover, RTX appeared to be superior in terms of safety and efficacy, with less need for treatment interruptions and dose adjustments [59]. Along with the systemic treatment, local therapeutic agents such as antibiotic, lubricant and/or steroid containing eye drops, and surgical approaches including dacryocystorhinostomy, ocular surface reconstruction by mucosal or amniotic membrane graft, keratoplasty are also used.

### CONCLUSION

AAV are severe and often organ and life-threatening diseases. Ocular disease occasionally occurs in the absence of other organ or systemic involvement and represents a limited form of disease which may also be ANCA negative. Clinicians should be aware of ocular involvement, since it reflects disease activity and often requires systemic immunosuppressive drugs to control the symptoms. Caring for patients with AAV having ocular manifestations requires close collaboration between ophthalmologists and other specialists to achieve the best outcomes.

### CONFLICT OF INTEREST

The authors report no conflicts of interest and have no proprietary interest in any of the materials mentioned in this article. The authors alone are responsible for the content and writing of the paper.



**Figure 3.** The patient who presented with mild proptosis, conjunctival redness and chemosis in his right eye (a) revealed a raised and yellowish lesion on the periphery of the retina on fundus examination (b), ocular USG showed a retrobulbar mass lesion pushing the eye wall inward (c). The diagnosis of AAV was made by tissue biopsy.

## REFERENCES

- [1] Pagnoux C. Updates in ANCA-associated vasculitis. *Eur J Rheumatol* 2016; 3(3): 122-133.
- [2] Jennette JC, Falk RJ, Bacon PA, et al. 2012 revised International Chapel Hill Consensus Conference Nomenclature of Vasculitides. *Arthritis Rheum* 2013; 65(1): 1-11.
- [3] Leavitt RY, Fauci AS, Bloch DA, et al. The American College of Rheumatology 1990 criteria for the classification of Wegener's granulomatosis. *Arthritis Rheum* 1990; 33(8): 1101-1107.
- [4] Masi AT, Hunder GG, Lie JT, et al. The American College of Rheumatology 1990 criteria for the classification of Churg-Strauss syndrome (allergic granulomatosis and angiitis). *Arthritis Rheum* 1990; 33(8): 1094-1100.
- [5] Rothschild PR, Pagnoux C, Seror R, et al. Ophthalmologic manifestations of systemic necrotizing vasculitides at diagnosis: a retrospective study of 1286 patients and review of the literature. *Semin Arthritis Rheum*. 2013; 42(5): 507-514.
- [6] Miyanaga M, Takase H, Ohno-Matsui K. Anti-Neutrophil Cytoplasmic Antibody-Associated Ocular Manifestations in Japan: A Review of 18 Patients. *Ocul Immunol Inflamm*. 2020;1-6.
- [7] Ungprasert P, Crowson CS, Cartin-Ceba R, et al. Clinical characteristics of inflammatory ocular disease in anti-neutrophil cytoplasmic antibody associated vasculitis: a retrospective cohort study. *Rheumatology (Oxford)* 2017; 56(10): 1763-1770.
- [8] Watkins AS, Kempen JH, Dongseok C, et al. Ocular disease in patients with ANCA-positive vasculitis. *J Ocul Biol Dis Infor*. 2009; 3(1): 12-19.
- [9] Pulido JS, Goeken JA, Nerad JA, et al. Ocular manifestations of patients with circulating antineutrophil cytoplasmic antibodies. *Arch Ophthalmol* 1990; 108: 845-850.
- [10] Caster JC, Shetlar DJ, Pappolla MA, et al. Microscopic polyangiitis with ocular involvement. *Arch Ophthalmol* 1996; 114: 346-348.
- [11] Tarabishy AB, Schulte M, Papaliodis GN, et al. Wegener's granulomatosis: clinical manifestations, differential diagnosis, and management of ocular and systemic disease. *Surv Ophthalmol* 2010; 55 (5): 429-444.
- [12] Perez VL, Chavala SH, Ahmed M, et al. Ocular manifestations and concepts of systemic vasculitides. *Surv Ophthalmol* 2004; 49(4): 399-418.
- [13] Robinson MR, Lee SS, Sneller MC, et al. Tarsal-conjunctival disease associated with Wegener's granulomatosis. *Ophthalmology*. 2003; 110: 1770-1780.
- [14] Fortney AC, Chodosh J. Conjunctival ulceration in recurrent Wegener granulomatosis. *Cornea*. 2002; 21(6): 623-624.
- [15] Meier F, Messmer E, Bernauer W. Wegener's granulomatosis as a cause of cicatrizing conjunctivitis. *Br J Ophthalmol*. 2001; 85(5): 625.
- [16] Jordan DR, Zafar A, Brownstein S, et al. Cicatricial conjunctival inflammation with trichiasis as the presenting feature of Wegener granulomatosis. *Ophthal Plast Reconstr Surg*. 2006; 22: 69-71.
- [17] Gu J, Zhou S, Ding R, et al. Necrotizing Scleritis and Peripheral Ulcerative Keratitis Associated with Wegener's Granulomatosis. *Ophthalmol Ther*. 2013; 2(2): 99-111.
- [18] Akpek EK, Uy HS, Christen W, et al. Severity of episcleritis and systemic disease association. *Ophthalmology*. 1999; 106(4): 729-731.
- [19] Sainz de la Maza M, Foster CS, Jabbur NS. Scleritis associated with systemic vasculitic diseases. *Ophthalmology* 1995; 102: 687-692.
- [20] Watson PG, Hayreh SS. Scleritis and episcleritis. *Br J Ophthalmol* 1976; 60(3): 163-191.
- [21] Jabs DA, Mudun A, Dunn JP, et al. Episcleritis and scleritis: clinical features and treatment results. *Am J Ophthalmol* 2000; 130(4): 469-476.
- [22] Cocho L, Gonzalez-Gonzalez LA, Molina-Prat N, et al. Scleritis in patients with & granulomatosis with polyangiitis (Wegener). *Br J Ophthalmol* 2016; 100: 1062-1065.
- [23] Bernauer W, Pleisch B, Brunner M. Five-year outcome in immune-mediated scleritis. *Graefes Arch Clin Exp Ophthalmol* 2014; 252: 1477-1481.
- [24] Hoang LT, Lim LL, Vaillant B, et al. Antineutrophil cytoplasmic antibody-associated active scleritis. *Arch Ophthalmol*. 2008; 126(5): 651-655.
- [25] Rosenbaum JT. The eye and rheumatic diseases. In: Firestein GS, Budd RC, Gabriel SE, McInnes IB, O'Dell JR (eds) Kelley and Firestein's textbook of rheumatology. Philadelphia, Elsevier, 2017 pp 645-653 (Chapter 44).
- [26] Wieringa WG, Wieringa JE, ten Dam-van Loon NH, et al. Visual outcome, treatment results, and prognostic factors in patients with scleritis. *Ophthalmology*. 2013; 120: 379-386.
- [27] Foster CS, Forstot SL, Wilson LA. Mortality rate in rheumatoid arthritis patients developing necrotizing scleritis or peripheral ulcerative keratitis. Effects of systemic immunosuppression. *Ophthalmology* 1984; 91(10): 1253-1256.
- [28] Messmer EM, Foster CS. Vasculitic peripheral ulcerative keratitis. *Surv Ophthalmol* 1999; 43: 379-396.
- [29] García C, Voorduyn S, Pedroza-Seres M. Diagnosis of Wegener's granulomatosis in patients with ocular inflammatory disease. *Gac Med Mex* 2006; 142(6): 477-482.
- [30] Smith VA, Hoh HB, Easty DL. Role of ocular metalloproteinases in peripheral ulcerative keratitis. *Br J Ophthalmol* 1999; 83: 1376-1383.
- [31] Sainz de la Maza M, Foster CS, Jabbur NS, et al. Ocular characteristics and disease associations in scleritis-associated peripheral keratopathy. *Arch Ophthalmol* 2002; 120: 15-19.

- [32] Tauber J, Sainz de la Maza M, Hoang-Xuan T, et al. An analysis of therapeutic decision making regarding immunosuppressive chemotherapy for peripheral ulcerative keratitis. *Cornea* 1990; 9(1): 66-73.
- [33] Ebrahimiadib N, Modjtahedi BS, Roohipoor R, et al. Successful Treatment Strategies in Granulomatosis with Polyangiitis-Associated Peripheral Ulcerative Keratitis. *Cornea*. 2016; 35(11): 1459-1465.
- [34] Spalton DJ, Graham EM, Page NG, et al. Ocular changes in limited forms of Wegener's granulomatosis. *Br J Ophthalmol* 1981; 65(8): 553-563.
- [35] Cassan SM, Coles DT, Harrison EG Jr. The concept of limited forms of Wegener's granulomatosis. *Am J Med* 1970; 49: 366-379.
- [36] du Huong LT, Tran TH, Piette JC. Granulomatous uveitis revealing Wegener's granulomatosis. *J Rheumatol* 2006; 33: 1209-1210.
- [37] Gheita TA, Abd El Latif EM. Relationship of ocular presentation in granulomatosis with polyangiitis to autoantibodies and disease activity. *Z Rheumatol*. 2019; 78(3): 281-286.
- [38] Harman LE, Margo CE. Wegener's granulomatosis. *Surv Ophthalmol* 1998; 42: 458-480.
- [39] Bullen CL, Liesegang TJ, McDonald TJ, et al. Ocular complications of Wegener's granulomatosis. *Ophthalmology* 1983; 90 (3): 279-290.
- [40] Lin M, Anesi SD, Ma L, et al. Characteristics and Visual Outcome of Refractory Retinal Vasculitis Associated with Antineutrophil Cytoplasm Antibody-Associated Vasculitides. *Am J Ophthalmol*. 2018; 187: 21-33.
- [41] Venkatesh P, Chawla R, Tewari HK. Hemiretinal vein occlusion in Wegener's granulomatosis. *Eur J Ophthalmol* 2003; 13: 722-725.
- [42] Wang M, Khurana RN, Sadda SR. Central retinal vein occlusion in Wegener's granulomatosis without retinal vasculitis. *Br J Ophthalmol*. 2006; 90(11): 1435-1436.
- [43] Kubaisi B, Abu Samra K, Foster CS. Granulomatosis with polyangiitis (Wegener's disease): An updated review of ocular disease manifestations. *Intractable Rare Dis Res*. 2016; 5(2): 61-69.
- [44] McNab AA. The 2017 Doyné Lecture: the orbit as a window to systemic disease. *Eye (Lond)*. 2018; 32(2): 248-261.
- [45] Jiang B, Zhao YY, Wei SH. Granulomatosis with polyangiitis: the relationship between ocular and nasal disease. *Ocul Immunol Inflamm*. 2013; 21(2): 115-118.
- [46] Holle JU, Voigt C, Both M, et al. Orbital masses in granulomatosis with polyangiitis are associated with a refractory course and a high burden of local damage. *Rheumatology (Oxford)* 2013; 52(5): 875-882.
- [47] Hoffman GS, Kerr GS, Leavitt RY et al. Wegener's granulomatosis: an analysis of 158 patients. *Ann Intern Med*. 1992; 116(6): 488-498.
- [48] Jinnah HA, Dixon A, Brat DJ, et al. Review chronic meningitis with cranial neuropathies in Wegener's granulomatosis. Case report and review of the literature. *Arthritis Rheum* 1997; 40(3): 573-577.
- [49] Chung S, Monach PA. Anti-neutrophil cytoplasmic antibody-associated vasculitis. In: Firestein GS, Budd RC, Gabriel SE, McInnes IB, O'Dell JR (eds) Kelley and Firestein's textbook of rheumatology. Philadelphia, Elsevier, 2017, pp 1541-1558 (Chapter 89)
- [50] Woo TL, Francis IC, Wilcsek GA et al. Australasian orbital and adnexal Wegener's granulomatosis. *Ophthalmology* 2001;108(9);1535-1543.
- [51] Ismailova DS, Abramov JV, Novikov PI, et al. Clinical features of different orbital manifestations of granulomatosis with polyangiitis. *Graefes Arch Clin Exp Ophthalmol*. 2018;256(9):1751-1756.
- [52] Fauci AS, Wolff SM, Johnson JS. Effect of cyclophosphamide upon the immune response in Wegener's granulomatosis. *N Engl J Med* 1971; 285 (27):1493-1496.
- [53] Novack SN, Pearson CM. Cyclophosphamide therapy in Wegener's granulomatosis. *N Engl J Med* 1971; 284 (17):938-942.
- [54] Stone JH, Merkel PA, Spiera R, et al. Rituximab versus cyclophosphamide for ANCA-associated vasculitis. *N Engl J Med* 2010; 363 (3):221-232.
- [55] Jones RB, Tervaert JW, Hauser T, et al. Rituximab versus cyclophosphamide in ANCA-associated renal vasculitis. *N Engl J Med* 2010; 363 (3):211-220.
- [56] Huerva V, Sanchez MC, Traveset A, et al. Rituximab for peripheral ulcerative keratitis with Wegener's granulomatosis. *Cornea* 2010; 29 (6):708-710.
- [57] You C, Ma L, Lasave AF, et al. Rituximab Induction and Maintenance Treatment in Patients with Scleritis and Granulomatosis with Polyangiitis (Wegener's). *Ocul Immunol Inflamm* 2018; 26(8):1166-1173.
- [58] Seo P, Specks U, Keogh KA. Efficacy of rituximab in limited Wegener's granulomatosis with refractory granulomatous manifestations. *J Rheumatol* 2008; 35:(10):2017-2023.
- [59] Ahmed A, Foster CS. Cyclophosphamide or Rituximab Treatment of Scleritis and Uveitis for Patients with Granulomatosis with Polyangiitis. *Ophthalmic Res*. 2019; 61(1):44-50.