

Clinical Features and Treatment Results of Conjunctival Melanoma: Cross-Sectional Study

İrem Koç¹

ORCID: 0000-0001-9370-6173

Yasemin Kapucu¹

ORCID: 0000-0002-9126-8875

Hayyam Kıratlı¹

ORCID: 0000-0003-2100-4740

¹ Ophthalmology Department, Ocular Oncology Service, Hacettepe University Faculty of Medicine, Ankara, Türkiye.

Corresponding Author: İrem Koç

E-mail: kocirem@gmail.com

Received: 21 January 2023, Accepted: 3 March 2023,

Published online: 31 March 2023

ABSTRACT

Purpose: Our aim in this study is to report the clinical features and treatment results of patients with conjunctival melanoma (CM) diagnosed in our clinic in the last 20 years.

Materials and Methods: Demographic information, tumor diameter, accompanying melanosis, presence of recurrence and survival data were obtained retrospectively from the records of patients who had histopathologically confirmed CM diagnosis.

Results: Conjunctival melanoma was detected in 84 eyes of 84 patients with a mean age of 61.5 ± 24.6 years. In total 45.2% of the patients were female and 54.8% were male. The two most common primary lesion locations were limbus in 23.8% and bulbar conjunctiva in 22.6% of the patients. In ophthalmological evaluation, 46.3% of the patients had concomitant primary acquired melanosis. Appropriate surgical excision to the extent of the disease was performed primarily in all patients. After a median follow-up of 55 months, local recurrence rate was 45.2%, while the survival rate was found to be 74.3%.

Conclusion: Conjunctival melanoma is a malignant neoplasm seen in advanced adulthood, often involving the bulbar surface of the conjunctiva. Even using the standard surgical approach, CM is associated with a 45.2% local recurrence rate and a 25.7% mortality rate. In our study, there was no clinical parameter that showed a statistically significant relationship with survival.

Keywords: Conjunctiva, melanoma, excision, cryotherapy.

INTRODUCTION

Conjunctival melanoma (CM), constituting approximately 5% of all ocular melanomas, is a malignant ocular surface tumor that is formed by malignant transformation of normally residing conjunctival melanocytes [1]. Population-based studies in the literature present findings that CM incidence has been increasing over time [2,3]. Conjunctival melanoma, which constitutes approximately 25% of melanocytic conjunctival tumors, is most commonly seen in Caucasians [4]. Conjunctival melanoma may arise either from

primary acquired melanosis (PAM), conjunctival nevus or occur de novo [5]. In addition to the basic principle in the primary treatment of CM being surgical excision performed with no-touch technique; local recurrence, distant metastasis and even death are not uncommon despite appropriate surgery [1,5,6]. Our aim in this study is to report the findings and treatment results of CM patients who were diagnosed and treated in our hospital which serves as a tertiary health care clinic in our country.

MATERIALS AND METHODS

Patients who applied to Hacettepe University Faculty of Medicine, Ocular Oncology Service and received histopathological diagnosis of CM between October 2000 and October 2020 were included in the retrospective cross-sectional study. The study was approved by Hacettepe University Non-Interventional Clinical Research Ethics Committee with decision number 2019/17-52. The study was conducted in accordance with the Declaration of Helsinki.

Patients' information obtained from Hacettepe University electronic data system, Ocular Oncology Service records and anterior segment photographic archive included: age at diagnosis, gender, location of the primary lesion, base width of primary lesion in clock hours, distance of the lesion's closest border to limbus, presence of accompanying PAM, extent of PAM if present, degree of pigmentation

of the primary lesion, treatment of the primary lesion, presence of local recurrence, survival status and duration of follow-up. If a multifocal lesion was observed at the time of admission, the characteristics of the largest lesion were recorded.

In confined lesions with a base width of less than 1 cm, lesion localization was categorized in 4 classes as: limbus, bulbar conjunctiva, tarsal conjunctiva or caruncle (Figure 1). Because of the involvement of more than one category, this classification was not applied in more diffuse or giant tumors where the base of the lesion was larger than 1 cm. Additionally, the base width of tumors in which the base of the tumor could be evaluated was noted in clock hours. The extent of PAM was defined as focal in cases of involvement less than $\frac{1}{4}$ of the total conjunctival surface, and diffuse in cases of more extensive involvement (Figure 1).

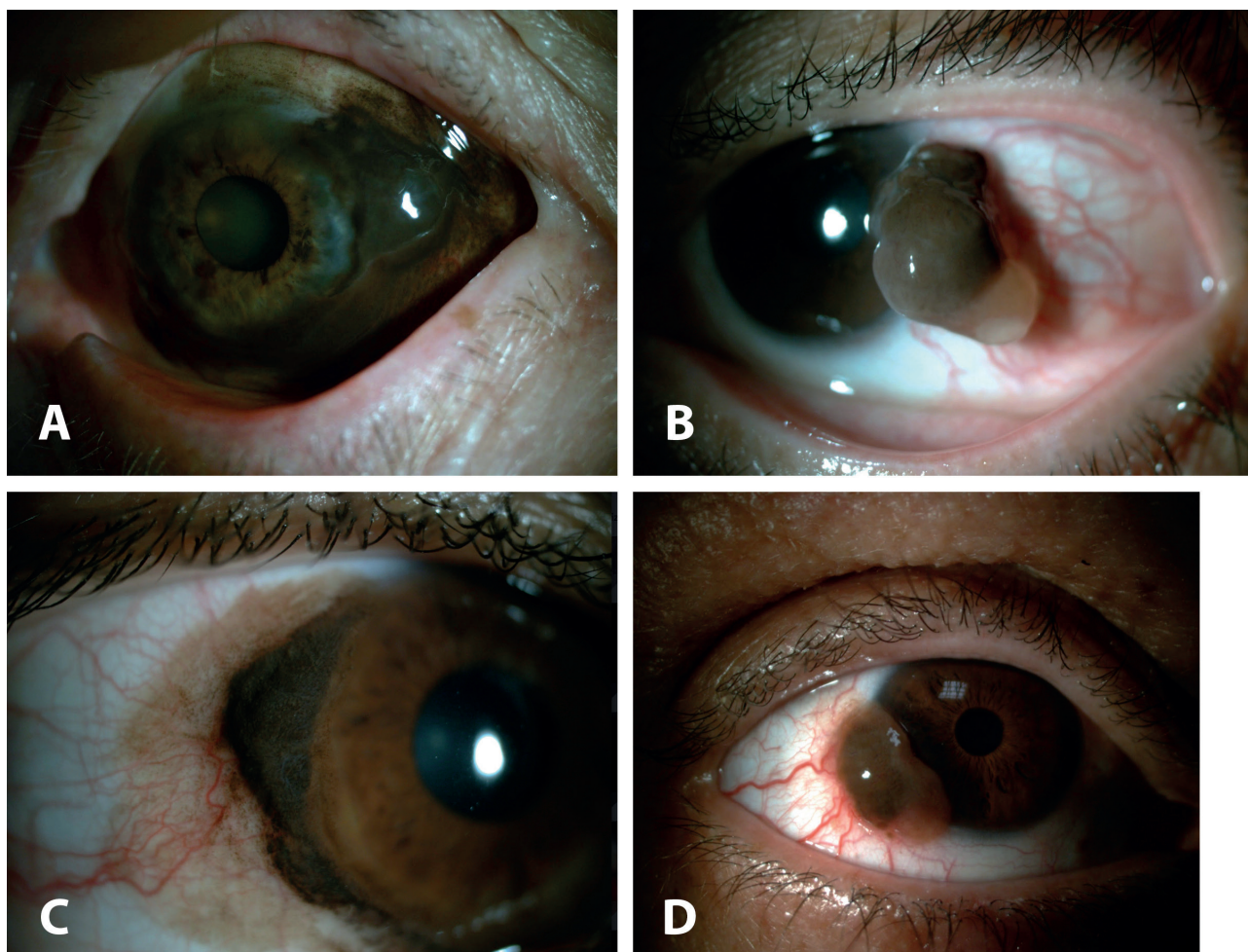


Figure 1. A. Diffuse melanoma with a wide base B. Melanoma with a mixed pigmentation pattern C. Limbal melanoma with diffuse primary acquired melanosis D. Melanoma with a dilated feeder vessel, as described in the study.

In our clinic, surgical removal is adopted as the gold standard in the treatment of CM and its recurrences. In cases where there is no clinical suspicion of scleral or orbital invasion, surgical principles defined in the literature aiming negative surgical margins were used as standard treatment of CM. Enucleation and orbital exenteration were offered in the presence of deep scleral invasion or intraocular invasion or in the presence of orbital involvement, respectively. If the histopathological surgical margin was positive adjuvant topical IFN α 2 β or 5-FU were used until 2018 and after 2018, respectively, due to the difficulties in the supply of IFN α 2 β following 2018. Dosing schedule was arranged on a patient basis.

In the study, IBM SPSS Statistics for Windows program was used for descriptive statistics and Kaplan Meier analysis (Version 23, IBM Corp., Armonk, N.Y., USA). In descriptive statistics mean and standard deviation or median and range of values were included. T-test and Mann-Whitney U test were used to compare the quantitative data with and without normal distribution between the two groups, respectively.

RESULTS

A total of 84 eyes of 84 patients were analyzed retrospectively. Of the patients, 38 (45.2%) were female and 46 (54.8%) were male. The mean age of the patients was 61.5 \pm 24.6 years (range: 22-100), and there was no statistically significant difference between genders ($p=0.680$). Primary lesion localization was limbus in 20 patients (23.8%), bulbar conjunctiva other than limbus in 19 patients (22.6%), caruncle in 7 patients (8.3%), and palpebral conjunctiva in 5 patients (6.0%). Tumors involving more than one of these compartments were encountered in 20 patients (23.8%). While PAM was present in 25 (46.3%) of anatomically limited tumors in which the presence of PAM could be evaluated, it was not observed in 29 cases (53.7%). Of 25 patients with PAM, focal PAM was detected in 10 (40.0%) and diffuse PAM (60.0%) in 15. In patients whose primary tumor pigmentation could be evaluated, 40 (66.7%) had melanotic, 6 (10.0%) showed amelanotic and 14 (23.3%) had tumors with both melanotic and amelanotic components. In tumors where the base of the lesion could be evaluated in terms of clock hours, the median tumor

diameter was found to be 4 (range: 1-12). Excluding the tumors primarily located at the limbus, median distance from closest corneal side to limbus was 3.5 mm (range: 0.5-13.0). Multifocal tumors at the time of admission were seen in 4 (4.8%) patients. One (1.1%) patient had enucleation due to recurrence with intraocular spread, 2 (2.4%) patients had primary orbital exenteration due to orbital spread at the time of admission, and two (2.4%) patients received secondary orbital exenteration due to recurrence with orbital spread during follow-up.

The median follow-up time from the initial time of diagnosis was 55 months (range: 6-250). During the whole follow-up period, local disease recurrence was observed in 14 patients (45.2%), while recurrence was not observed in 17 patients (54.8%) after initial treatment. The survival rate of the patients with follow-up data after a median of 55 months was 74.3% ($n=26$). The cause of death in 9 patients (25.7%) who were deceased was found to be distant metastasis of CM. Death occurred after an average of 45.9 \pm 20.7 months from the time of initial CM diagnosis. In the linear regression analysis, no statistically significant correlation was found between age, gender, location of the primary lesion, the diameter of the lesion in clock hours, the degree of pigmentation or presence of recurrence with overall survival in univariate analysis, thus further multivariate analyses were not applied.

DISCUSSION

Histologically, the conjunctival epithelium possesses a non-keratinized stratified squamous epithelium. Normally, in the basal layer of this conjunctival epithelium, melanocytes are expected to be seen in a small number and proportion compared to the basal epithelial layer cells. Benign or malignant lesions arising from these melanocytes are frequently encountered in ophthalmology practice. When lesions originating from conjunctival melanocytes are evaluated as a whole, approximately 1/4 of all conjunctival melanocytic lesions are found to be CM and 1/4 is described as PAM, which is considered a precursor to CM [4,7]. Clinically, CM can initially be diagnosed as a maculopapular or nodular lesion with melanotic, amelanotic or combined pigmentation as a mobile or immobile mass depending on its extent [1]. It can occur in any part of the conjunctiva and may

contain dilated feeder vessels [1]. Conventional primary treatment consists of surgical excision with 2-3 mm clear margins, with or without cryotherapy to remaining conjunctival borders [6,8]. Additional superficial sclerectomy or orbital exenteration may be preferred in cases with suspicion of superficial scleral involvement or orbital spread, respectively [6,8]. Adjuvant topical chemotherapy, plaque brachytherapy or external beam radiotherapy can be applied in case of suspected or biopsy-proven residua disease [8].

In our study, consistent with the literature, at the time of diagnosis of CM there was a slight male predominance (54.8% vs. 45.2%) with a mean age at diagnosis of 61.5 years, and no pediatric cases were observed [4].

In the literature, it has been shown that the diagnosis of PAM, which is considered a precursor of CM, occurs at a statistically earlier age than CM, supporting the chronology of CM development from PAM [4,9]. The most two common primary lesion locations are found to be limbus and non-limbal bulbar conjunctiva with 23.8% and 22.6% frequencies in the present study. These results are consistent with the expectation that 83.5% - 92% of CM would be seen on the bulbar side of the conjunctiva and the remaining 16.5% in the non-bulbar conjunctiva [8,10]. The frequency of PAM accompanying the primary lesion is 46.3%, 60% of which corresponds to diffuse PAM; however, no prognostic effect of this finding on survival was found. The extent of the lesion precluded the compartment classification and lesion diameter measurement as described above in methods in 23.8% of cases which points to advanced and extensive tumors in nearly 1/4th of our patients. For this reason, it was not possible to draw solid conclusions from comparison of our results with the larger series in the literature in which smaller CM cases accounted for a larger proportion [4,11]. Considering that in the largest series in which primary lesion involved 4.6 clock hours and the mean basal diameter is 10.8-12.5 mm, the patients who applied to our clinic presented with more advanced stages and more widespread disease [4,11].

In our study, a statistically significant regression model could not be established for the factors

affecting the development of local recurrence due to the insufficient sample size. Five-year local recurrence rates in the literature vary between 26% and 66% and the recurrence rate of 45.2% seen after 55 months of follow-up in our study is consistent with these data [10-13]. When age, gender, location of the primary lesion, the diameter of the lesion in clock hours, the degree of pigmentation and the presence of recurrence were evaluated with univariate regression analysis as the clinical parameters which could possibly affect survival, no parameter showing a statistically significant relationship with survival was found. In the literature, however, various risk factors have been presented for development of CM metastasis and death. These include: positive surgical margins, tumor location outside the limbus, presence of local recurrence, tumor thickness, tumor diameter, advanced age, male gender, T4 tumors, lymph node involvement at the time of diagnosis, histopathological tumor thickness and ulceration [2,10,13-15].

The main limitations of our study include the limited number of patients and limited follow-up data. Tumor, node and metastasis classification could not be used due to high proportion of patients presenting with diffuse disease. In order to examine the factors affecting local recurrence and survival in detail, multicenter prospective studies and evaluation of additional factors such as histopathological prognostic criteria hold great importance.

CONCLUSION

Although conjunctival melanoma is a rare disease, it is a malignant tumor that should be treated and followed meticulously. Despite appropriate treatment, long-term follow-up is required in terms of local recurrence and metastasis, especially in cases presenting with advanced disease.

Author contribution

Study conception and design: İK, YK, HK; data collection: İK, YK; analysis and interpretation of results: İK, YK, HK; draft manuscript preparation: İK, YK, HK. All authors reviewed the results and approved the final version of the manuscript.

Ethical approval

The study was approved by the Hacettepe University Non-Interventional Clinical Research Ethics Committee (Protocol no. 2019/17-52).

Funding

The authors declare that the study received no funding.

Conflict of interest

The authors declare that there is no conflict of interest.

 REFERENCES 

- [1] Seregard S. Conjunctival melanoma. *Surv Ophthalmol.* 1998;42(4):321-50.
- [2] Larsen AC. Conjunctival malignant melanoma in Denmark. Epidemiology, treatment and prognosis with special emphasis on tumorigenesis and genetic profile. *Acta Ophthalmol.* 2016;94(8):842.
- [3] Tuomaala S, Eskelin S, Tarkkanen A, Kivela T. Population-based assessment of clinical characteristics predicting outcome of conjunctival melanoma in whites. *Invest Ophthalmol Vis Sci.* 2002;43(11):3399-408.
- [4] Shields CL, Alset AE, Boal NS, Casey MG, Knapp AN, Sugarman JA, et al. Conjunctival tumors in 5002 cases. Comparative analysis of benign versus malignant counterparts. The 2016 James D. Allen Lecture. *Am J Ophthalmol.* 2017;173:106-33.
- [5] Shields CL, Chien JL, Surakiatchanukul T, Sioufi K, Lally SE, Shields JA. Conjunctival tumors: review of clinical features, risks, biomarkers, and outcomes--The 2017 J. Donald M. Gass Lecture. *Asia Pac J Ophthalmol (Phila).* 2017;6(2):109-20.
- [6] Shields JA, Shields CL, De Potter P. Surgical management of conjunctival tumors. The 1994 Lynn B. McMahan Lecture. *Arch Ophthalmol.* 1997;115(6):808-15.
- [7] Bresler SC, Simon C, Shields CL, McHugh JB, Stagner AM, Patel RM. Conjunctival melanocytic lesions. *Arch Pathol Lab Med.* 2022;146(5):632-46.
- [8] Jain P, Finger PT, Fili M, Damato B, Coupland SE, Heimann H, et al. Conjunctival melanoma treatment outcomes in 288 patients: a multicentre international data-sharing study. *Br J Ophthalmol.* 2021;105(10):1358-64.
- [9] Shields CL, Markowitz JS, Belinsky I, Schwartzstein H, George NS, Lally SE, et al. Conjunctival melanoma: outcomes based on tumor origin in 382 consecutive cases. *Ophthalmology.* 2011;118(2):389-95 e1-2.
- [10] Shields CL, Shields JA, Gunduz K, Cater J, Mercado GV, Gross N, et al. Conjunctival melanoma: risk factors for recurrence, exenteration, metastasis, and death in 150 consecutive patients. *Arch Ophthalmol.* 2000;118(11):1497-507.
- [11] Pacheco RR, Yaghy A, Dalvin LA, Vaidya S, Perez AL, Lally SE, et al. Conjunctival melanoma: outcomes based on tumour origin in 629 patients at a single ocular oncology centre. *Eye (Lond).* 2022;36(3):603-11.
- [12] Vaidya S, Dalvin LA, Yaghy A, Pacheco R, Shields JA, Lally SE, et al. Conjunctival melanoma: Risk factors for recurrent or new tumor in 540 patients at a single ocular oncology center. *Eur J Ophthalmol.* 2021;31(5):2675-85.
- [13] Missotten GS, Keijser S, De Keizer RJ, De Wolff-Rouendaal D. Conjunctival melanoma in the Netherlands: a nationwide study. *Invest Ophthalmol Vis Sci.* 2005;46(1):75-82.
- [14] Jia S, Zhu T, Shi H, Zong C, Bao Y, Wen X, et al. American Joint Committee on Cancer Tumor Staging System predicts the outcome and metastasis pattern in conjunctival melanoma. *Ophthalmology.* 2022;129(7):771-80.
- [15] Abt NB, Zhao J, Huang Y, Eghrari AO. Prognostic factors and survival for malignant conjunctival melanoma and squamous cell carcinoma over four decades. *Am J Otolaryngol.* 2019;40(4):577-82.