

Giant Cervical Lipoma: A Case Report

Arda Küçüküven*, [MD]

Mert Çalış¹, [MD]

Figen Özgür¹, [MD]

ABSTRACT

Lipomas are benign soft tissue tumors composed of adipose tissue. They are mobile, painless, well-circumscribed, slow-growing masses and have rubber-like consistency. They may be localized in almost all body parts where the fat tissue is present and may be in a giant form. Mass localization may also cause functional limitations. Giant lipomas of the neck are very rarely seen. In the present study, we reported a 59-year-old man who presented with a cervical mass enlarged in a time period of 10 years. During 21 months of postoperative period, cosmetic and functional results of the surgery were excellent. Any recurrence was not detected. After surgery, patient's restriction of body function was disappeared.

Key Words: Giant, lipoma, neck, surgery

¹Hacettepe University Faculty of Medicine,
Department of Plastic Reconstructive and Aesthetic
Surgery, Ankara, Turkey

* Corresponding Author: Arda Küçüküven,
Hacettepe University Faculty of Medicine,
Department of Plastic Reconstructive and Aesthetic
Surgery, Ankara, Turkey
e-mail: ardakucukguven@gmail.com

Received: 6 February 2018, Accepted: 24 March 2018,
Published online: 31 March 2018

INTRODUCTION

Lipomas are encapsulated masses that make up 50% of all benign soft tissue neoplasms with an estimated annual incidence of one per 1,000 persons. These tumors composed of mature adipocytes. They may grow slowly without any symptoms in any region where the fat tissue is present. Other than cosmetic reasons, it could take time to notice[1]. %13 of all lipomas are seen in head and neck region. Mostly they locate posteriorly and subcutaneously [2-3]. They usually appear as mobile, soft, well-circumscribed masses in neck region. Although lipomas can occur at any age, they most often appear

during 4th or 6th decades of life.

80% of all lipomas are less than 5 cm in size at first visit to hospital[4]. Lipomas bigger than 10 cm or heavier than 1000 gr are called giant lipomas [5]. It may be confusing to differentiate lipomas from malignant tumors. Surgical excision is the definitive treatment of lipomas and recurrence rate is 1-2% after enucleation [6]. In this study, we aimed to present a 59-year-old male patient with a painless giant lipoma, which was found to be 108x138x165 mm in size, located at the back of the neck and to review the literature.

CASE PRESENTATION

A 59-year-old male patient was referred to our hospital with a palpable mass at the back of the neck for 10 years. He had a history of slow-growing mass without any signs of inflammation or decreasing in size. There was some discomfort and limitation of head movement caused by the tumor. It was learnt

that the patient underwent an excision of a small tumor from the back of the thorax 15 years ago. Physical examination revealed a soft, mobile, painless giant tumor filling the posterior cervical region (Figure 1).

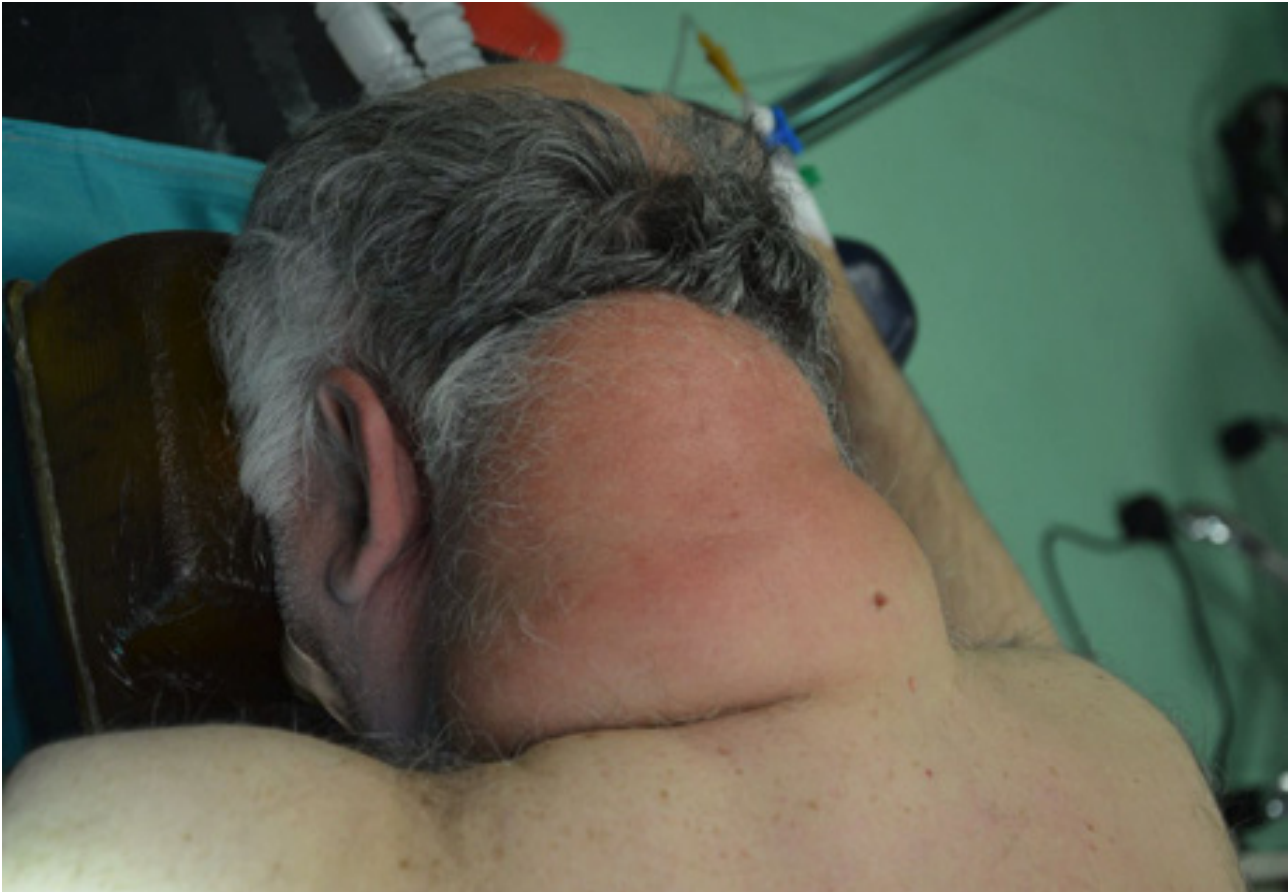

Figure 1: Giant lipoma located at the back of the neck.

There was no any erythema or edema of the skin covering the tumor. There was no other palpable mass at the head and neck region. The patient had no history of head and neck surgery or trauma and did not have any systemic diseases such as granulomatous disease, HIV infection, autoimmune disease which could cause formation of a palpable mass.

Magnetic resonance imaging (MRI) showed a lipomatous tumor extending from upper thoracic vertebrae to occipital bone and located subcutaneously at the back of the neck. It was 108x138x165 mm in size. It was reported that the tumor was

well-circumscribed with a capsule and there was no infiltration into surrounding muscles (Figure 2).

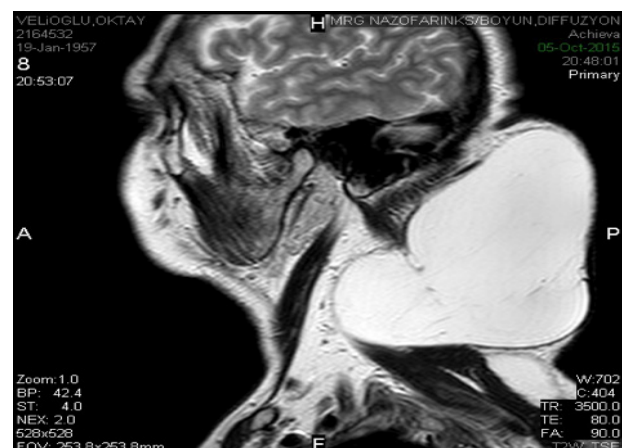


Figure 2: Lipoma in sagittal section, MRI

Patient was operated under general anesthesia with preliminary diagnosis of lipoma. An eclipitic incision parallel to skin folds was designed and encapsulated lipoma with a small skin island was excised in one piece (Figure 3). One Jackson-Pratt drain was placed to prevent hematoma and it was removed 2 days later. No postoperative complication has been seen (Figure 4) and the pathology report confirmed preliminary diagnosis. There was no recurrence and the patient was symptom-free at his 21-month follow-up.

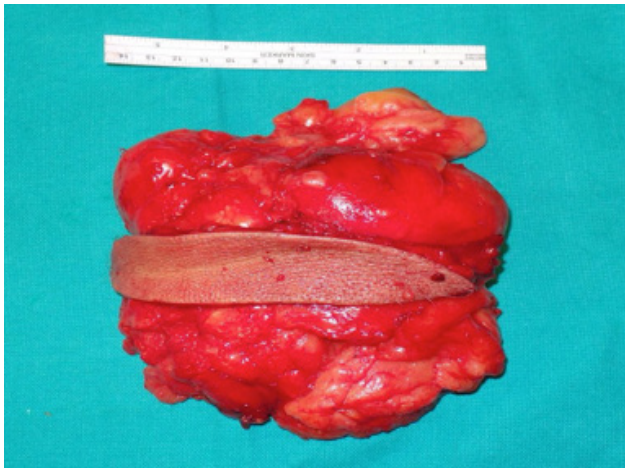

Figure 3: Excised lipoma with skin island.

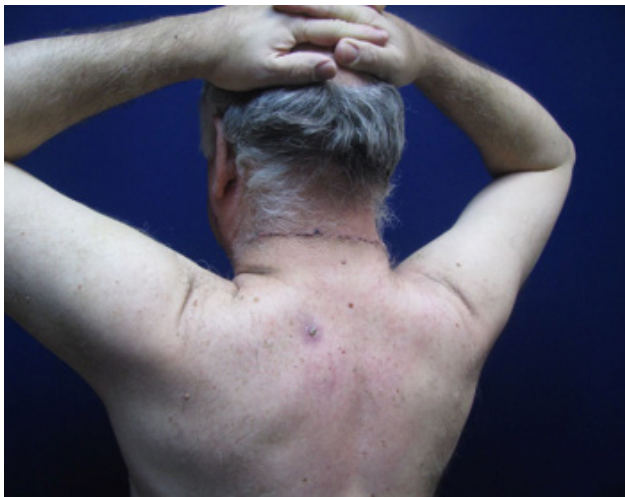

Figure 4: Postoperative view

DISCUSSION

Lipomas usually present as a solitary, painless, slow-growing masses and account for 4-5% of all benign tumors [7]. Lipomas occur more often in overweight people and increase in size if patient gains weight. But it is reported that there is no

direct relationship between weight loss and shrinkage of lipoma[8]. Lipomas are mostly asymptomatic and usually patients come for cosmetic reasons. In some cases, they can reach giant size and cause severe cosmetic impairment. The giant cervical lipoma, which was neglected for 10 years by our patient, was measured as 108x138x165 mm.

The etiology and pathogenesis of lipomas remain unknown, although genetic endocrine and traumatic factors have been suggested[9]. There was no any systemic disease, family or trauma history in our case.

The differential diagnosis between giant lipoma and liposarcoma is of great importance. Liposarcomas are well-circumscribed but not encapsulated tumors. They usually occur in the limbs, retroperitoneum and mediastinum whereas lipomas are mostly located subcutaneously. Mitosis is a good parameter to distinguish liposarcoma from lipoma histologically. Additionally, fat necrosis, muscle and bone invasion should raise suspicion of liposarcoma. Epidermal cysts, hemangiomas, abscess, necrotic lymph nodes, cystic hygroma, neurofibroma and malignant fibrous histiocytoma should be considered in differential diagnosis of lipoma at the neck region[10].

Ultrasonography is an inexpensive, easy and harmless diagnostic tool that can be done as an initial examination of tumors of the neck. Typically, lipomas are seen homogenous with regular margins in both CT and MRI. The characteristic images of lipomas have low attenuation and few or no thin fibrous septa[8]. MRI is superior to CT for parenchymal evaluation and boundary delineation in lipomas. Lipomas show homogeneous hyperintense fat signal on T1-weighted MR images whereas they show fat-suppression in T2-weighted images as in our case[11].

In conclusion, giant lipomas are very rarely seen in the neck region and they may cause functional limitations. A preoperative MRI or CT imaging can be helpful in evaluation of the accurate tumor extent and its relation to adjacent tissues. Recurrence is very rare if the lipoma is completely excised with its capsule and a definite histopathologic diagnosis will be reached at this point.

CONSENT

Written informed consent was obtained from the patient for publication of this case report and accompanying images. A copy of the written consent is available for review if requested.

CONFLICT OF INTEREST

The authors have no conflicts of interest to disclose.

REFERENCES

- [1] Grecchi F, Zollino I, Candotto V, et al. A case of lipoma of lateral anterior neck treated with surgical enucleation. *Dent Res J (Isfahan)* 2012; 9: S225-228.
- [2] Kim KS, Yang HS. Unusual locations of lipoma: Differential diagnosis of head and neck mass. *Aust Fam Physician* 2014; 43: 867-870.
- [3] Mehdiyev H. Anterior Servikal Dev Lipom: Olgu Sunumu. *Firat Tıp Dergisi* 2009; 14(1): 101-103.
- [4] Luba MC, Bangs SA, Mohler AM, et al. Common benign skin tumors. *Am Fam Physician* 2003; 67: 729-738.
- [5] Sanchez MR, Golomb FM, Moy JA, et al. Giant lipoma: case report and review of the literature. *J Am Acad Dermatol* 1993; 28: 266-268.
- [6] Scherl MP, Som PM, Biller HF, et al. Recurrent infiltrating lipoma of the head and neck. Case report and literature review. *Arch Otolaryngol Head Neck Surg* 1986; 112: 1210-1212.
- [7] De Vincentiis M, Greco A, Mascelli A, et al. Lipoma of the larynx: a case report. *Acta Otorhinolaryngol Ital* 2010; 30: 58-63.
- [8] El-Monem MH, Gaafar AH, Magdy EA. Lipomas of the head and neck: presentation variability and diagnostic work-up. *J Laryngol Otol* 2006; 120: 47-55.
- [9] Austin RM, Mack GR, Townsend CM, et al. Infiltrating (intramuscular) lipomas and angioliipomas. A clinicopathologic study of six cases. *Arch Surg* 1980; 115: 281-284.
- [10] Som PM, Scherl MP, Rao VM, et al. Rare presentations of ordinary lipomas of the head and neck: a review. *AJNR Am J Neuroradiol* 1986; 7: 657-664.
- [11] Durr ML, Agrawal N, Saunders JR, et al. Laryngeal lipoma associated with diffuse lipomatosis: case report and literature review. *Ear Nose Throat J* 2010; 89: 34-37.

