


ACTA MEDICA

Volume 54 • Supp 2 • 2023

formerly
Hacettepe
Medical
Journal



from the seniors to the students



ACTA MEDICA

formerly Hacettepe Medical Journal

www.actamedica.org

Vol 54 • Supplement 2 • 2023

23rd National Anatomy Congress



online ISSN: 2147-9488

ACTA MEDICA

online ISSN: 2147-9488

www.actamedica.org

Cilt 54, Supplement 2, 2023

Hacettepe Üniversitesi Tıp Fakültesi adına sahibi
Deniz Demiryürek

Sorumlu Yazı İşleri Müdürü
Gülen Eda Utine

Yayının Türü
Yaygın Süreli Yayının

Yayının Şekli
Üç aylık İngilizce

Baş Editör
Hakan Uzun

Editöryal İletişim
Hacettepe Üniversitesi
Tıp Fakültesi Dekanlığı
06100 Sıhhiye - Ankara
E-posta: editor@actamedica.org

Yayıncı
Hacettepe Üniversitesi
Tıp Fakültesi Dekanlığı
06100 Sıhhiye - Ankara
Telefon: 0 312 305 10 80
Belgeç (faks): 0 312 310 05 80
E-posta: tipmaster@hacettepe.edu.tr

Yayıncılık Hizmetleri
Akdema Bilişim ve Yayıncılık
Telefon: 0 533 166 80 80
E-posta: bilgi@akdema.com
Web: www.akdema.com

ACTA MEDICA

online ISSN: 2147-9488

www.actamedica.org

Vol 54, Supplement 2, 2023

Owner on behalf of the Hacettepe Medical School
Deniz Demiryürek

Administrator
Gülen Eda Utine

Publication Type
Peer-reviewed journal

Publication Frequency and Language
Quarterly, English

Editor-in-Chief
Hakan Uzun

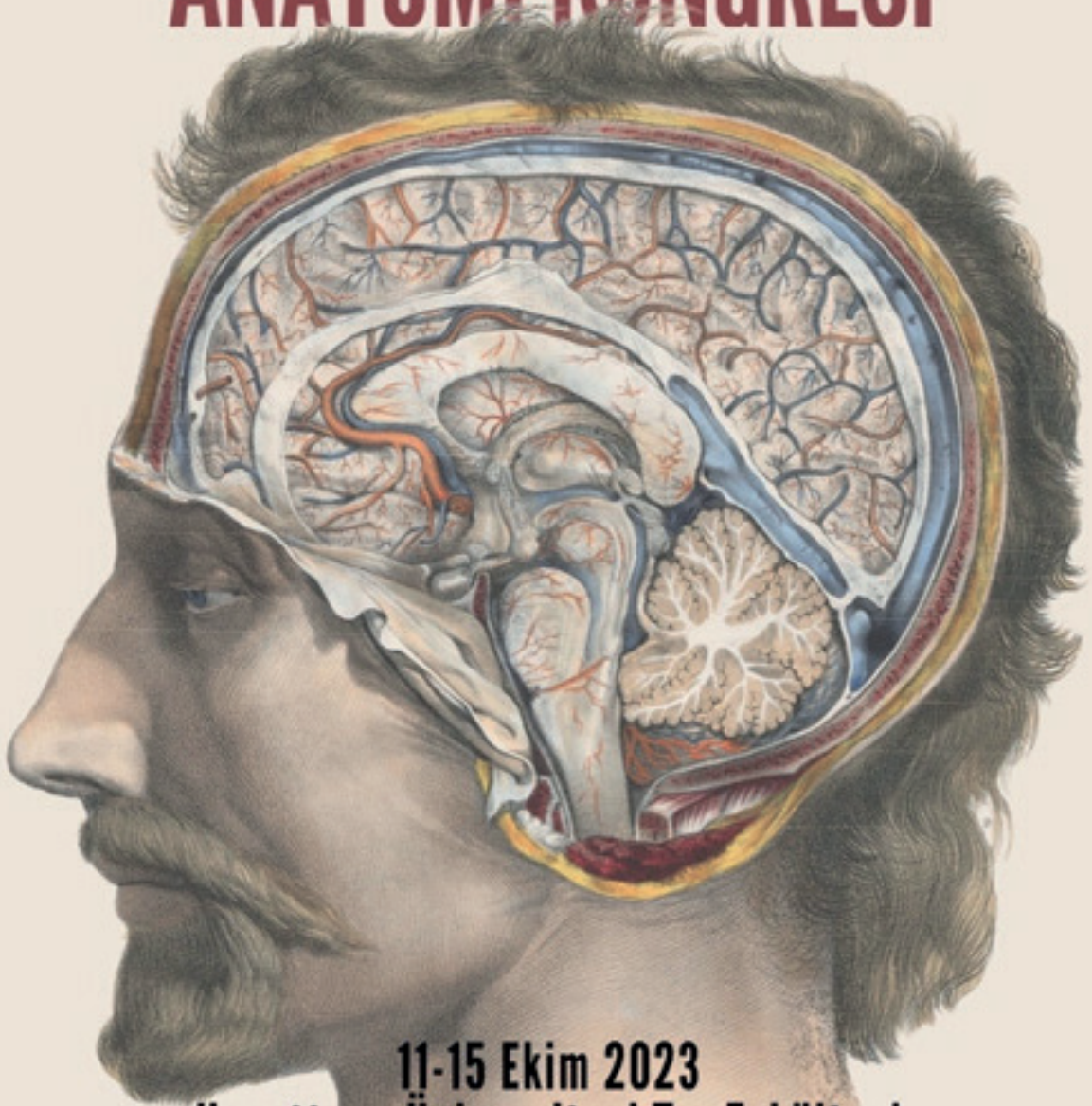
Editorial Office
Hacettepe University
Hacettepe Medical School
06100 Sıhhiye - Ankara
E-mail: editor@actamedica.org

Publisher
Hacettepe University
Hacettepe Medical School
06100 Sıhhiye - Ankara
Phone: +90 312 305 10 80
Fax: 0 312 310 05 80
E-mail: tipmaster@hacettepe.edu.tr

Publishing Services
Akdema Informatics and Publishing
Phone: +90 533 166 80 80
E-mail: bilgi@akdema.com
Web: www.akdema.com



23. ULUSAL ANATOMİ KONGRESİ




11-15 Ekim 2023
Hacettepe Üniversitesi Tıp Fakültesi
Ankara

Kongre Başkanı:
M. Deniz DEMİRYÜREK



TÜBİTAK

anatomikongresi2023.org

 [anatomikongresi.2023](https://www.instagram.com/anatomikongresi.2023)

İllüstrasyon: Nicolas Henri JACOB [1867]

23rd NATIONAL ANATOMY CONGRESS

October 11-15, 2023, Ankara, Türkiye

ORGANIZATION COMMITTEE

Honorary Congress President:

Professor Bedia SANCAK, MD, PhD

Professor Dođan AKŐIT, PhD

Congress President:

Professor Mehmet Deniz DEMİRYÜREK, MD, PhD

Secretary General:

Associate Professor Ceren GÜNENÇ BEŐER, MD, PhD

Assistant Professor Hilal AKDEMİR AKTAŐ, MD, PhD

Hasan BarıŐ ILGAZ, MD, PhD

Organization Committee:

Professor H. Hamdi ÇELİK, MD, PhD

Professor M. Mustafa ALDUR, MD, PhD

Professor C. Cem DENK, MD, PhD

Professor İlkan TATAR, MD, PhD

Associate Professor Ceren GÜNENÇ BEŐER, MD, PhD

Associate Professor Ayőegül FIRAT, MD

Associate Professor Burcu ERÇAKMAK GÜNEŐ, MD

Associate Professor Alper VATANSEVER, PhD

Assistant Professor Hilal AKDEMİR AKTAŐ, MD, PhD

Hasan BarıŐ ILGAZ, MD, PhD

Mehmet ÜLKİR, MD

Zeynep YILMAZ, MD

Helin YÜCEDAĐ GÜNDOĐDU, MD

Zehra ÇELİK, MD

Bahattin PASLI, MD

TuĐçe TAŐKINDERE ABBASOĐLU, MD

İbrahim Tuna AKDİŐ, MD

Ali Enes ALDUR, MD

Hüseyin GÜZEY, MD

Rukiye ÖNCEL, MD

Tolga KARABÖRKLÜ, MD

Pınar DEMİR GÜNDOĐMUŐ, MD

Jiyan TANRIKULU, MD

EXECUTIVE COUNCIL OF TURKISH SOCIETY OF ANATOMY AND CLINICAL ANATOMY (TSACA)

President: Professor Piraye KERVANCIOĞLU, MD

Vice-President: Professor Çağatay BARUT, MD, PhD

Vice-President: Professor Nadire ÜNVER DOĞAN, MD

Secretary General: Associate Professor İlke Ali GÜRSES, MD

Treasurer: Associate Professor Ceren GÜNENÇ BEŞER, MD, PhD

Member: Professor Ayhan CÖMERT, MD

Member: Assistant Professor Kerem ATALAR, PhD

SCIENTIFIC COMMITTEE

All members of the Turkish Society of Anatomy and Clinical Anatomy (TSACA).

All oral and poster presentations submitted to the congress were reviewed and scored by the scientific committee prior to the congress.

Our event has been entitled to receive The Scientific and Technological Research Council of Türkiye (TUBİTAK) "2223-B Grant Program for Organizing Scientific Meeting within the Country".



TÜBİTAK

Dear scientists,

As the Turkish Society of Anatomy and Clinical Anatomy and Hacettepe University, Faculty of Medicine, Department of Anatomy, we are honored to host the 23rd National Anatomy Congress with great pride and excitement.

This congress dedicated to the 100th anniversary of the Republic of Türkiye, It will be held in Ankara between 11-15 October 2023, in the light of reason and science, for the goal of "Contemporary and Great Turkey", as Mustafa Kemal Atatürk and his comrades dreamed of when they set out.

In this special event to be held on the 100th anniversary of the founding of Türkiye as a modern nation state and the 60th anniversary of the foundation of Hacettepe University Faculty of Medicine, academicians, researchers and those interested in anatomy will come together, anatomy education, macroscopic and microscopic anatomy, developmental anatomy and clinical anatomy will be evaluated in all aspects. In addition, up-to-date information on new research methods, technological advances and relations with related disciplines will be shared during the meeting.

Our Congress, will host many scientific sessions, seminars, workshops, presentations and exhibitions. Through these events, the participants will have the opportunity to share their current studies and researches with their colleagues, and will be inspired by the experiences and knowledge of valuable scientists, and they will have the chance to learn the most up-to-date information on developments in the field of anatomy.

Within the scope of the social programs to be held after the scientific meetings during the congress, our guests will have the opportunity to get to know Ankara and its surroundings better, which is known as the historical and cultural capital of our country, as well as one of the centers of developments in the field of modern medicine.

The abstracts of the papers presented at the congress will be published as supplements in the Acta Medica journal (www.actamedica.org) in the Ulakbim-Tr index.

As Hacettepe University Faculty of Medicine, we invite you to witness the achievements of our country in the field of anatomy and to discover the beauties of Ankara.

We would like to state once again that we will be honored and happy to see you among us at the 23rd National Anatomy Congress, and we want you to know that our team is ready to help you with whatever you need.

Yours sincerely,

Prof. Dr. Deniz Demiryürek
President of the Congress
Dean of Hacettepe University Faculty of Medicine

SCIENTIFIC PROGRAM

Thursday, October 12, 2023

09:00-10:00 OPENING LECTURES, INVITED SPEAKERS (HALL A)

Moderators: Prof. Dr. H. Hamdi ÇELİK, Prof. Dr. Deniz DEMİRYÜREK

I1 - Anatomy on the 100th Anniversary of the Republic of Türkiye

Doğan Akşit

I2 - Anatomy and bureaucracy

Muzaffer Şeker

I3 - Anatomy knowledge in hand surgery

Gürsel Leblebicioğlu

10:20-11:30/ ORAL PRESENTATIONS 1 (HALL A)

Moderators: Prof. Dr. Esat ADIGÜZEL, Assoc. Prof. Dr. İlke Ali GÜRSES

O72 - The frequency of the bony parameters of femoroacetabular impingement syndrome in young asymptomatic individuals: a computed tomography study

Menekşe Cengiz, Serra Öztürk, Ayşe Keven, Hande Salim, Murat Gölpinar, Kemal Gökkuş, Muzaffer Sindel

O64 - Gender comparison of acromion section area, acromial index, lateral acromial angle and critical shoulder angle in patients with shoulder impingement syndrome

Ayşe Baydere, Alper Atasever

O113 - Application of patellar type and patella related measurements in chondromalacia patella classification

Nizameddin Fatih Karamus, Mehmet Zahit Gül, Firat Sustam, Mustafa Büyükmumcu, Serdar Balsak, Özge Pasin

O4 - Does medial longitudinal arch morphometrics affect the formation of pes planus or pes cavus in patients with epin calcanei (heel spur)?

Gözde Cingöz, Tugrul Örmeci, Neslihan Yuzbasioglu

O24 - Radio-anatomical relationships between interdigital neuroma and hallux valgus angle

Birsen Arkar, Tuğrul Örmeci

O142 - Evaluation of the ankle and foot in MR images of patients with knee osteoarthritis

Ümmühan Yağmurkaya, Banu Ordahan, Ülkü Kerimoğlu, Duygu Akın Saygın, İsmihan İlknur Uysal

O60 - Evaluation of body donation records and updates on awareness activities in Mersin University

Zeliha Kurtoglu Olgunus, Alev Bobuş Örs

10:20-11:30/ ORAL PRESENTATIONS 1 (HALL B)

Moderators: Prof. Dr. Samet KAPAKIN, Assoc. Prof. Dr. Bora UZUNER

O128 - Radiographic analysis of spinopelvic alignment anatomy in scoliosis patients

Ozden Bedre Duygu, Figen Govsa Gokmen

O165 - The relationship between sternum ossification process and age with gender: a retrospective computed tomography study

Menşure Şahin, Necati Emre Şahin, Serkan Öner, Şeyma Toy, Zülal Öner

O131 - Radiological investigation of development of the knee joint in fetal period

Nazlı Ateş, Mehmet Ali Malas, Sevgi Ünal

O67 - Evaluation of coccyx morphology and morphometry in patients with ankylosing spondylitis

Ayfer Metin Tellioglu, Dilara İlyä, Yasemin Durum Polat

O116 - Is the morphometry of the medially protruding part of os naviculare related to the medial longitudinal arch?

Turan Koç, Asena Ayça Özdemir, Zeliha Kurtoğlu Olgunus, Alev Bobuş Örs

O15 - Assessment of gait symmetry and pelvic symmetry in children and adolescents with specific learning disorders and comparison with healthy controls

Yunus Emre Kundakcı, Emel Taşvuran Horata

O81 - Do Turkish anatomists prefer to continue teaching anatomy after death?

Begümhan Turhan, Melike Akcaalan, Menekşe Karahan

11:30-12:00 INVITED SPEAKER (HALL A)

Moderator: Prof. Dr. Behice DURGUN

I4 – Anatomy, magnetic resonance and diffusion tensor imaging of the human brainstem

Gülgün Şengül

13:00-13:30 INVITED SPEAKER (HALL A)

Moderator: Prof. Dr. İsmail Nadir GÜLEKON

I5 - A glimpse of anatomy from radiology

Adalet Elçin Yıldız

13:30-14:40/ ORAL PRESENTATIONS 2 (HALL A)

Moderators: Prof. Dr. Rabet GÖZİL, Prof. Dr. Meltem BAHÇELİOĞLU

O90 - Investigation of the effects of curcumin and resveratrol on the hippocampus in a streptozotocin induced Alzheimer's rat model

Derya Öztürk Söylemez, Dilek Sağır, Erdoğan Unur

O97 - Investigation of The Protective Effect of Chrysin Against Pemetrexed-Induced Liver Incurry In Rats

Beyza Özdemir, Evren Köse, Azibe Yıldız, Nesibe Yılmaz, Kevser Tanbek , Ayşegül Kısaoğlu, Süleyman Sandal

O110 - Evaluation of thalamus volume and cell numbers in adolescent autistic rats: A stereologic study

Erdal Horata, Hakan Ay

O10 - Evaluating noise stress on neuronal activation of rat's central nervous system

Alper Vatansever, Duygu Gök Yurtseven, Gonca Topal, Şule Mergen, İlker Mustafa Kafa, Gökhan Göktalay, Özhan Eyigör

O189 - Fractal geometry for determining the shapes and sizes of anatomical structures

Behice Durgun

O11 - Investigation of distal radius morphometry in adults and evaluation of its compliance with implants applied in distal radius fractures

Pelin İsmailođlu, Alp Bayramođlu, Güler Kahraman Yıldırım

13:30-14:40/ ORAL PRESENTATIONS 2 (HALL B)

Moderators: Prof. Dr. Nadire ÜNVER DOĐAN, Assist. Prof. Dr. Hilal AKDEMİR AKTAŞ

O121 - Penicillin dose dependant effect on primer astroglial cell line: It might be cell base epilepsy model

Mehmet Bülent Özdemir

O101 - Cystic duct opening variations: A preliminary study

Zekiye Karaca Bozdađ, Emre Bozdađ, Ayla Kürkçüođlu, Buse Naz Çandır, Süleyman Sönmez

O134 - Treatment of rat uterus with iloprost in experimental ischemia and reperfusion injury

Zümrüt Dođan, Ebru Annaç, Seda Çetin, Talip Karaçor

O71 - The effect of high-fat diet during prenatal and postnatal periods on subcutaneous white adipose tissue adipocyte diameters

Gülay Madan, Yüksel Aydar

O125 - Investigation of the effectiveness of atmospheric pressure cold plasma on sciatic nerve injury in rats

Nesibe Yılmaz, Ömür Gülsüm Deniz, Şeyda Seçgin, Yusuf Secgin, Ferhat Bozduman

O120 - Effect of various doses of metformin on map-kinase and apoptosis in penicillin-induced secondary rat cortical astrocytes-can metformin be antiepileptic?

Hülya Özdemir, Mehmet Bülent Özdemir

O19 - Evaluation of the relationship between coccyx mobility and prolapse in anterior, middle, and posterior compartments in women with pelvic organ prolapse

Nureda Nalcaci Bozkurt, Tugrul Ormeci, Neslihan Yuzbasioglu

15:00-15:30 INVITED SPEAKER (HALL A)

Moderator: Prof. Dr. İsmihan İlknur UYSAL

I6 - 3D printing systems in anatomy education

Pınar Yılgör Huri

15:30-16:30/ ORAL PRESENTATIONS 3 (HALL A)

Moderators: Prof. Dr. Muzaffer SİNDEL, Prof. Dr. Çađatay BARUT

O106 - Morphometric examination of the relationship between spina ossis sphenoidalis and anatomical landmarks at the skull base

Eda Duygu İpek, Berrin Özüstün, Ilgaz Akdođan

O62 - Examination of cochlea dimensions in children with hearing loss aged 0-18 years: A 3D reconstruction study of cochlea

Saliha Seda Adanir, Mohammad Al Saadi, İlhan Bahşı, Piraye Kervanciođlu, Vedat Topsakal

O7 - The evaluation of arterial and venous variations that can be observed in thorax computed tomography examinations - Preliminary study

Mine Işık Tanış, İsmail Nadir Gülekon, Şilan Işık

O78 - Radiologic identification and clinical significance of gastroduodenal artery origin; preliminary study

Buket Oğuz, Sezer Nil Yılmaz Zorlu, Aleyna Öner, Emre Can Çelebioğlu, Selma Çalışkan

O66 - Does sphenoidal sinus pneumatization influences adjacent structures?

Ayfer Metin Tellioglu, Umut Şener, Işık Tuncer, Yasemin Durum Polat

O18 - Age and gender prediction with sinus sphenoidalis measurements

Aybegum Fazlioglu, Burak Bilecenoglu, TugrulOrmeçi, Alper Atasever

15:30-16:30/ ORAL PRESENTATIONS 3 (HALL B)

Moderators: Prof. Dr. Ayhan CÖMERT, Assoc. Prof. Dr. Ayşegül FIRAT

O94 - Anatomical variations of the petrosphenoidal ligament: a systematic review

Burak Oğuzhan Karapınar, Aymen Ahmed Warille, Orhan Baş, Mehmet Emirzeoğlu

O84 - Safe zone for great auricular nerve block

Bahar Selenay Bulut, Mehmet Yılmaz, Aysun Uz, Ali Fırat Esmer

O118 - Development of temporal muscle in fetal period

Gizem Çizmeci, Mehmet Ali Malas, Selen Akyol Bahçeci

O3 - Clinical approach to neurovascular structures in the preauricular region

Emre Kaygın, Aslı Aktan İkiz

O43 - Investigation of the anatomical properties of the superior transverse ligament (Whitnall's ligament) and its topographic relationship with neighboring structures on 100 orbits: cadaveric study

Gkionoul Nteli Chatzioglou, Özcan Gayretli, Kemal Turgay Özbilen, Vildan Onal, Ayşin Kale

O48 - Evaluation of the association of the phrenic nerve with anatomical structures in the superior thoracic aperture and the importance of these relations in terms of clinical procedures: A cadaveric study

Nilay Yıldız, Gkionoul Nteli Chatzioglou, Osman Coskun, Aysin Kale, Ozcan Gayretli

15:00-15:30 INVITED SPEAKER (HALL A)

Moderator: Prof. Dr. Deniz DEMİRYÜREK, Prof. Dr. Ayla KÜRKÇÜOĞLU

I7 - Facial anatomy in terms of aesthetic applications

Selçuk Tunalı

17:20-18:20/ ORAL PRESENTATIONS 4 (HALL A)

Moderators: Prof. Dr. Zeliha KURTOĞLU OLGUNUS, Assist. Prof. Dr. Kerem ATALAR

O77 - Investigation of Basis Cranii Interna Morphology in Anencephalic and Normal Fetuses

Mustafa Umut Çağlar, Kübra Erten, Derya Çağlar, Ali Faruk Özyaşar

O75 - Could the biomechanical characteristics of the crural fascia in the anterior compartment be related to the levels of anterior leg pain occur in athletes?

İnci Kesilmiş, Zeliha Kurtođlu Olgunus

O26 - Anatomical features of the point which the superficial peroneal nerve pierces the crural fascia

Kıvanç Goral, Elif Cansu İbiş

O138 - Pronator quadratus musculo-osseous free flap for wide hard palatal defect reconstruction: An anatomical study

Murat Igde, Necati Salman, Yigit Gungor, Mehmet Yılmaz, Ela Comert, Murat Enes Saglam, Yiđit Baykara, Ayhan Comert

O146 - The vascular supply of the lateral compartment of the leg with emphasis on fibular graft harvesting

Nihal Apaydin, Aybegum Balci, Marios Loukas, Richard S. Tubbs, Simel Kendir

O166 - A new free functional split gracilis flap design for natural smile reanimation in patients with total facial paralysis: a cadaveric study

Murat Enes Saglam, Murat Igde, Mehmet Yılmaz, Mehmet Aydin, Necati Salman, R. Shane Tubbs, Ayhan Comert

17:20-18:20/ ORAL PRESENTATIONS 4 (HALL B)

Moderators: Prof. Dr. Burak BİLECENOĐLU, Dr. Hasan Barış ILGAZ

O147 - A rare anomaly noticed during coronary angiography intervention: Coiled common iliac artery

Ersin Dođanözü, Pınar Demir Gündođmuş, Burcu Erçakmak Güneş

O130 - A situs inversus totalis case and an anatomical review of the situs anomalies

Çađatay Erşan, Ali Enes Aldur, Zeynep Yılmaz, Ayşegül Fırat

O183 - 3D reconstruction of kidneys in cadaver fetus

Şenol Pişkin, Özlem Elvan, Kaan Esen, Deniz Uzmansel, Samir Donmazov

O175 - Morphological features of carotid body in children: a computed tomography angiography study

Zeynep Yılmaz, Dilek Yıldırım, Ayşegül Fırat, Rahşan Göçmen

O45 - Evaluation of maxillary sinus volume in three-dimensional digital models obtained from multidetector computed tomography images

Mustafa Tekeli, Huseyin Erdem, Yigit Cevik, Nazire Safak Kılıc, Omer Kaya, Neslihan Boyan, Ozkan Oguz

O20 - Morphometric analysis of infraorbital canal in the dog

Nimet Turgut, Sadullah Bahar, Yađmur Güleç

Friday, October 13, 2023

09:00-09:30 INVITED SPEAKER (HALL A)

Moderator: Prof. Dr. Mustafa ALDUR, Prof. Dr. Bünyamin ŞAHİN

18 - Anatomical MRI modalities: Principles, techniques, and diagnostic evaluations

Mehmet Bilgen

09:30-10:40/ ORAL PRESENTATIONS 5 (HALL A)

Moderators: Prof. Dr. Bayram Ufuk ŞAKUL, Assoc. Prof. Dr. Alper VATANSEVER

O29 - Evaluation of the relationship of patients' body mass index with pelvis anatomy, prostate morphology and postoperative continence data

Elif Sena Ozcan, Burak Karakus, Rahim Horuz

O98 - Correlation of craniovertebral junction morphological values in the Anatolian population

Asrın Nalbant, Özden Bedre Duygu, Halide Temelci, Zülal Öner, Serkan Öner

O14 - Evaluation of associated inner ear anomalies in pediatric cases of congenital atresia of the external auditory canal

Ayşe Keven, Serra Ozturk, Merve Sarikaya Dogan, Ekin Tuna Sahin, Basak OguzYolcular, Asli Bostanci Toptas, Muzaffer Sindel, Murat Turhan

O46 - Anatomy and variations of the bronchial artery: Multislice computed tomographic angiography study

Garip Kılıç, Serra Öztürk, Ayşe Keven, Muzaffer Sindel

O126 - Investigating the effects of trigeminal impression and internal acoustic opening morphology differences for possible surgical applications

Ayhan Comert, Ihsan Dogan, Niyem Pelin Cavdar Yilmaz, Yigit Gungor

O124 - Anatomical relationship of crista intersesamoidalis with first metatarsal axis and distal metatarsal joint angle in hallux valgus foot deformity

Ismail Türkten, Semih Ayanoğlu

09:30-10:40/ ORAL PRESENTATIONS 5 (HALL B)

Moderators: Prof. Dr. Halil İbrahim AÇAR, Assist. Prof. Dr. Ali Faruk ÖZYAŞAR

O13 - Investigation of hemispheric asymmetry in Alzheimer patients with the fNIRS method in the resting state

Hazel Gul Mizrak, Merve Dikmen, Lutfu Hanoglu, Bayram Ufuk Sakul

O170 - 3D printed anatomical models as pre-catheterization training material in interventional radiology

Vahide Tutuk, Emre Can Çelebioğlu, Selma Çalışkan

O35 - Comparative Assessment of GPT 3.5, Google Bard and Bing Responses to Different Types of Anatomy Questions

Abdullah Ortadeveci, Hilmi Özden

O50 - Investigation of cranioplasty performed with a 3D printed molded implant and its cosmetic effects: Case report

Yılmaz Yıldırım, Hakan Çakın, Umut Özsoy

O86 - Age estimation by using machine learning algorithms with parameters obtained from x-ray images of the calcaneus

Rukiye Çiftçi, Yusuf Seçgin, Zülal Öner, Şeyma Toy, Serkan Öner

O34 - Gender estimation by using machine learning algorithms with parameters obtained from direct pelvic radiographs

Şeyma Toy, Rukiye Ciftci, Yusuf Secgin, Zulal Oner, Serkan Oner

O73 - The major arterial supply of the musculus temporalis: a cadaveric study

Necati Salman, Simel Kendir, Mehmet Yılmaz, Murat İğde, Süleyman Tuna Karahan, Aysun Uz

11:00-11:30 INVITED SPEAKER (HALL A)

Moderator: Prof. Dr. Samet KAPAKİN

I9 - Traces of life reflected in the bones: The example of the Iznik Byzantine community

Yılmaz Selim Erdal

11:30-12:30/ ORAL PRESENTATIONS 6 (HALL A)

Moderators: Prof. Dr. Nihal APAYDIN, Prof. Dr. Mustafa ORHAN

O92 - Examination of hippocampus volume in brain magnetic resonance images by age and gender using volbrain

Kemal Emre Özen, Özge Coşkun, Cansu Kibar, Hatice Yenigül, Hassan Bagheri, Turgay Şahin, Gülhan Ertan Akan, Kadir Bozdoğan, Niyazi Acer

O55 - Morphometric evaluation of corpus callosum by using magnetic resonance imaging in patients with amyotrophic lateral sclerosis

Zeynep Şengün, Alev Bobuş Örs, Şükrü Hakan Kaleağası, Anıl Özgür

O107 - Evaluation of cerebellum lobule volumes using magnetic resonance imaging in patients followed by the diagnosis of schizophrenia

Vahide Tutuk, Çiçek Hocoaoğlu, Özdemir Sevinç

O112 - Comparison of different radiology-based measurement programs in cerebellar volume analysis of individuals with Alzheimer's disease

Muhammed Emre Yüzer, Büşra Zencirci, Zümrüt Doğan

O23 - Evaluation of the changes between the subcortical nuclei distances in patients after cardiopulmonary resuscitation by conventional magnetic resonance imaging

Hilal Melis Altıntaş, Gülhan Ertan Akan, Özge Arıcı Düz, Berin Tuğtağ Demir, Bayram Ufuk Şakul

O135 - Is there a brain asymmetry difference in unilateral temporal lobe epilepsy patients?

Edibe Bilişli Kara, Zeynep Fırat, Aziz Uluğ, Gazanfer Ekinci, Ümit Süleyman Şehirli

11:30-12:30/ ORAL PRESENTATIONS 6 (HALL B)

Moderators: Prof. Dr. Can PELİN, Assoc. Prof. Dr. Burcu ERÇAKMAK GÜNEŞ

O157 - The relationship between cortical thickness and facial recognition performance in Parkinson's Disease

Necati Emre Şahin, Bünyamin Şahin, Zülal Öner, Gülhan Ertan Akan

O168 - Evaluation of basal nuclei volumes in Multiple Sclerosis patients; preliminary report presentation

Fatma Nur Türkoğlu, Nadire Ünver Doğan, Şerefnur Öztürk, Zeliha Fazlıoğulları, Mustafa Koplay, Ahmet Kağan Karabulut

O176- Volumetric analysis of subcortical structures in obese individuals In Turkish population with MRIcloud method

Beyza Nur Urul, Tuğrul Örmeci, Alper Atasaver

O132 - Morphology and typing of the auriculotemporal nerve

Gülden Kayan, Deniz Uzansel, Turan Koç, Ali Türker Çiftçi, Nail Can Öztürk

O68 - Three-dimensional analysis of the difference in asymmetry between the feet of patients with cerebrovascular events and healthy individuals

Mehmet Karagülle, Yılmaz Yıldırım, Hatice İkizler May, Umut Özsoy, Lütfiye Bikem Süzen

O114 - Am I a fraud? Evaluation of the prevalence of Imposter phenomenon among students receiving postgraduate education in the field of Anatomy in Turkey

Fatma Ok, Mehmet Yiğit, Ayşin Çetiner Kale, Özcan Gayretli, Osman Coşkun

13:30-14:00 INVITED SPEAKER (HALL A)

Moderator: Prof. Dr. Mustafa BERKER, Prof. Dr. İlkan TATAR

I10 - New horizons in surgical neuroanatomy with 3D modeling, virtual/augmented reality and artificial intelligence

Şahin Hanalioğlu

14:00-15:00/ ORAL PRESENTATIONS 7 (HALL A)

Moderators: Prof. Dr. Hakan ÖZTÜRK, Assoc. Prof. Dr. Ceren GÜNENÇ BEŞER

O2 - Author and illustrator of first Turkish dissection atlas: Contributions of İlhami Güneral (1914-2006) to anatomy

İlke Ali Gürses

O8 - Finding the most effective method in anatomy lessons in medical education: A comparison of lectures and online lessons with flipped classroom

Ümran Gözde Çeliker, Serra Öztürk, Mustafa Kemal Alimoğlu, Levent Sarıkcıoğlu, Erol Gürpınar, Muzaffer Sindel

O111 - A different perspective on anatomy education: modelling and virtual reality

Eda Sağıroğlu, Aya Aldashash

O93 - 'Neurocranium bones' in Miftah-ı Teşrih: Up-to-date explanation of anatomical terms

Mine Farımaz, M. Mustafa Aldur

O155 - A rare case: persistent primitive olfactory artery

Ersel Ziyilan, Rukiye Öncel, Yeşim Eroğlu, Hasan Barış Ilgaz

O1 - Using *sous vide* method for warm water maceration and cleaning of bone specimens from fresh and embalmed human cadavers

Ahmet Ertaş, İlke Ali Gürses

14:00-15:00/ ORAL PRESENTATIONS 7 (HALL B)

Moderators: Prof. Dr. Lütfiye Bikem SÜZEN, Assoc. Prof. Dr. Selma ÇALIŞKAN

O33 - Evaluation of the branching angles of the tracheobronchial tree and the lung volume with the three-dimensional reconstruction method

Ayşe Erkaya, Zafer Kutay Coşkun, Seda Akyol, Tuncay Veysel Peker, Tayfun Kuçlu, Fatma Nur Baran Aksakal, Aslı Beyza Tütüncü

O79 - Morphological Differences of Nasal Turbinates in Pulmonary Transplant Candidate Patients: A Radiological Study

Ekin Kartal, Eda Tezgör Aksakal, Sinem Akkaşoğlu, Hüseyin Çetin

O179 - Analysis of idh-1 genotype in glioblastomas: A radiomics study

Aslı Beril Karakaş, Figen Gökmen, Mehmet Asım Özer, Hüseyin Biçeroğlu, Cenk Eraslan, Deniz Tanır

O44 - Determination of the prevalence of retro transverse and arcuate foramen of the Atlas with three-dimensional computed tomography images: a preliminary study

Kaan Çimen

O54 - Evaluation of nasolacrimal duct morphometry in the Turkish population

Kadriye Betül Pence, Nureda Nalcaci, Bahar Tekin, Selva Sen, Gamze Ansen, Tugrul Ormeci, Neslihan Yuzbasioglu

O30 - Anthropometric measurements of the nasal angles and ideal nasolabial angle perception

Niyem Pelin Cavdar Yılmaz, İbrahim Tekdemir, Ceren Bay, İrem Nur Yılmaz, Fatma Nur Ok, Aslı Ateş, Orhun Kelsaka, Ebubekir Demirtaş

15:00-15:30 INVITED SPEAKERS (HALL A)

Moderator: Prof. Dr. Davut ÖZBAĞ, Prof. Dr. Deniz UZMANSEL

I11 – To be an anatomist surgeon

Ali Konan

I12 - Synchronous esophageal and voice reconstruction with free ileocolon flap

Gökhan Sert

17:10-18:10/ ORAL PRESENTATIONS 8 (HALL A)

Moderators: Prof. Dr. Yasin ARİFOĞLU, Assoc. Prof. Dr. Zümrüt DOĞAN

O80 - Prevalence of Haglund deformity in Turkish population

Esin Özşahin, Mahmut Tunç, Sema Polat, Zafer Altun, Pınar Göker

O59 - Morphometric evaluation of the intertubercular sulcus

Cem Erçalık, Elif Cansu İbiş, Ercan Tanyeli, Ali İhsan Soyluoğlu, Ahmet Ertaş

O96 - Morphometric evaluation of mitral valve apparatus and its clinical relations

Buse Naz Çandır, Çağla Ergin, Kader Yılar, Osman Coşkun, Erdoğan Kara, Ayşin Kale, Nilgün Bozbuğa, Adnan Öztürk, Özcan Gayretli

O99 - Evaluation of the relationship between mylohyoid ridge and mandibular morphometry

Selva Şen, Melike Nur Girit, Gamze Ansen, Kadriye Betül Pençe, Neslihan Yüzbaşıoğlu

O51 - Evaluation of the relationship between static plantar pressure and gait biomechanical parameters in healthy adults

Merve İzci, Bihter Akinoglu, Hayri Baran Yosmaoglu, Caner Incekas, Can Pelin

O6 - Relationship of the distal end of the femur with sex and side in the Turkish population

Zennure Adıgüzel Şahin, Ayşe Derya Ertem, Elif Cansu İbiş

17:10-18:10/ ORAL PRESENTATIONS 8 (HALL B)

Moderators: Prof. Dr. Eray TÜCCAR, Assoc. Prof. Dr. Barış Özgür DÖNMEZ

O37 - Evaluation of anatomy according to pelvic floor dysfunction types in magnetic resonance defecography

Melike Taşci, Nadire Ünver Doğan, Emine Uysal, Ahmet Kağan Karabulut, Hüsnü Alptekin, Zeliha Fazlıoğulları

O105 - Investigation of the relationships between craniofacial asymmetries and trunk asymmetries

Begümhan Turhan, Fatma Nur Alçın, Hilal Doğan, Nilufer Çetişli-Korkmaz

O144 - Morphometric study of fibular notch

Damla Şahin, Ebru Yolaçan, Necdet Kocabıyık

O123 - Investigation of temporal fossa morphometry in dry skull bones

Mehmet Ali Malas, Hatice Kübra Yeşil Aksoy

O177 - The geometric morphometric and morphometric analysis of distal humerus

Beyza Nur Caymaz, Kübra Erdoğan

O104 - Topographic and morphometric anatomy of the distal part of the dorsal scapular nerve

Beyza Çelikkün, Özcan Gayretli, İlke Ali Gürses, Osman Coşkun, Adnan Öztürk, Ayşin Kale

LIST OF POSTERS

P5 - A variation of the lateral circumflex femoral artery

Elif Cansu İbiş, Ercan Tanyeli, Mehmet Üzel, Ali İhsan Soyloğlu

P9 - Is there a difference between anatomy and gynecology textbooks in terms of female external genitalia?

Gönül Kotil Aslan, Çağatay Barut

P12 - Comparative evaluation of thickness, surface area, and volume data obtained by freesurfer and brainsuite in brain segmentation and parcellation

Bünyamin Şahin, Yasemin Ekiz, Necati Emre Şahin, Gülhan Akan

P16 - Evaluation of posterior cranial fossa anatomy in migraine patients

Ebru Otu, Tugrul Ormeci, Neslihan Yuzbasioglu

P17 - How effective are acromion types and acromial morphometrics in musculus supraspinatus tear?

Semih Burak Sozcu, Tugrul Ormeci, Neslihan Yuzbasioglu

P21 - Condition of musculus rectus abdominis in patients with Covid-19

Dilek Aydemir, İlyas Uçar, Muhammet Değermenci, Muharrem Said Coşgun

P22 - Anatomy in the light of state archives documents

Yunus Emre Kundakcı

P25 - Neuroplasticity; the brain's lifelong power of change

Figen Koç Direk, Sibel Ateşoğlu Karabaş

P28 - Bibliometric analysis of the one hundred most cited articles during the first hundred years of our republic

Hanife Ertürk, Kenan Öztürk, İhsan Hız, Yadiğar Kastamoni

P38 - Investigation of the protective effect of lavandula stoechas against the damage caused by bisphenol a in the liver tissue of rats

Merve Aydın, Evren Köse, Elif Taşlıdere, Kevser Tanbek, Süleyman Sandal

P39 - Radiological evaluation of the relationship of meniscocapsular thickness with anterior cruciate ligament and its clinical significance

Simge Kökcan, Burak Bilecenoğlu

P40 - Morphometric examination of flexor pollicis brevis in human fetuses

Saliha Seda Adanır, Mehmet Koçbay, Orhan Beger, İlhan Bahşi, Mustafa Orhan, Piraye Kervancıoğlu

P41 - Anatomical variations of inferior phrenic arteries: insights from computed tomography angiography

Serra Ozturk, Ayse Keven, Ekin Tuna Sahin, Basak Oguz Yolcular, Muzaffer Sindel

P42 - Evaluation of pain with VAS scale in university students with and without smartphone addiction

Selma Solgun Dağ, Davut Özbağ

P52 - Analysis of the thigh aesthetic profiles: one of physical ideal body proportions

Gkionoul Nteli Chatzioglou, Figen Gövsa, Gökhan Gökmen

P53 - Computer-aided analysis of the ideal umbilicus

Figen Gövsa, Gkionoul Nteli Chatzioglou, Gökhan Gökmen

P56 - Total injury of the flexor tendons, which is not noticed due to a small incision the finger, surgery and rehabilitation process: a rare case

Sevda Canbay Durmaz, Ali Canbay

P58 - Comparison of the outcomes of online and face-to-face education in anatomy courses

Elif Sena Ozcan, Inci Oktay, Hulya Erbagci

P61 - Three-Dimensional (3D) printing technology in anatomy

F. Fatih Kesmezacar, Özge Çoşkun, Duygu Tunçman, Cem Kopuz

P63 - Anatomical formation and clinical importance of facial lines

Furkan Mehmet Özden, Serpil Çilingiroğlu Anlı, Ayla Kürkcüoğlu

P65 - Clinical significance of crista galli anatomy, types and morphometric features

Meltem Çelik, Kadirhan Doğan, Derya Öztürk Süylemez, Hatice Güler, Mehtap Nisari

P74 - Case report: High originated deep brachial artery accompanying the brachial plexus variation

İbrahim Kaan Özer, Erencan Begiç, Turan Koç, Zeliha Kurtoğlu Olgunus

P76 - Morphometric description for an unnamed anterior compartment fat pad located subfascially in the mid-lower leg

İnci Kesilmiş, Zeliha Kurtoğlu Olgunus

P83 - Anterior and posterior tibial recurrent artery exit patterns and pathways

Mehmet Yilmaz, Ali Firat Esmer

P89 - The relationship between leg length and performance tests of amateur athletes aged 15-18

Nisanur Atlı, Fatih Atlı, Ayla Kürkcüoğlu

P100 - Evaluation of the course and morphologic features of the mandibular incisive canal and mental foramen in the Turkish population

Neslihan Yuzbasioglu, Selva Sen, H. Emir Yuzbasioglu, B. Ufuk Sakul

P102 - Compatibility of anatomical images generated by artificial intelligence with real images

Mert Nahir, Bünyamin Şahin

P103 - Term definition study (Turkish and Latin) for the hand area of the cardiac massage practitioner in contact with the patient's chest

Ismihan İlknur Uysal, Abdullah Taha Talan, Ummuhan Yagmurkaya

P108 - Do anatomists neglect the middle hepatic artery?

Tuğçe Taşkindere Abbasoğlu, Ayşegül Fırat

P109 - Examination of brain volumes of individuals who applied to the hospital with complaints of headache or dizziness

Nuriye Öz, Kamil Karaali, Nigar Keleş-Çelik

P117 - Evaluation of reliability and quality of YouTube videos about larynx anatomy

Songul Cuglan

P122 - Demonstration of the therapeutic effect and mechanism of action of basil (ocimum gratissimum) in acute (acetyl salicylic acid) and chronic (stz-streptozocin) experimental tinnitus models created experimentally in rats with its anti-glutamnergic effect and monitoring of tinnitus in rats with EEG.

Mehmet Bülent Özdemir, Ahmet Kutluhan, Semin Fenkçi, Gülçin Abban Mete

P127 - Do the morphological characteristics of the canalis carpi during the embryological period differ according to gender and hand side?

Mehtap Kondak, Nevnihal Akbayturk, Mehmet Haluk Uluutku

P129 - Evaluation of arteria mesenterica inferior and its branching pattern by magnetic resonance angiography

Necmi Keskin, Belgin Bamac, Ozgur Cakir, Tuncay Colak, Abdullah Ors, Cagatay Barut

P136 - Association of Klippel-Feil syndrome and Duane syndrome: Case report

Sevdenur Bekam, Burak Karip, Sevim Yener, Nurullah Yucel

P137 - The effect of pes equinovarus on the myotonometer characteristics of leg surface muscles, calcaneal tendon, and plantar fascia: A preliminary study

Rabia Taşdemir, Rukiye Çiftçi, Nevzat Gönder, Ömer Faruk Cihan, Zeynep Şencan, Cansu Öztürk, Ebru Sena Çalışır

P139 - Retrospective evaluation of age, gender and side differences of acromial index using three-dimensional reconstruction method

Gülnur Diner, Ender Uzabacı, Gökhan Gökalp, Senem Turan Özdemir

P140 - Frequency of nonmetric variations in late Byzantine period (13th century AC) atlases

Gizem Çetin, Nilgün Tuncel-Çini, Gülnur Diner, Senem Turan Özdemir

P145 - Bibliometric analysis of doctoral theses in the field of anatomy

Gülay Madan

P148 - Evaluation of distance and formal anatomy education in vocational school of health services students

Özge Coşkun, Özgü Kesmezacar, Fatih Kesmezacar

P149 - Subarachnoid cisterns: Is there a difference between anatomical and clinical descriptions?

Gizem Serpil Balyemez, Çağatay Barut

P150 - Round ligament varices as a cause of inguinal swelling during pregnancy

Gamze Uyanık Yılmaz, Bilge İpek Torun, Mehtap Balaban

P151 - Auricular types in normal and anomalous fetuses

Evrin Güneş, Özlem Elvan, Alev Örs

P152 - Absence of the right coronary artery: a rare coronary artery anomaly

Yusuf Güler, Yeşim Eroğlu, Pınar Demir Gündoğmuş

P153 - Lumbar spine visualization: an algorithmic approach to 3D printing for training and surgical planning

Aya Aldashash, Eda Sađırođlu, Fatema Shaaban

P154 - Digitalization of bone materials with 3D mobile scanning program and adaptation to anatomy education

Zehra elik, Mehmet lkir, Hasan Barıř Ilgaz

P158 - Does the radial groove really exist?

Nimet Ebrar Demircan, Mislina Utlu, Mehmet Ali Gner, Necdet Kocabıyk

P159 - The effect of using a smartphone on walking and balance

Metehan Pehlivan, Blent Sabri Cıđalı

P160 - Morphometric features of the lateral plate of pterygoid process: A clinical correlation study

mmhan Yađmurkaya, Dilara Patat, Berin Tuđtađ Demir, Mehtap Nisari, Burak Bilecenođlu

P161 - Morphometric evaluation of sagittal curvature in dry tibia bones

Merve Kker, Nazlı Ateř, Mehmet Ali Malas

P162 - The parameters of Turkish population's tibial plateau

Didem Dnmez Aydın, Seher Mehmed, Sıdıka Akran, İlayda řafak, Ođuz Tařkınalp

P167 - Morphological investigation of the importance of incisive foramen in maxillary surgery

Hilal Melis Altıntař, Simge Eřme, Berin Tuđtađ Demir, Mehtap Nisari, Burak Bilecenođlu

P169 - Coexistence of Seckel syndrome and neurogenic bladder: Case report.

Elif Sena Ozcan, Sevim Yener, Metin Esen, Nurullah Yucel

P171 - Bibliometric analysis of anatomy doctoral theses in Turkiye

Bedrettin inpolat, Meltem Aar Gdek

P172 - Anatomical structures in the rare genetic disease Wolfram syndrome: A case report

Rabia Solak Dner, Sevim Yener, Papatya Keleř, Nurullah Ycel

P173 - Evaluation of foramen lacerum morphometry on brain computed tomography images with 3D slicer method

Merve Muslu, mr Karaca

P174 - The relationship between the infraorbital nerve and the periorbita

Elif elik, Necati Salman, Simel Kendir, Nihal Apaydın, S. Tuna Karahan

P184 - The contribution of 3D tibia modeling to anatomy education: How successful is it?

Aslı Beril Karakař, Figen Gkmen, Mehmet Asım zer

P186 - Bardet-Biedl syndrome: Case report

Cansu Kibar, Ozge Coskun, Sevim Yener, Papatya Keles, Nurullah Yucel

P187 - Anatomy and functional effects of the human microbiota; an examination related to the vagus nerve

Hseyin Gzey, Rukiye ncel, Zehra elik, M. Mustafa Aldur

P190 - The importance of the anatomical neighborhoods of the cervix and upper vagina to avoid colpotomy complications due to the increased V-NOTES surgery: a case report

Ali Can Gunes, Burcu Ercakmak Gunes

P191 - Examination of distal femur morphometry in various parameters

Hilal Kiran

P192 - Endoscopic transorbital approach to the skull base: Anatomical landmarks and clinical applications

Hilal Akdemir Aktaş

P193 - Anatomical landmarks for craniomaxillofacial deformities and cleft lip and palate

Ceren Güneç Beşer

I1 - Anatomy on the 100th Anniversary of the Republic of TürkiyeDoğan Akşit¹¹Department of Anatomy, Faculty of Medicine, Hacettepe University, Ankara, Türkiye**I2 - Anatomy and bureaucracy**Muzaffer Şeker^{1,2}¹Head of Turkish Academy of Sciences²Department of Anatomy, Faculty of Medicine, Necmettin Erbakan University, Konya, Türkiye**I3 - Anatomy knowledge in hand surgery**Gürsel Leblebicioğlu¹¹Department of Orthopedics and Traumatology, Faculty of Medicine, Hacettepe University, Ankara, Türkiye**I4 - Anatomy, magnetic resonance and diffusion tensor imaging of the human brainstem**Gülgün Şengül¹¹Department of Anatomy, Faculty of Medicine, Ege University, İzmir, Türkiye**I5 - A glimpse of anatomy from radiology**Adalet Elçin Yıldız¹¹Department of Radiology, Faculty of Medicine, Hacettepe University, Ankara, Türkiye**I6 - 3D printing systems in anatomy education**Pınar Yılgör Huri¹¹Department of Biomedical Engineering, Faculty of Engineering, Ankara University, Ankara, Türkiye**I7 - Facial anatomy in terms of aesthetic applications**Selçuk Tunalı¹¹Department of Anatomy, Faculty of Medicine, University of Economics & Technology (TOBB ETU), Ankara, Türkiye**I8 - Anatomical MRI modalities: Principles, techniques, and diagnostic evaluations**Mehmet Bilgen¹¹Department of Biophysics, Faculty of Medicine, Adnan Menderes University, Aydın, Türkiye**I9 - Traces of life reflected in the bones: The example of the Iznik Byzantine community**Yılmaz Selim Erdal¹¹Department of Anthropology, Faculty of Letters, Hacettepe University, Ankara, Türkiye**I10 - New horizons in surgical neuroanatomy with 3D modeling, virtual/augmented reality and artificial intelligence**Şahin Hanalioğlu¹¹Department of Neurosurgery, Faculty of Medicine, Hacettepe University, Ankara, Türkiye**I11 - To be an anatomist surgeon**Ali Konan¹¹Department of General Surgery, Faculty of Medicine, Hacettepe University, Ankara, Türkiye**I12 - Synchronous esophageal and voice reconstruction with free ileocolon flap**Gökhan Sert¹¹Department of Plastic Reconstructive and Aesthetic Surgery, Faculty of Medicine, Hacettepe University, Ankara, Türkiye

O1 - Using *sous vide* method for warm water maceration and cleaning of bone specimens from fresh and embalmed human cadavers

Ahmet Ertaş¹, İlke Ali Gürses²

¹Department of Anatomy, Cerrahpasa Faculty of Medicine, Istanbul University-Cerrahpasa, Istanbul, Türkiye

²Department of Anatomy, School of Medicine, Koç University, Istanbul, Türkiye

Objectives: *Sous vide* is a cooking technique which improves heat flow and allows cooking in vacuum plastic pouches at controlled temperatures. This feature renders this method as an alternative maceration method. This study presents utilization of *sous vide* for chemical maceration and cleaning of fresh and embalmed human specimens.

Methods: Three head and neck and upper extremity, and four lower extremity and pelvis specimens from 5 fresh and 2 embalmed cadavers at the Department of Anatomy of the Koç University School of Medicine were used. Following soft tissue removal, specimens in plastic pouches filled with water and detergent solution were vacuum packaged. Maceration was done with a commercial device at 65 °C for three to four days. Between sessions, remaining soft tissue was removed with blunt instruments. Following maceration, additional degreasing was done with concentrated acetone solution.

Results: Three sets of crania, cervical vertebrae, upper extremity bones, and four sets of lower extremity skeletons with pelvises were prepared. The method successfully cleaned embalmed and fresh specimens. Small embalmed bones (vertebrae, carpals etc.) and large fresh bones (femora, humeri etc.) were adequately macerated in three sessions. Crania and large embalmed bones usually required an additional session. Degreasing in acetone baths lasted from three to seven days.

Conclusions: Using *sous vide* for chemical maceration might be a cheaper and effective alternative for preparation of human skeletal specimens from both fresh and embalmed cadavers. Further studies are planned for quantifying the soft tissue removal and degreasing capacity of *sous vide* method.

Keywords: bone cleaning, cadaver, detergent, embalmed cadaver, fresh cadaver, maceration, *sous vide*

O2 - Author and illustrator of first Turkish dissection atlas: Contributions of İlhami Güneral (1914-2006) to anatomy

İlke Ali Gürses¹

¹Department of Anatomy, School of Medicine, Koç University, Istanbul, Türkiye

Objective: İlhami Güneral was a Turkish physician and surgeon who contributed to anatomy education, and possibly medical illustration, in Türkiye which was not reported before. This study aims to outline his achievements throughout his career and acknowledge his contributions to anatomical sciences in Türkiye.

Methods: A series of interviews were conducted with his surviving family, relatives, and friends with additional collected documents.

Results: İlhami Güneral was born in 1914 in Anadolu Kavağı, İstanbul. He attended İstanbul University Faculty of Medicine and graduated in 1942. Upon graduation, he published his first book titled "Dissection Atlas" which he also illustrated himself. His illustrations were later used in the dissection atlas of Prof. Dr. Zeki Zeren published in 1953. Following his mandatory military and medical services, he visited and worked with renowned neuropathologist Philipp Schwartz, his former pathology lecturer from İstanbul University, between 1958 and 1960 in the US. During his stay, he constructed a detachable "Transparent Brain Model" for teaching brain anatomy which was awarded with the Billings Gold Medal at the 109th Annual Meeting of the American Medical Association. After his return to Türkiye, he published his final illustrated anatomy atlas in 1972, the "Atlas Cerebri Humani". He spent the remaining days of his life in his long standing home in Ödemiş, İzmir, as a private physician and surgeon. He was diagnosed with prostate cancer in 1993, and passed away due to his illness in 2006.

Conclusion: It is possible that this interesting and unique dramatis persona is the author and illustrator of the first dissection atlas printed in Turkish.

Keywords: anatomy, anatomy education, dissection, medical illustration

O3 - Clinical approach to neurovascular structures in the preauricular region

Emre Kaygın¹, Aslı Aktan İkiz²

¹Department of Anatomy, Faculty of Medicine, Kocaeli University, Kocaeli, Türkiye

²Department of Anatomy, Faculty of Medicine, Ege University, İzmir, Türkiye

Objective: The aim of this study is to measure the distances of the veins and nerves located in the preauricular region to certain anatomical structures on the face and examine the relationships between these measurements. The goal is to provide guidance to healthcare professionals and researchers in the implementation of treatments based on the results.

Methods: A total of 20 dissection studies were conducted on the right and left preauricular regions. The superficial temporal artery (ATS), superficial temporal vein (VTS), and auriculotemporal nerve (NAT) were dissected in the preauricular region. The point where these structures surfaced from the subcutaneous deep plane (CP) was determined. The distances from the point where the artery surfaced (ACP), the point where the vein surfaced (VCP), and the point where the nerve surfaced (NCP) to the commissura labiorum (CL), commissura palpebralis lateralis (CPL), and tragus (T) were measured. The relationships between these distances were statistically analyzed.

Results: Only the mean distances between right and left VCP - CL were statistically significantly different ($p < 0.05$). Positive strong correlations were found among measurements of distances on the right and left sides: ACP - CL, VCP - CL, and NCP - CL; ACP - CPL, VCP - CPL, and NCP - CPL ($p < 0.05$). There was no statistically significant difference found in the other measurements ($p > 0.05$).

Conclusion: Veins on the face exhibit more variation compared to arteries and nerves, and oral asymmetries are more commonly observed. The relationships between neurovascular structures in the preauricular region and surrounding structures, as supported by previous studies, may contribute to understanding the causes of certain clinical cases.

Keywords: auriculotemporal nerve, preauricular region, superficial temporal artery, superficial temporal vein

O4 - Does medial longitudinal arch morphometrics affect the formation of pes planus or pes cavus in patients with epin calcanei (heel spur)?

Gozde Cingoz¹, Tugrul Ormeci², Neslihan Yuzbasioglu¹

¹Department of Anatomy, School of Medicine, Istanbul Medipol University, Istanbul, Türkiye

²Department of Radiology, Medicana Hospital Ataköy, Istanbul, Türkiye

Objective: Plantar fasciitis can affect the morphometry of the medial longitudinal arch (MLA). Pes cavus and pes planus deformities may occur in individuals due to MLA deterioration. Morphometry of MLA may also be impaired in patients with epin calcanei associated with plantar fasciitis. Therefore, the aim of our study to reveal the anatomical changes in the morphometry of the MLA in the X-ray foot images of epin calcanei patients and to evaluate the predisposition of these patients to pes cavus or pes planus foot deformities.

Methods: Lateral Computed Radiographs (CR) of 200 people were evaluated. These individuals were divided into two groups and examined. The first group was formed by 100 people diagnosed with epin calcanei. The second group was formed by 100 people as control group. The measurements of the calcaneal pitch, lateral Meary, tibiotalar and Hibbs angles associated with pes planus and pes cavus were compared in the radiological images of both groups.

Results: When the values of calcaneal pitch, lateral Meary and Hibbs angles were compared between the patient and control groups, no statistically significant difference was found ($p > 0.05$). When the values of tibiotalar angles were compared between the patient and control groups, a statistically significant difference was found ($p < 0.05$). A strong ($p < 0.01$) and negative correlation was found between calcaneal pitch angle and Hibbs angle.

Conclusion: It is thought that there is a need for new studies in which more people are involved and more parameters will be evaluated in order to reveal clearly the health problems that can be caused by heel spurs.

Keywords: epin calcanei, medial longitudinal arch, pes cavus, pes planus, plantar fasciitis

O6 - Relationship of the distal end of the femur with sex and side in the Turkish population

Zennure Adigüzel Şahin¹, Ayşe Derya Ertem¹, Elif Cansu İbiş¹

¹Department of Anatomy, Cerrahpasa Faculty of Medicine, Istanbul University-Cerrahpasa, Istanbul, Türkiye.

Objective: Total knee prosthesis is a frequently used material in the surgery. Distal femur measurements must be taken into account to use the correct prosthesis. The aim of this study is to determine whether the distal femur differs according to side and / or sex in the Turkish population. Thus, it is planned to guide the Turkish population in choosing the most suitable knee prostheses imported from abroad.

Methods: Using 138 dry bones in the study, at first sides of the femurs were determined and eight parameters from femur distal and proximal parts were measured by a measuring tape and a digital caliper for sex determination. Five parameters were measured at the distal part to evaluate whether these parameters differ according to femur side and sex.

Results: According to the results distal femoral sizes narrower than the female in the male in the Turkish population as well as all over the world. Distal femur measurements do not differ by side. Distal femur measurements of female and male in the Turkish population are wider than distal measurements of Far East and Asian populations. These measurements are more similar to the measurements of the North American population.

Conclusion: In knee prostheses that need to be imported, it is important to purchase prosthesis according to the distal femur dimensions of the Turkish population.

Keywords: Turkish population, distal femur, total knee prosthesis, sex, side.

O7 - The evaluation of arterial and venous variations that can be observed in thorax computed tomography examinations - Preliminary study

Mine Işık Tanış¹, İsmail Nadir Gülekon², Şilan Işık³

¹Türkiye Olympic Preparation Center, Ankara, Türkiye

²Department of Anatomy, Faculty of Medicine, Gazi University, Ankara, Türkiye

³Health Sciences University, Van Education and Research Hospital, Department of Pulmonology, Van, Türkiye

Objective: Vascular variations can be anomalies encountered incidentally through radiological imaging, and they may not present any symptoms throughout one's lifetime. Having a comprehensive understanding of thoracic vascular anatomy and anomalies, along with their precise characterization, is essential for future surgical planning and the prevention of potential complications. This study was conducted to determine the incidence and clinical significance of normal, variable, and abnormal branching patterns of thoracic vascular structures in the general adult population using Computed Tomography (CT) images.

Methods: The study included a total of 300 patients, consisting of 143 males and 157 females, who presented to the Department of Pulmonology at Van Education and Research Hospital for various reasons and underwent Thoracic CT examination. Patients with non-diagnostic quality thoracic CT scans, a history of lung surgery, or severe parenchymal disease were excluded from the study. Patients were examined and recorded in terms of gender, age, vascular variations and anomalies that could be observed in the thoracic imaging area.

Results: Among the 300 patients evaluated in our study, bovine arch anomaly was observed in 49 (16.3%) patients. In 48 (16%) patients, the vena hemiazygos accessoria drained into the left brachiocephalic vein through the left superior intercostal vein. Vena thoracica interna dextra variation draining into the vena cava superior was observed in 6 (2%) patients. Aberrant right subclavian artery anomaly was observed in 5 (1.6%) patients, and azygos vein variation was seen in 6 (2%) patients. In 13 (4.3%) patients, the left vertebral artery originated directly from the aortic arch.

Conclusion: In this study, a multitude of diverse anomalies and variations were encountered. A clear comprehension of thoracic region variations provides preoperative precise information that can facilitate the execution of accurate and safe surgical procedures, reduce the incidence of postoperative complications, and contribute to the enhancement of patients' prognoses.

Keywords: thorax computed tomography, arterial variations, venous variations

O8 - Finding the most effective method in anatomy lessons in medical education: A comparison of lectures and online lessons with flipped classroom

Ümran Gözde Çeliker¹, Serra Öztürk¹, Mustafa Kemal Alimoğlu², Levent Sarıkcıoğlu¹, Erol Gürpınar², Muzaffer Sindel¹

¹Department of Anatomy, Faculty of Medicine, Akdeniz University, Antalya, Türkiye

²Department of Medical Education, Faculty of Medicine, Akdeniz University, Antalya, Türkiye

Objective: As technology continues to advance, various educational models have emerged, and medical education has adapted to these changes. The aim of this study is to compare the effectiveness of flipped classroom in human anatomy education with traditional face-to-face education (lectures) and online education in terms of student satisfaction with all three models.

Methods: The study included 212 second-semester students studying at Akdeniz University Faculty of Medicine during the 2022-2023 academic year. To ensure consistency among the students, the same instructor taught different anatomy subjects using various educational methods. Subsequently, a feedback form, prepared by experts in the field of medical education, was distributed to evaluate student satisfaction, and the results were analyzed statistically.

Results: The mean total scores of student feedback were found 40.9 ± 12.3 for the classical lecture, 39.4 ± 12.7 for the online class, and 44.9 ± 10.8 for the flipped classroom. The difference between these scores was found to be statistically significant (One-Way ANOVA, $p=0.003$).

Conclusion: Advancing with the evolving technological landscape, this study demonstrates the advantages of the flipped classroom approach in comparison to traditional face-to-face lectures and online education within the realm of human anatomy education. The results underscore the enhanced engagement and knowledge acquisition associated with the flipped classroom model, as evidenced by higher student satisfaction and preference. This highlights the potential for more widespread adoption of innovative educational methodologies in the medical field.

Keywords: flipped classroom, online education, medical education, anatomy

O10 - Evaluating noise stress on neuronal activation of rat's central nervous system

Alper Vatansever¹, Duygu Gök Yurtseven², Gonca Topal², Şule Mergen³, İlker Mustafa Kafa¹, Gökhan Göktaş³, Özhan Eyigör²

¹Department of Anatomy, Faculty of Medicine, Bursa Uludağ University, Bursa, Türkiye

²Department of Histology and Embryology, Faculty of Medicine, Bursa Uludağ University, Bursa, Türkiye

³Department of Pharmacology and Toxicology, Faculty of Medicine, Bursa Uludağ University, Bursa, Türkiye

Objective: Noise is the type of stress that people are most exposed to during daily life. Noise, described as nonspecific biologic stress type, could affect negatively to metabolism same as other stress factors. According to World Health Organisation's report, noise is listed as the second most common stress type among other environmental stress factors that affect public health negatively. Aim of this study was to investigate morphological and molecular effects of noise exposure on rat's central nervous system.

Methods: A total number of 12 adult male Wistar rats (6 for control group; 6 noise exposure group) included our study. Handling procedure was applied for a week for all animals. Then, noise group was exposed white noise (85-105 dBA) for 30 minutes. Control group was transferred to the experiment room and stay there for 30 minutes exposed only basal noise (60dBA). After finished the experiment, animals were sacrificed and post-fixation procedures were applied. Serial sections of brains of animals were collected using vibratome. Immunohistochemical staining with anti-*c-fos* antibody according to manufacturer's guide. Ventral cochlear nucleus (VC), medial geniculate body (MGB) and primary auditory cortex (Au1) were evaluated. The neurons that stained positive with anti-*c-fos* antibody were count manually using QuPath software. A total number of positive cells were recorded and compared between groups. After statistical tests were completed, p values that less than 0.05 were accepted as significantly different.

Results: As a result of statistical analysis, statistically significant differences were observed between the experimental and control groups in favor of the experimental group in evaluated regions.

Conclusion: It was observed that exposing high level of noise caused a significant increase of neural activation in auditory pathways. Furthermore, presence of *c-fos* positive neurons in other subcortical areas along with the auditory pathways suggests that noise causes stress with pathways via lower centers.

Keywords: noise stress, hearing, neuroscience, neuroanatomy

O11 - Investigation of distal radius morphometry in adults and evaluation of its compliance with implants applied in distal radius fractures

Pelin İsmailoğlu¹, Alp Bayramoğlu², Güler Kahraman Yıldırım³

¹Department of Physiotherapy and Rehabilitation, Faculty of Health Sciences, Fenerbahçe University, Istanbul, Türkiye

²Department of Anatomy, Faculty of Medicine, Acıbadem University, Istanbul, Türkiye

³Department of Anatomy, Faculty of Medicine, Istanbul University-Cerrahpaşa, Istanbul, Türkiye

Objective: The objective of this study is to analyze the morphometric differences of the volar aspect of the distal radius to make an anatomical contribution to the surgical treatment of distal radius fractures. It is aimed to ensure the anatomical compatibility of volar implants by detailing the morphological individual differences that may occur in the fixation treatment of distal radius fractures with volar implants.

Methods: Morphometric measurements were performed retrospectively on computed tomography images of 103 intact distal radii. Watershed line, width (G), ulnar variance, LFI (Lunate facet Inclination), SFI (Scaphoid Facet Inclination), and IFA (Interfacet Angle) were measured.

Results: A sagittal section was described as passing through the midpoint of the scaphoid facet. 1 cm distal of the radius body to define the watershed line's lateral curvature on average (A1-1) was 144.92 for the women. It was determined as 138.96 for men. For medial curvature the sagittal section passes through the midpoint of the lunate facet and its 1 cm distal measurement was named A2-1. A significant difference was found for the A1-1 and A2-1 angles in terms of gender ($p < 0.05$). For A1-1, $p = 0.000149$; for A2-1, $p = 0.000030$. These angles were wider for women compared to men. The average G value was 26.51 mm, and no significant difference was found for gender, age, or right-left side ($p > 0.05$). The mean ulnar variance was found to be -2.01 ± 2.20 mm, the mean LFI was -0.100 ± 8.410 , the mean SFI was 26.140 ± 6.960 , and the average IFA was 24.240 ± 10.460 .

Conclusion: Individual differences have been determined by morphometric evaluation of the volar aspect of the distal radius and it is concluded that surgical treatment with a distal radius volar implant is important in restoring anatomical consistency. It is recommended to use three-dimensional examination methods in pre-surgical planning for the fixation of distal radius fractures with volar implants.

Keywords: watershed line, ulnar variance, distal radius, volar implants

O13 - Investigation of hemispheric asymmetry in Alzheimer patients with the fNIRS method in the resting state

Hazel Gul Mizrak¹, Merve Dikmen², Lutfu Hanoglu³, Bayram Ufuk Sakul¹

¹Department of Anatomy, School of Medicine, Istanbul Medipol University, Istanbul, Türkiye

²Istanbul Medipol University, Health Sciences and Technologies Research Institute (SABITA), Regenerative and Restorative Medicine Research Center (REMER), Clinical Electrophysiology, Neuroimaging and Neuromodulation Laboratory, Istanbul, Türkiye

³Department of Neurology, School of Medicine, Istanbul Medipol University, Istanbul, Türkiye

Objective: The aim of our study is to compare the decrease in hemispheric asymmetry that occurs with aging in healthy and elderly subjects diagnosed with Alzheimer's Disease (AD) according to the hemodynamic responses of the brain. Thus, we aim to contribute to the use of these differences in the early diagnosis of AD in the clinic and to provide a new perspective on treatment approaches.

Methods: Resting states fNIRS data (in two session: eyes-open and eyes-closed of 20 AD and 20 controls) was analyzed by functional connectivity analysis.

Results: Results with eyes-open and eyes-closed resting state interhemispheric functional connectivity analysis result a significant difference between the two groups in parallel channels between brain regions including primary somatosensory cortex, gyrus supramarginalis and Wernicke's area. In the comparison of the functional connectivity of intrahemispheric adjacent channel pairs within the Alzheimer group for eyes-open resting state, a significant difference was found in the adjacent channels containing the same brain regions ($p < 0,05$). In the comparison of the functional connectivity analyzes of the intrahemispheric adjacent channel pairs between the groups, a significant difference was found between the two groups in the adjacent channel pair containing the premotor cortex ($p < 0,05$).

Conclusion: It was determined that the decrease in hemispheric asymmetry was higher in the control group compared to the Alzheimer group. In addition, interhemispheric and intrahemispheric functional connectivity in the right hemisphere was found higher in the control group. It means that the right hemisphere plays a greater role in the reduction of hemispheric asymmetry. However, the decrease in hemispheric asymmetry was found less in the Alzheimer group compared to the control group. We claim that it may be a cause or a consequence of the pathology.

Keywords: Alzheimer's Disease, fNIRS, hemispheric asymmetry, lateralization, resting state

O14 - Evaluation of associated inner ear anomalies in pediatric cases of congenital atresia of the external auditory canal

Ayşe Keven¹, Serra Oztürk², Merve Sarıkaya Doğan², Ekin Tuna Sahin¹, Basak Oguz Yolcular³, Asli Bostanci Toptas⁴, Muzaffer Sindel², Murat Turhan⁴

¹Department of Radiology, Faculty of Medicine, Akdeniz University, Antalya, Türkiye

²Department of Anatomy, Faculty of Medicine, Akdeniz University, Antalya, Türkiye

³Biostatistics and Medical Informatics specialist, Antalya, Türkiye

⁴Department of Otorhinolaryngology Head and Neck Surgery, Faculty of Medicine, Akdeniz University, Antalya, Türkiye

Objective: In our study, we aimed to evaluate the frequency and types of internal auditory canal anomalies that may accompany external auditory canal (EAC) atresia, stenosis and auricular anomalies in pediatric cases with hearing loss on CT (computed tomography) images.

Methods: 20 patients under the age of 18 with EAC atresia, microtia, auricular anomaly, who underwent temporal CT had both ears evaluated retrospectively. Temporal bone and middle ear cavity pneumatization were graded. Coronal and axial sections were evaluated and the length and diameter of the internal acoustic canal, cochlea length and variations, bone chain pathology in the middle ear, semicircular canal variations, the presence of jugular bulb anomaly were evaluated.

Results: In our patients with atresia or hypoplasia of the EAC, pneumatization of the temporal bone was most common in the infralabyrinth. Pneumatization of the middle ear was found at a high rate in our patients. In our study, the mean length and diameter of the internal auditory canal and the mean length of the cochlea were measured, and no significant difference was found on either side. Incudo-malleolar complex anomaly was detected most frequently, and semicircular canal abnormality was detected at a low rate.

Conclusion: It is crucial to identify any congenital abnormalities that may occur alongside EAC atresia when selecting patients who could potentially benefit from surgical intervention. This study is the first to conduct all of these evaluations in such detail in this specific age group.

Keywords: middle ear anomaly, inner ear anomaly, external auditory canal anomaly, CT, congenital anomaly

O15 - Assessment of gait symmetry and pelvic symmetry in children and adolescents with specific learning disorders and comparison with healthy controls

Yunus Emre Kundakcı¹, Emel Taşvuran Horata¹

¹Department of Physiotherapy and Rehabilitation, Faculty of Health Sciences, Afyonkarahisar Health Sciences University, Afyonkarahisar, Türkiye

Objective: The pelvic skeleton is a complex ring-shaped anatomical structure consisting of the sacrum and coccyx at the back and a pair of innominate bones on the sides. Symmetry is one of the criteria for proper body posture in an upright position. Pelvic asymmetries can occur that alter the anatomy, function or biomechanics of the pelvis, which is considered to be essentially symmetrical. Since the pelvis plays a bridging role between the trunk and lower extremities, its position during walking is clinically important. The aim of this study was to examine and compare the gait symmetry and pelvic symmetry of children with specific learning disorders (SLD) and age-matched healthy controls.

Methods: In this study, the SLD group consisted of 47 children and adolescents and the healthy control group consisted of 51 age-matched participants. All participants underwent a 10-meter walking test, and the BTS G-walk wearable motion analysis system (G-Sensor, BTS Bioengineering S.p.A., Italy) was used to calculate symmetry indices during the test. Group differences were analysed using the Mann-Whitney U test.

Results: There was no significant difference between SLD and the healthy control groups in terms of gait symmetry index and pelvic oblique symmetry index ($p>0.05$). However, there was a significant difference in the pelvic tilt symmetry index and pelvic rotation symmetry index between the two groups ($p=0.008$ and $p=0.002$, respectively).

Conclusion: Children and adolescents with SLD exhibit asymmetric pelvic kinematics during gait compared to healthy controls. Abnormal alignment of pelvic movements during walking may also affect other related structures. It is emphasized that pelvic asymmetry contributes to increased mechanical load during gait. Therefore, future studies may investigate the possible contribution of pelvic asymmetries to pathologies of other pelvis-related structures in children with SLD.

Keywords: specific learning disorder, pelvic asymmetry, pelvic alignment, gait

O18 - Age and gender prediction with sinus sphenoidalis measurements

Aybegum Fazlioglu¹, Burak Bilecenoglu², Tugrul Ormeci³, Alper Atasever¹

¹Department of Anatomy, Faculty of Medicine, Istanbul Medipol University, Istanbul, Türkiye

²Department of Anatomy, Faculty of Medicine, Ankara Medipol University, Ankara, Türkiye

³Department of Radiology, Faculty of Medicine, Istanbul Medipol University, Istanbul, Türkiye

Objective: Determining gender and age are important steps in identification studies. The cranium is very resistant to destruction therefore the cranium is a guiding tool in identification. It has been observed that there is a need to determine the role of sinus sphenoidalis in gender and age estimation in case of damage to other sinuses. The aim of our study is to investigate whether the 6 parameters of the sinus sphenoidalis are a determining structure on gender and age estimation and to determine the correlation between cranium measurements and sinus sphenoidalis parameters.

Methods: This study was conducted retrospectively on computerized tomography images of 80 people (40 men, 40 women) between the ages of 10-85. Measurements of sinus and cranium were made with the Philips IntelliSpace Portal system. Analyzes were made with Statistical Package for Social Sciences 20.0 software. Sinus sphenoidalis anterior wall; horizontal distance with 90 degree perpendicular to processus clinoides posterior and its distance from the dens-axis apex, the anterior-posterior and laterolateral transverse distance of the sinus sphenoidalis walls, the farthest distance from the most inferior of the sinus to the processus clinoides posterior were measured. Head circumference of the cranium, fronto-occipital and biparietal distances were measured.

Results: We found that the longest horizontal distance of the sinus anterior-posterior wall and the fronto-occipital distance were related to age. We concluded that gender is related to the horizontal distance of the sinus anterior wall to the posterior processus clinoides, but no significant difference was found between cranium measurements and gender.

Conclusion: Sinus sphenoidalis, which is located deepest, and its relationship with the surrounding structures are important in the development of the skull base. Parameters of the sinus sphenoidalis are a relatively new and reliable method for determining gender and age.

Keywords: age estimation, forensic anthropology, gender estimation, sinus sphenoidalis, identification

O19 - Evaluation of the relationship between coccyx mobility and prolapse in anterior, middle, and posterior compartments in women with pelvic organ prolapse

Nureda Nalcaci Bozkurt¹, Tugrul Ormeci², Neslihan Yuzbasioglu¹

¹Department of Anatomy, School of Medicine, Istanbul Medipol University, Istanbul, Türkiye

²Department of Radiology, Faculty of Medicine, Istanbul Medipol University, Istanbul, Türkiye

Objective: Pelvic organ prolapse (POP) is a serious disease that decreases the quality of life. In this study, POP was examined in three groups as anterior, middle and posterior compartments. Coccyx mobility were examined in these three compartments and the relationship between coccyx mobility and prolapse is the aim of the investigation.

Methods: In our study, demographic data of 45 women with POP were collected and T2-weighted MR defecography images were included in the study. Each compartment prolapse sagging amounts were determined. Coccyx angle, sacrococcygeal angle and sacrococcygeal joint angles were measured in the four phases of defecation: resting, squeezing, straining and defecation.

Results: Statistically significant differences existed in the angles (coccyx, sacrococcygeal, and sacrococcygeal joint) during defecation phases ($p < 0.05$). The coccyx angle changed by an average of $5,94^\circ$, sacrococcygeal angle by $12,82^\circ$, and sacrococcygeal joint angle by $3,2^\circ$ during defecation. Coccyx length showed a significant connection with sagittal diameter of the pelvic outlet ($p < 0.05$). Significant associations existed between body mass index (BMI) and anterior, middle, and posterior compartments, and between age and anterior/middle compartment prolapse ($p < 0.05$). Solely menopause showed a significant relationship with anterior compartment prolapse ($p < 0.05$).

Conclusion: The changes of coccyx angle, sacrococcygeal angle and sacrococcygeal joint angle in four phases of defecation were compared in women with POP. In order to facilitate defecation is believed that this change occurred. It is believed that determining the range of values for coccyx movement will make it easier to determine the pathological values of the disease.

Keywords: MR defecography, dynamic pelvic floor, pelvic floor dysfunction, pelvic organ prolapse, mobility of coccyx

O20 - Morphometric analysis of infraorbital canal in the dog

Nimet Turgut¹, Sadullah Bahar¹, Yağmur Güleç¹

¹Department of Anatomy, Faculty of Veterinary Medicine, Selcuk University, Konya, Türkiye

Objective: The infraorbital canal structural features are essential for successful surgical procedures such as nerve blocks and the application of catheters. In carnivores, the relationship of the foramens in this canal to bone reference points on the dry skull has been described, but information on its morphometric characteristics is limited. This study aims to determine the morphological and morphometric characteristics of the infraorbital canal in dog using Computed Tomography (CT).

Methods: The study used CT images of 4 healthy dog heads (2 males, 2 females) aged 4-12 years and from 3 different breeds. The images were transferred to RadiAnt DICOM Viewer. Using the program's Multiplanar Reconstruction tool, the diameter and cross-sectional area of the caudal and rostral openings, the middle part, and the length of the infraorbital canal were measured. The obtained data were presented as mean and standard deviation.

Results: The infraorbital canal was located dorsal to the last two the maxillary premolars, ventral to the nasolacrimal canal, and it was observed that the lateral wall of the maxillary recess formed the medial wall of the canal. The length of the canal was 19.41 ± 2.26 mm. The heights of the caudal, and rostral openings and the middle part of the canal were 11.78 ± 1.53 , 7.68 ± 1.10 and 6.35 ± 0.42 mm, the widths were 5.57 ± 0.36 , 3.39 ± 0.58 and 4.40 ± 0.41 mm, and the areas were 49.61 ± 9.42 , 21.46 ± 6.07 and 22.11 ± 3.83 mm², respectively. The infraorbital canal narrowed from caudal to rostral and had an asymmetric structure according to the results of the measurement parameters on each side of the head.

Conclusion: There is no obvious method for measuring canals and foramens on radiological images of dog skulls. The method used is based on measurements made on human skulls. We believe that measurements of related animal structures can be easily performed using this method and that the method is reproducible.

Keywords: computed tomography, infraorbital canal, carnivore, morphometry

O23 - Evaluation of the changes between the subcortical nuclei distances in patients after cardiopulmonary resuscitation by conventional magnetic resonance imaging

Hilal Melis Altıntaş¹, Gülhan Ertan Akan², Özge Arıcı Düz³, Berin Tuğtağ Demir¹, Bayram Ufuk Şakul⁴

¹Department of Anatomy, Faculty of Medicine, Ankara Medipol University, Ankara, Türkiye

²Department of Radiology, Faculty of Medicine, Istanbul Medipol University, Istanbul, Türkiye

³Department of Neurology, Faculty of Medicine, Istanbul Medipol University, Istanbul, Türkiye

⁴Department of Anatomy, Faculty of Medicine, Istanbul Medipol University, Istanbul, Türkiye

Objective: Although many markers are used for prognostication in the clinic, no consensus could be reached on issues such as the reliability of the tests used because individuals after cardiopulmonary resuscitation have many variables. This study, it was aimed to investigate the usability of changes in gray matter masses in the brain, which are sensitive to hypoxia, as a prognostic marker on MR images.

Methods: We retrospectively analyzed 50 patients and 105 healthy individuals whose spontaneous circulation was restored after cardiac arrest. On MRIs of patients and healthy individuals participating in the study, 12 measurements were made at the basal ganglia level in each hemisphere.

Results: When the patients after cardiopulmonary resuscitation were compared with the healthy individuals, the distances showing the width of the white matter were narrower in the patients and the distances showing the width of the gray matter were wider in the patients ($p<0.05$). The distance showing the gray matter width was found to be a strong marker in identifying patients poor neurological outcome ($p<0.05$).

Conclusion: Although we know that the findings obtained from cardiopulmonary arrest patients, who are a difficult group to study, are valuable, we think that more combination studies are needed by increasing the number of patients to gain clarity and certainty on this subject. The data obtained in this study, which examined the basal ganglia with MRI in individuals after cardiopulmonary resuscitation, together with other biomarkers may help determine the prognosis of the patient.

Keywords: basal ganglia, cardiac arrest, cardiopulmonary resuscitation, magnetic resonance imaging, thalamus

O24 - Radio-anatomical relationships between interdigital neuroma and hallux valgus angle

Birsen Arkar¹, Tuğrul Örmeci²

¹Arkar Therapy, İzmir, Türkiye

²Department of Anatomy, Faculty of Medicine, Istanbul Medipol University, Istanbul, Türkiye

Objective: Interdigital neuroma is a compressive neuropathy of the forefoot interdigital nerve. It is characterized by pain that radiates to the forefoot and toes. HV is a foot problem characterized by lateral deviation of the thumb and medial deviation of the first metatarsal bone. It is one of the most frequent progressive foot deformities that cause pain and functional limitations and disrupts the aesthetic appearance of the foot and restricts the activities of daily living. The basic aim of the study was to evaluate the radioanatomical relationships between interdigital neuroma and hallux valgus deformity.

Methods: A total of 60 patients, aged between 23 and 77 years, who applied to the Bagcilar Medipol Mega University Hospital Orthopedics outpatient clinic with the complaint of forefoot pain and were diagnosed with interdigital neuroma according to MRI and clinical examination, were included in the study retrospectively. HVA was measured on dorsoplantar foot radiographs while the patient was standing and weight-bearing. Interdigital neuroma AP and transverse diameters, and intermetatarsal bursitis AP and transverse diameters were measured on MRI. Pearson product moment correlation coefficients were calculated to evaluate the relationships between interdigital neuroma and HV deformity measurements.

Results: Interdigital neuroma AP diameter; intermetatarsal bursitis showed a significant negative correlation with AP diameter ($r = -0.37$). That is, the high AP diameter of the interdigital neuroma is accompanied by the low AP diameter of the intermetatarsal bursitis. HVA showed a significant negative correlation with intermetatarsal bursitis AP ($r = -0.29$) and transverse diameter ($r = -0.27$). In other words, high HVA brings with it intermetatarsal bursitis AP and low transverse dimension. No significant correlation coefficient was obtained between interdigital neuroma and HVA.

Conclusion: It was observed that there was no relationship between interdigital neuroma and HVA.

Keywords: hallux valgus, interdigital neuroma, radiological imaging

O26 - Anatomical features of the point which the superficial peroneal nerve pierces the crural fascia

Kıvanç Goral¹, [Elif Cansu İbiş¹](#)

¹Department of Anatomy, Faculty of Medicine, Istanbul University-Cerrahpasa, Istanbul, Türkiye

Objective: We aimed to determine the point which superficial peroneal nerve (SPN) pierces the crural fascia.

Methods: It was performed on 14 lower extremities of 7 male cadavers aged between 60 and 88 years. In our study, distance of the point which SPN pierces fascia to apex of head of fibula (AHF) was measured. Also, length of point which SPN pierces fascia to end point of lateral malleolus (LM) was measured. Taking fibula as a reference, leg was divided into three sections and point which SPN pierced fascia was classified according to these sections.

Results: SPN pierced fascia in 12 extremities. In two extremities, it was determined that SPN separated into its terminal branches called intermediate dorsal cutaneous nerve (IDCN) and medial dorsal cutaneous nerve (MDCN) before piercing fascia. In these two extremities, distances from point which the terminal branches pierced fascia to end point of LM and AHF were determined separately. In 12 extremities, average distance from point which SPN pierced fascia to AHF was 26.81 ± 3.34 cm and average distance from point which SPN pierced fascia to end point of ML was 11.35 ± 2.97 cm. In 10 of 12 extremities (83.33%), point which SPN perforated fascia was in distal 1/3 of leg and in 2 extremities (16.66%) point which SPN perforated fascia was in the middle 1/3 of leg. In two extremities which SPN was separated early, average distance of point which MDCN pierced fascia to AHF was 24.1 ± 5.09 cm and average distance of point which MDCN pierced fascia to end point of ML was 14.75 ± 1.48 cm was determined. The point which MDCN pierced fascia was located in the middle 1/3 of leg in 1 extremity and in distal 1/3 of leg in 1 extremity. The average distance of point which IDCN pierced fascia to AHF was 32.15 ± 3.6 cm and average distance of point which IDCN pierced fascia to end point of ML was 7.05 ± 0.07 cm. It was determined that point which IDCN pierced fascia was located in distal 1/3 part of leg in both extremities.

Conclusion: We think that the data we obtained will reduce possibility of nerve damage and increase chance of success in leg and ankle operations.

Keywords: superficial peroneal nerve, crural fascia, cadaver

O29 - Evaluation of the relationship of patients' body mass index with pelvis anatomy, prostate morphology and postoperative continence data

Elif Sena Ozcan^{1,2}, Burak Karakus³, Rahim Horuz³

¹Department of Anatomy, Faculty of Medicine, Istanbul Medipol University, Istanbul, Türkiye

²Department of Anatomy, Faculty of Medicine, Altinbas University, Istanbul, Türkiye

³Department of Urology, Faculty of Medicine, Istanbul Medipol University, Istanbul, Türkiye

Objective: The aim of this study is to evaluate the relationship of Body Mass Index (BMI) values of individuals with pelvis anatomy, prostate shape and continence data after radical prostatectomy.

Methods: The study was performed retrospectively on Magnetic Resonance (MR) images of 80 patients aged 50-75 years who had undergone radical prostatectomy for prostate cancer from the archive of Medipol Mega University Hospital. Demographic information of the patients, pelvimetric measurements obtained from MR images, age, PSA level, postoperative continence data, nerve sparing approach, pathological stage and surgical technique were compared.

Results: When all parameters were considered, the increase in the pubis-coccyx and prostate capsule-pubis distances significantly effective in achieving earlier and higher continence on the day of catheter removal, and the lower BMI were significantly effective in achieving earlier and higher continence in the postoperative 1st month (respectively $p=0,02$, $p=0,01$, $p=0,00$). From the pelvic measurements, the distance between the two tuber ischiadicum increased significantly as BMI increased ($p=0.03$). Of the patients without central lobe, 46.7% on the day of catheter removal, 66.7% on postoperative 1st month, and 80% at the postoperative 1st year were continent. Of the patients who underwent nerve-sparing approach, 54.5% on the day of catheter removal, 77.3% on the postoperative 1st month and 95.4% at the postoperative 1st year were continent. Of patients who had perineal surgery, 62.5% on the day of catheter removal, 87.5% on the postoperative 1st month, 100.0% at the postoperative 1st year were continents.

Conclusion: In conclusion, BMI, pelvimetric measurements, surgical technique effect postoperative continence results. Our study does not aim to compare the subgroup data statistically, as the number of participants is not sufficient to compare the subgroup data meaningfully, but aims to show their distribution.

Keywords: body mass index, pelvis anatomy, postoperative continence, prostate, radical prostatectomy

O30 - Anthropometric measurements of the nasal angles and ideal nasolabial angle perception

Niymet Pelin Çavdar Yılmaz¹, İbrahim Tekdemir¹, Ceren Bay², İrem Nur Yılmaz², Fatma Nur Ok², Aslı Ateş², Orhun Kelsaka², Ebubekir Demirtaş²

¹Department of Anatomy, Faculty of Medicine, Ankara University, Ankara, Türkiye

²Ankara University, Medical School, Ankara, Türkiye

Objective: Rhinoplasty is one of the most common plastic surgery procedures. This study aims to provide a new perspective to clinicians performing rhinoplasty and to contribute to literature by determining the social nasal angle morphometry and determining the society's ideal nasolabial angle tendency.

Methods: Measurements were taken and the survey was filled by students and research assistants of Ankara University Medicine Faculty between the ages of 18-35 (71 female, 71 male). At the first stage participants' nasal angles were measured while their heads were kept in a neutral/relaxed position parallel to the ground in the Frankfurt Horizontal plane and photographs were taken with a tripod from lateral and frontal views while the eyes were locked at a certain point at the same level, 1.5 meters far away. Then, angles were measured by using CS6 photoshop application. At the second stage, a survey of 12 questions was applied to the participants. IBM SPSS v26.0 was used for statistic measurements.

Results: Nasofacial angle was found $32,35 \pm 3,44$ in men and $32,54 \pm 3,17$ in women. Nasolabial angle was measured $99,51 \pm 9,51$ in men and $100,49 \pm 9,37$ in women. Nasofrontal angle was found $138,49 \pm 9,29$ in men and $141,64 \pm 8,1$ in women. Preferred nasolabial angle was found 91,32 in women and 94,78 in men. Manuel and photographic measurements were similar. Participants' predisposition to the rhinoplasty was found 1.9 over 5. The difference between participants's nasolabial angle and their preferred angle measurement haven't changed the esthetic perception. Participants had a disfavor for rhinoplasty. Participants who had previous rhinoplasty had the similar esthetic perception.

Conclusion: Thinking of the patient satisfaction is highly important in esthetics, preferred nasal anthropometric measurements have become determinants. In the present study not only the anthropometric nasal angle measurements have done but also esthetic perception have founded. Results could be useful for the preparation and planning of rhinoplasty.

Keywords: esthetics, rhinoplasty, nasolabial angle, nasofrontal angle, nasofacial angle

O33 - Evaluation of the branching angles of the tracheobronchial tree and the lung volume with the three-dimensional reconstruction method

Ayşe Erkaya¹, Zafer Kutay Coşkun², Seda Akyol³, Tuncay Veysel Peker², Tayfun Kuçlu⁴, Fatma Nur Baran Aksakal⁴, Aslı Beyza Tütüncü⁵

¹Department of Anatomy, Faculty of Medicine, Lokman Hekim University, Ankara, Türkiye

²Department of Anatomy, Faculty of Medicine, Gazi University, Ankara, Türkiye

³Department of Radiology, Memorial Ankara Hospital, Ankara, Türkiye

⁴Department of Public Health, Faculty of Medicine, Gazi University, Ankara, Türkiye

⁵Faculty of Medicine, Ankara Yıldırım Beyazıt University, Ankara, Türkiye

Objective: The aim of the research is to evaluate the branching angles of the tracheobronchial tree and the correlation between these angles and the lung volume using the three-dimensional reconstruction method.

Methods: Thorax CT (computed tomography) images of 150 individuals, who were over 18 years of age and didn't have any pathology on CT, were obtained retrospectively. The individuals included in the study were grouped by age and sex. The age groups were determined as 20-40 years, 41-61 years, and 62-87 years. A three-dimensional reconstruction of the trachea, bronchi, and lungs was carried out. External and internal angles between the trachea and main bronchi, between the main bronchi and lobar bronchi, and between the lobar bronchi were measured. Moreover, the volume measurement of the right and left lungs was performed.

Results: The internal and external angles between the right upper lobar bronchus and intermediate bronchus were found to be greater in the 20-40 age group. In this age group, the internal and external angles between the middle lobar bronchus and the right lower lobar bronchus were found to be greater. The left subcarinal angle, total subcarinal angle, and left interbronchial angle were found to be greater in the 62-87 age group. In males, a statistically significant negative moderate correlation was identified between the right lung volume and the right subcarinal angle. In females, a statistically significant positive moderate correlation was revealed between the external and internal angles between the right upper lobar bronchus and the intermediate bronchus, and the right lung volume.

Conclusion: In our literature review, we couldn't find any study investigating the correlation between the branching angles of the tracheobronchial tree and the lung volume using the 3-dimensional reconstruction method. Therefore, we think that our study will contribute to the literature.

Keywords: tracheobronchial tree, morphometry, lung volume

O34 - Gender estimation by using machine learning algorithms with parameters obtained from direct pelvic radiographs

Seyma Toy¹, Rukiye Ciftci², Yusuf Secgin¹, Zual Oner³, Serkan Oner⁴

¹Department of Anatomy, Faculty of Medicine, Karabuk University, Karabuk, Türkiye

²Department of Anatomy, Faculty of Medicine, Gaziantep Islam Science and Technology University, Gaziantep, Türkiye

³Department of Anatomy, Faculty of Medicine, Izmir Bakırçay University, Izmir, Türkiye

⁴Department of Radiology, Faculty of Medicine, Izmir Bakırçay University, Izmir, Türkiye

Objective: Gender prediction is a critical biomarker that is considered the first step in gender determination. The aim of this study is to obtain a gender estimation with higher accuracy and sensitivity by using machine learning algorithms with parameters obtained from direct pelvis radiographs.

Methods: The study was conducted on the direct pelvis radiographs (pelvis X-ray) of 99 males and 102 females between the ages of 20 and 65. X-ray images were transferred to Radiant DICOM Viewer program and anterior superior iliac spine length (AISL), iliac crest length (ICL), ischial tuberosity length (ITL), terminal line curvature length (TLCL), head of femur diameter (HFD), neck of femur diameter (NFD), transversal diameter (TD), conjugata vera (CV) parameters were measured. The measurements obtained were used in machine learning algorithms (ML) input to make gender estimation.

Results: As a result of ML analysis, the parameters obtained from the pelvis skeleton were found to have an accuracy rate between 0.90 and 0.95. As a result of SHAP analyser of Random Forest algorithm, NFD parameter was found to have the highest contribution in determining gender.

Conclusions: As a result of our study, it was found that with its compact structure, the pelvis showed high accuracy in gender estimation by using machine learning algorithms.

Keywords: pelvis, X-Ray, machine learning algorithms, gender estimation

O35 - Comparative assessment of GPT 3.5, Google Bard and Bing responses to different types of anatomy questions

Abdullah Ortadeveci¹, Hilmi Özden¹

¹Department of Anatomy, Faculty of Medicine, Eskisehir Osmangazi University, Eskisehir, Türkiye

Objective: Developing technology often leads to modifications and innovations in anatomy education. Anatomists are often at the forefront of adopting innovations. Artificial intelligence based applications (AIBAs), which can store, compute and analyze large amounts of data using machine learning and even improve its own efficiency through complex neural networks, has recently gained increasing popularity. In this study, we aimed to evaluate the answers of AIBAs to different types of anatomy questions and to make determinations about their algorithms for interpreting anatomical information.

Methods: The researchers asked 20 knowledge and 20 interpretation multiple choice questions to the AIBAs of GPT 3.5, Google Bard and Bing. The answers were evaluated in terms of correctness and duration. Answers and response times were statistically evaluated comparatively in terms of question type and AIBA.

Results: For knowledge questions, GPT 3.5, Bing and Google Bard scored 55, 70 and 70, respectively, while for interpretation questions these scores were 55, 65 and 45. While GPT 3.5 and Bing's score on knowledge or interpretation questions did not show a statistically significant difference, Bard scored significantly higher on knowledge questions ($p= 0.014$). While GPT 3.5 answered the knowledge questions in 6.65 seconds on average, the response time was 19 seconds for Bing, and 5.65 seconds for Bard. While no significance was detected between GPT 3.5 and Bard in terms of response time, Bing's response time was significantly higher than both applications.

Conclusion: The scores obtained by the AIBAs clearly show that these apps have remarkable anatomy knowledge and interpretation ability. Considering the differences in the apps' answers and response times to knowledge and interpretation questions, anatomists need to be effectively involved in the AIBAs process of learning anatomy and interpreting anatomical information.

Keywords: anatomy education, artificial intelligence, gpt 3.5, google bard, bing

O37 - Evaluation of anatomy according to pelvic floor dysfunction types in magnetic resonance defecography

Melike Taşçı¹, Nadire Ünver Doğan¹, Emine Uysal², Ahmet Kağan Karabulut¹, Hüsnü Alptekin³, Zeliha Fazlıoğulları¹

¹Department of Anatomy, Faculty of Medicine, Selcuk University, Konya, Türkiye

²Department of Radiology, Faculty of Medicine, Selcuk University, Konya, Türkiye

³Department of General Surgery, Faculty of Medicine, Selcuk University, Konya, Türkiye

Objectives: Pelvic floor dysfunction, arising from the weakening of pelvic support structures, leads to the loss of supporting elements for intrapelvic organs and the occurrence of prolapse. Prolapses can occur individually or together depending on the damaged structures. In our study, we aimed to investigate the varying pelvic anatomy in different types of pelvic floor dysfunction and the changes occurring during different phases of defecation, using a dynamic imaging method known as magnetic resonance defecography.

Methods: The study included a total of 206 patients, categorized as follows: 18 patients without pelvic floor dysfunction, 51 patients with only posterior compartment prolapse, 58 patients with anterior and posterior compartment prolapse, and 79 patients with anterior, middle, and posterior compartment prolapse. In patients, the presence and severity of cystocele, uterine prolapse, posterior compartment prolapse, and rectocele were determined. Measurements were taken for the thickness of the puborectalis muscle, H line, M line, anorectal angle, uterine version angle, fat thickness in front of the rectus abdominis muscle, presacral and suprapubic fat thickness.

Results: Evidence was found indicating that when prolapses coexisted, their severity manifested more intensely ($p=0.001$). The H line, M line, anorectal angle ($p=0.001$), presacral ($p=0.004$), and suprapubic ($p=0.027$) fat thicknesses were found to be significantly different among the groups. The thickness of the puborectalis muscle showed differences only on the right side among the groups ($p=0.038$). There was no significant difference among the groups in terms of the fat thickness in front of the rectus abdominis muscle and the position of the uterus ($p>0.05$).

Conclusion: Our study has found that parameters related to the pelvic floor and the positions of organs exhibit significant variability both across different types of dysfunction and across different phases of defecation. Thus, the study has highlighted the power of magnetic resonance defecography in demonstrating prolapse and its contribution to the assessment of changing pelvic anatomy.

Keywords: magnetic resonance defecography, pelvic floor, prolapse

O43 - Investigation of the anatomical properties of the superior transverse ligament (Whitnall's ligament) and its topographic relationship with neighboring structures on 100 orbits: cadaveric study

Gkionoul Nteli Chatzioglou¹, Özcan Gayretli², Kemal Turgay Özbilen³, Vildan Onal², Ayşin Kale²

¹Department of Anatomy, Faculty of Medicine, Istanbul Health and Technology University, Istanbul, Türkiye

²Department of Anatomy, Faculty of Medicine, Istanbul University, Istanbul, Türkiye

³Department of Ophthalmology, Faculty of Medicine, Istanbul University, Istanbul, Türkiye

Objective: This study was conducted to investigate the morphological and morphometric properties of the superior transverse ligament-Whitnall's ligament in detail and to reveal topographic relationship with the levator palpebrae superioris muscle and levator aponeurosis.

Methods: The study was performed on 100 orbits of 50 adult human cadavers (12 female and 38 male) in the laboratory of Istanbul University, Istanbul Faculty of Medicine, Department of Anatomy (Ethics committee approval date:31.03.2021; number:155281). Dissections of the anterior cranial fossa and orbital region were performed to reach the superior transverse ligament.

Results: The superior transverse ligament was found 3.19 ± 2.06 mm posterior to levator palpebrae superioris muscle in 87 orbits and just above the junction of levator palpebrae superioris muscle and levator aponeurosis in 13 orbits. The medial, central, and lateral anteroposterior lengths of the superior transverse ligament were 5.65 ± 2.01 mm, 6.48 ± 2.45 mm, and 5.94 ± 2.27 mm, respectively. According to the lengths, the ligaments were classified into four types; Type I-straight ligament (28%), Type II-lateral/medially deviated ligament (14%), Type III-irregular ligament (9%), and Type IV-central ligament (49%). Type IV was found to be the most common type among both genders and sides (49%).

Conclusion: The function of the superior transverse ligament is controversial although different opinions have been reported in the literature, it should be preserved in ptosis or orbital surgery as it supports the levator palpebrae superioris muscle to act. Therefore, the findings related to its morphometric-morphological features and the results of its localization gain importance during the approaches of orbital surgery.

Keywords: levator aponeurosis, morphology, orbital surgery, superior transverse ligament, Whitnall's ligament

O44 - Determination of the prevalence of retrotransverse and arcuate foramen of the Atlas with three-dimensional computed tomography images: a preliminary study

Kaan Çimen¹

¹Department of Anatomy, Faculty of Medicine, Sivas Cumhuriyet University, Sivas, Türkiye

Objective: The study aims to determine the prevalence of retrotransverse (RTF) and arcuate foramen (AF), their correlations with each other, and whether there are gender and age-related differences.

Methods: The study was a retrospective archive scan in an observational radiological anatomy setting. The study group consists of three-dimensional reconstructions of computed tomography (CT) images of patients who applied to our institution's clinics for various reasons (cerebrovascular disease, subarachnoid hemorrhage, head trauma, dizziness, headache). Exclusion criteria were craniocervical joint surgery, a fixation screw on the atlas, and CT images in which the integrity of the atlas could not be observed. Age, gender, AF, RTF prevalence, and bilaterality were evaluated and noted. The student's T-test was used to determine gender and age-related correlations between AF and RTF prevalence. The obtained data were evaluated in the SPSS (v. 23.0) program. $P < 0.05$ was considered statistically significant.

Results: A total of 1200 [567 Female (47.3%) / 633 Male (52.8%)] patient CT images were included in the study. The AF and RTF observed prevalences of 12.1% ($n = 68$), 19.7% ($n = 125$) ($t = 3.339$, $p = 0.001^*$); 11.6% ($n = 66$), 13.1% ($n = 85$) ($t = 0.953$, $p = 0.341$) in females and males, respectively. There was a statistically significant difference in the prevalence of AF between genders, while there was no difference in the prevalence of RTF. There was no significant difference between age and AF and RTF prevalence ($p > 0.05$).

Conclusion: It was determined that the prevalence of AF and RTF was not uncommon in the studied patient group. The high prevalence of AF, especially in men, shows that it should be considered in the clinic to prevent misinterpretations in radiological evaluations.

Keywords: atlas, retrotransverse foramen, arcuate foramen, computed tomography

O45 - Evaluation of maxillary sinus volume in three-dimensional digital models obtained from multidetector computed tomography images

Mustafa Tekeli¹, Huseyin Erdem², Yigit Cevik², Nazire Safak Kılıc², Omer Kaya³, Neslihan Boyan², Ozkan Oguz²

¹Department of Anatomy, Faculty of Medicine, Nigde Omer Halisdemir University, Nigde, Türkiye

²Department of Anatomy, Faculty of Medicine, Cukurova University, Adana, Türkiye

³Department of Radiology, Faculty of Medicine, Cukurova University, Adana, Türkiye

Objective: The aim of this study is to evaluate maxillary sinus volume bilaterally according to age and gender by using three-dimensional (3D) digital models created from multidetector computed tomography (MDCT) images.

Methods: In this study, 60 MDCT scans of 30 male and 30 female subjects with no history of trauma or disease in the head and neck region and no evidence of pathology were included. MDCT images were processed by manual segmentation in 3D slicer software. Maxillary sinus volumes were calculated in the created 3D digital models. Statistical analysis of the data was performed with IBM SPSS 20.0 statistical package.

Results: The mean maxillary sinus volume was 27.07 cm³ in males and 23.56 cm³ in females. There was no significant difference between the maxillary sinus volumes of females and males ($p>0.05$). There was no significant difference between age groups in terms of maxillary sinus volumes ($p>0.05$). According to Pearson correlation analysis, a positive and strong correlation was detected between right and left maxillary sinus and total maxillary sinus volumes ($0.8<r<1.0$). However, no significant correlation was found between age and these parameters.

Conclusion: In this study, the maxillary sinus volume in the Anatolian population was evaluated with 3D digital models created from MDCT images, and it was observed that there was no significant relationship with gender and age. Maxillary sinus volume is of critical importance especially for dentists and surgeons. A conscious assessment of this anatomical structure can reduce the risk of complications and increase the success of surgical interventions related to the ear, nose, throat, head, jaw and face.

Keywords: computed tomography, volume analysis, maxillary sinus

O46 - Anatomy and variations of the bronchial artery: Multislice computed tomographic angiography study

Garip Kılıç¹, Serra Öztürk¹, Ayşe Keven², Muzaffer Sindel¹

¹Department of Anatomy, Faculty of Medicine, Akdeniz University, Antalya, Türkiye

²Department of Radiology Faculty of Medicine, Akdeniz University, Antalya, Türkiye

Objective: The lungs have a pair of vascular supplies, including the pulmonary artery, which carries low-pressure, oxygen-free blood, and the bronchial artery (BA), responsible for carrying high-pressure, oxygenated blood. Our study aimed to evaluate the normal anatomy and variations of the BAs in a group of patients undergoing computed tomographic (CT) angiography of the thoracic aorta.

Methods: We retrospectively analyzed CT angiography images of the thoracic aorta captured between 2021 and 2022. These images were retrieved from the hospital PACS system (Sectra Workstation IDS7; Sectra AB, Linköping, SWEDEN). Any images with motion artifacts, those that couldn't be assessed, and patients under 18 years of age were excluded from the study.

Results: The total number of BAs of 344 patients in our study group was 859, of which 446 (52%) were right BAs and 413 (48%) were left BAs. When the total number of BAs was analyzed on a case basis, it was seen that 16 (4.7%) patients had 1 BA, 141 (41%) patients had 2 BAs, 130 (37.8%) patients had 3 BAs, and 45 (13%) patients had 4 BA branches. When the thoracic aorta and intercostal-bronchial common trunk (TICBA) were evaluated together, the most common combination was 1 right and 1 left bronchial artery branch and no branch from the TICBA was observed.

Conclusion: Multidetector CT offers interventionalists a comprehensive vascular access map before procedures. Understanding the variations in the BA is of great clinical significance.

Keywords: bronchial artery, variation, CT angiography

O48 - Evaluation of the association of the phrenic nerve with anatomical structures in the superior thoracic aperture and the importance of these relations in terms of clinical procedures: A cadaveric study

Nilay Yıldız¹, Gkionoul Nteli Chatzioglou², Osman Coskun¹, Aysin Kale¹, Ozcan Gayretli¹

¹Department of Anatomy, Faculty of Medicine, Istanbul University, Istanbul, Türkiye

²Department of Anatomy, Faculty of Medicine, Istanbul Health and Technology University, Istanbul, Türkiye

Objective: The phrenic nerve (PN) is the only motor nerve of the diaphragm and contains sensory fibers. Although it originates mainly from the C4 branch, it receives contributions from the C3 and C5 branches. In this study, the entry of the PN into the superior thoracic aperture and its morphometric relationships with the adjacent anatomical structures were examined to reduce possible complications in invasive procedures.

Methods: The study was performed in 27 unilateral-cadavers (15 males;12 females) in the laboratory of Department of Anatomy, Istanbul Medical Faculty. The clavicle was removed from the sternoclavicular joint to reach the PN. Subsequently, the brachiocephalic vein was also accessed and the PN was reached through the entrance to the superior thoracic aperture. The relationships of the PN with the jugular notch (JN), anterior scalene muscle (ASM), internal thoracic artery (ITA), subclavian artery (SA), common carotid artery (CCA) were evaluated using a digital caliper.

Results: In the 27 cadavers examined, the PN-JN distance, the distance from PN to medial edge of the ASM, the PN-ITA distance, the distance between the PN and the closest branch of the SA at the point where PN crosses the SA, the PN-CCA distance, the vertical length of the PN on the ASM, were found as mean 37.03±7.15mm, 8.43±4.16mm, 2.25±2.74mm, 5.14±3.45mm, 16.15±4.77mm, and 37.31±10.69mm, respectively. Where the PN crossed the SA, the closest branch of the SA was the thyrocervical trunk in 11/27 cadavers and the ITA in 16/27 cadavers.

Conclusion: Knowing the distance of the phrenic nerve to the vascular structures in the superior thoracic aperture and its position relative to the neurovascular structures at the entrance to the thoracic cavity is valuable in minimizing the possibility of nerve damage and preventing long-term complications.

Keywords: phrenic nerve, superior thoracic aperture, subclavian artery, internal thoracic artery, anterior scalene muscle

O50 - Investigation of cranioplasty performed with a 3D printed molded implant and its cosmetic effects: Case report

Yılmaz Yıldırım¹, Hakan Çakın², Umut Özsoy¹

¹Department of Anatomy, Faculty of Medicine, Akdeniz University, Antalya, Türkiye

²Department of Brain and Neurological Surgery, Faculty of Medicine, Akdeniz University, Antalya, Türkiye

Objective: Cranioplasty is a surgical procedure involving implanting a bone prosthesis to restore the cranial defects resulting from cranial trauma. The effectiveness of this procedure depends on prosthesis design, preservation of cranial integrity, and the achievement of aesthetic results. Shaping bone material used in prosthesis design on brain tissue may not yield satisfactory aesthetic outcomes, and the heat generated during the polymerization of polymethylmethacrylate (PMMA) presents another challenging factor. This study examines how pre-printed mold affects cranial asymmetry in a patient.

Case: A 46-year-old male patient's CT scan data who had undergone decompressive craniotomy was used for bone tissue segmentation and creating a three-dimensional model of the craniotomy region. This model was then employed to create a mold using a 3D printer during surgery. PMMA was poured onto the 3D-printed mold and carefully shaped to create a cranial prosthesis. The obtained prosthesis was fixed to the cranial defect using titanium screw plates. To evaluate soft tissue asymmetry, a 3D surface scanner was used to scan the entire head before the surgery and three months after. Asymmetry analysis was conducted by comparing the right and left halves of the head, and the root mean square error (RMSE) was calculated.

Conclusion: At the end of the three-month follow-up period, the RMSE decreased from 4.61mm to 1.88mm, indicating a significant reduction in asymmetry. Notably, the patient expressed high satisfaction with the aesthetic outcomes. Additionally, the surgeon reported a faster surgical procedure and more straightforward implementation, confirming the advantages of the proposed technique. This innovative approach improves cosmetic results and simplifies the surgical procedure, potentially enhancing the overall quality of care provided to patients undergoing cranioplasty. Further research and clinical application are necessary to confirm the broader applicability of this approach in craniofacial reconstructive surgery.

Keywords: cranioplasty, 3d printing, pmma, cranial defect

O51 - Evaluation of the relationship between static plantar pressure and gait biomechanical parameters in healthy adults

Merve İzci¹, Bihter Akinoglu², Hayri Baran Yosmaoglu³, Caner Incekas⁴, Can Pelin¹

¹Department of Anatomy, Faculty of Medicine, Baskent University, Ankara, Türkiye

²Department of Physiotherapy and Rehabilitation, Faculty of Health Sciences, Ankara Yildirim Beyazit University, Ankara, Türkiye

³Department of Physiotherapy and Rehabilitation, Faculty of Health Sciences, Baskent University, Ankara, Türkiye

⁴Department of Biostatistics, Faculty of Medicine, Ankara Medipol University, Ankara, Türkiye

Objective: Unbalanced distribution of body weight on the foot may affect the kinetic alignment and may cause postural changes during sitting, standing and walking. The aim of our study is to examine the relationship between pressure distribution parameters on the foot in a static position and foot pressure contact times during walking.

Methods Our study was conducted on 41 healthy male individuals (mean age: 21.93 ± 2.54 years; BMI: 24.77 ± 3.40 kg/m²). Foot pressure analysis was evaluated both in static position and dynamically during walking using the DIERS Pedogait (DIERS International GmbH, Schlangenbad, Germany) device. Dynamic plantar pressure measurements were examined as pressure durations (ms) affecting different parts of the foot within a gait cycle.

Results: A positive significant relationship was observed between the foot contact surface (cm²) in the static position and the rearfoot contact time (ms) during walking ($r = 0.352$). In dynamic conditions, between the midfoot and rearfoot contact times (ms) and the weight transfer of the body to the front (%) in the static position a negative significant relationship ($r = 0.350$; $r = 0.370$, respectively), between the midfoot and rearfoot contact times (ms) and the weight transfer of the body to the back (%) in the static position positive significant relationship ($r = 0.350$; $r = 0.370$, respectively) was observed ($p < 0.05$).

Conclusion: It was observed that the unbalanced distribution of body weight on the foot in the static position was related to the duration of foot pressure in dynamic conditions. For this reason, unbalanced distributions in plantar pressure evaluated in the static position should be supported with necessary conservative treatment methods.

Keywords: pedobarography, plantar pressure distribution, pressure-time integral

O54 - Evaluation of nasolacrimal duct morphometry in the Turkish population

Kadriye Betül Pence¹, Nureda Nalcaci¹, Bahar Tekin¹, Selva Sen¹, Gamze Ansen¹, Tugrul Ormeci², Neslihan Yuzbasioglu¹

¹Department of Anatomy, Faculty of Medicine, Istanbul Medipol University, Istanbul, Türkiye

²Department of Radiology, Medicana Atakoy Hospital, Istanbul, Türkiye

Objective: Detailed anatomical information about the nasolacrimal duct elucidates the etiology of primary acquired nasolacrimal duct obstruction (PANDO) and contributes to the clinic for effective treatment. This study aims to present norm data and determine differences between genders by examining the morphometry of the nasolacrimal duct in the Turkish population consisting of healthy individuals.

Methods: Computed tomography images taken in a healthy Turkish population of 150 people, 79 women and 71 men, were included in the study retrospectively. Images were modeled and analyzed using 3D Slicer version 5.2.2. The volume, surface area, vertical and horizontal length of the right and left side nasolacrimal duct at the starting point, and the distance between both nasolacrimal duct were evaluated. The data were analyzed with the SPSS package program.

Results: In this study, the average volume of the right nasolacrimal duct was $219.28 \pm 77.53 \text{ mm}^3$ in male and $193.82 \pm 75.71 \text{ mm}^3$ in female. The average volume of the left nasolacrimal duct was $213.14 \pm 73.82 \text{ mm}^3$ in male and $190.34 \pm 82.54 \text{ mm}^3$ in female. In both genders, vertical and horizontal length were statistically larger on the right side compared to the left side, but other parameters did not differ significantly for both genders when comparing the right and left sides ($p < 0.05$). There was a statistically significant high positive correlation between the volume and surface area of the right nasolacrimal duct in male and female gender ($p < 0.05$, $r = 0.961$, $r = 0.957$). There was a statistically significant high positive correlation for the left nasolacrimal duct only in male gender ($p < 0.05$, $r = 0.954$).

Conclusion: Differences between genders were detected in nasolacrimal duct morphometry. These findings allow the differentiation and understanding of acquired obstructions and safe surgical approaches.

Keywords: nasolacrimal duct, 3D Slicer, PANDO

O55 - Morphometric evaluation of corpus callosum by using magnetic resonance imaging in patients with amyotrophic lateral sclerosis

Zeynep Şengün¹, Alev Bobuş Örs¹, Şükrü Hakan Kaleağası², Anıl Özgür³

¹Department of Anatomy, Faculty of Medicine, Mersin University, Mersin, Türkiye

²Department of Neurology, Faculty of Medicine, Mersin University, Mersin, Türkiye

³Department of Radiology, Faculty of Medicine, Mersin University, Mersin, Türkiye

Objective: The current management of Amyotrophic lateral sclerosis (ALS), which includes the combination of upper and lower motor neuron damage, is inadequate in terms of diagnosis and prognosis. Due to the difficulty in recognizing the disease, especially in the early stages, our study aimed to examine the corpus callosum (CC) and to obtain a finding that would help the diagnosis of ALS disease.

Materials and methods: For this study, 60 cerebral MR images previously obtained with magnetic resonance (MR) imaging were used. On these images, CC length, thickness and angle of downward-facing aperture were measured in the midsagittal plane. Additionally, area measurements were made by dividing the CC into five regions. PACS (Picture Archiving and Communication Systems) software was used for measurements. 30 of the images belonged to ALS patients and 30 of them belonged to healthy individuals. Differences in measured parameters between these two groups were investigated. Additionally, extremity and bulbar onset types within the ALS patient group were compared.

Results: A statistically significant difference was observed between the patient and control groups in terms of CC thickness (CCK), area of the five regions (A1,2,3,4,5) and total CC area (CCTA) (CCK ($p<0,001$), A1 ($p=0,011$), A2 ($p<0,001$), A3 ($p<0,001$), A4 ($p<0,001$), A5 ($p=0,007$) ve CCTA ($p<0,001$)). Thickness and area measurement values of CC were found to be lower in ALS patients (CCK=5,13±0,72, A1=150,01±24,34, A2=132,92±26,54, A3=56,14±11,12, A4=30,68±5,10, A5=199,10±31,22, CCTA=565,36±87,44) than in the control group (CCK=6,71±0,41, A1=164,91±19,27, A2=160,4±13,72, A3=74,69±5,91, A4=37,47±5,20, A5=218,3±20,42, CCTA=655,77±43,47). A statistically significant difference was found between extremity and bulbar onset patients only in terms of CC angle measurement ($p=0,019$). It was determined that the CC angle (CCa) was narrower in patients with bulbar onset (CCa=81°,11±6,71) compared to those with extremity onset (CCa=87°,05±6,33).

Conclusion: In this study, morphological changes in CC were demonstrated between ALS patients and healthy individuals, and between limb onset and bulbar onset. It was thought that these data could contribute to the diagnosis of the disease, classification or scientific studies on the disease.

Keywords: amyotrophic lateral sclerosis, corpus callosum, magnetic resonance imaging

O59 - Morphometric evaluation of the intertubercular sulcus

Cem Erçalık¹, Elif Cansu İbiş¹, Ercan Tanyeli¹, Ali İhsan Soyloğlu¹, Ahmet Ertaş¹

¹Department of Anatomy, Faculty of Medicine, İstanbul University-Cerrahpaşa, İstanbul, Türkiye

Objective: The aim of this study was to evaluate the morphometric characteristics of the intertubercular groove at the proximal end of the humerus and to guide clinicians planning treatment for clinical problems in the shoulder region.

Methods: In this study, 65 (30 right, 35 left) proximal ends of the humerus belonging to the laboratory of the Department of Anatomy, Cerrahpaşa Faculty of Medicine, with no obvious anomalies or signs of trauma and of unknown sex and age were evaluated. Throughout the humerus and at its proximal end, based on other studies in the literature, length of the humerus (LoH), length of intertubercular groove (LoIG), depth of the intertubercular groove (DoIG), width of the intertubercular groove (WoIG), length of medial wall of intertubercular groove (LoMW), length of lateral wall of intertubercular groove (LoLW), opening angle of the intertubercular groove (OAIG), medial wall angle (MWA), width of the surgical neck (WoSN) and antero-posterior diameter of surgical neck (APDSN) were measured. A digital millimeter caliper and goniometer were used for these measurements. The data obtained were uploaded to the SPSS program and analyzed.

Results: In this study, LoH was 326.24 ± 19.78 mm, LoIG 73.60 ± 14.48 mm, DoIG 4.56 ± 0.81 mm, WoIG 10.37 ± 1.30 mm, LoMW 75.05 ± 13.55 mm, LoLW 91.21 ± 12.07 mm, OAIG 92.37 ± 21.63 degrees, MWA 52.32 ± 7.26 degrees, WoSN 27.27 ± 2.90 mm, APDSN 24.22 ± 2.58 were measured on average.

Conclusion: The morphology of the intertubercular groove is important in the pathophysiology of biceps tendinitis, one of the causes of shoulder pain, because of the tendon of the long head of the biceps brachii located in it. The intertubercular groove is also a surgically critical location in the surgery of humeral proximal end fractures and shoulder arthroplasties. We hope that the measurement results of this study will contribute to our clinical and anatomical knowledge about the intertubercular groove.

Keywords: intertubercular sulcus, humerus, biceps tendinitis, morphometry

O60 - Evaluation of body donation records and updates on awareness activities in Mersin University

Zeliha Kurtoğlu Olgunus¹, Alev Bobuş Örs¹

¹Department of Anatomy, Faculty of Medicine, Mersin University, Mersin, Türkiye

Objective: To share the findings about the studies on Body Donation Awareness and the current donation registrations status at Mersin University with the members of Anatomy society and to evaluate the findings in terms of contribution to the body donation road map.

Methods: The need to take measures to facilitate donations of body donor potentials were at the center of the activities. The following three addresses were focused on: 1- "Physicians and Medical Students" because they are often the first contact addresses for donors, 2- "Organ Donation Units" because they are addresses to which donors are frequently and incorrectly directed, and body donors are often organ donors at the same time, 3- "General Awareness of the Society" as it includes the individuals who can affect the donor decisions positively or negatively. Every year, during Body Donation Awareness Week, ceremony is held in memory of the cadavers buried that year. Thus "Ceremony of Thanks to the Silent Instructors of Medicine" provides regular briefing for medical students. Posters with QR codes directing to our informing website are displayed in the Organ Donation Unit of our hospital. The Head of the Anatomy attended the panel organized by the Mersin Metropolitan Municipality City Council for the Organ Donation Week.

Results: The number of donated cadavers to our laboratory so far is 12. The number of body donation registrations has increased by the range 11-19 per year in the last 6 years. Considerable amount of the donations were made through the organ donation unit of medical faculty.

Conclusion: The actions to improve body donations in the future should primarily involve the Organ Donation Units of health institutions throughout the province, and secondly, physicians working in the field.

Keywords: body donation, anatomy, organ donation unit, cadaver, mersin

O62 - Examination of cochlea dimensions in children with hearing loss aged 0-18 years: A 3D reconstruction study of cochlea

Saliha Seda Adanir¹, Mohammad Al Saadi², İlhan Bahşi¹, Piraye Kervancioğlu¹, Vedat Topsakal²

¹Department of Anatomy, Faculty of Medicine, Gaziantep University, Gaziantep, Türkiye

²Department of Otorhinolaryngology Head and Neck Surgery, University Hospital UZ Brussel, Vrije Universiteit Brussel, Brussels, Belgium

Objective: Cochlear variations are of key significance for clinical use of cochlear implants (CI). Cochlea dimensions assist the surgeon in electrode selection and surgical approach before CI surgery. Therefore, knowing cochlea's dimensions is considered significant, especially in childhood hearing loss (HL). It was aimed to examine cochlea dimensions in children aged 0-18 years with HL in this study.

Methods: High resolution computed tomography (HRCT) images of patients aged 0-18 years who applied to UZ Brussel Department of Otorhinolaryngology Head and Neck Surgery between March 2021 and 2022 for any reason were included in the study. Those who applied for reasons such as adenoids, sinusitis, etc. and had no hearing-related complaints were determined as healthy control group, and those with HL were determined as patient group. Patients over 18 years of age and those with a history of previous temporal bone surgery were excluded from the study. HRCT images in DICOM format were transferred to OTOPLAN, (CASCINATION AG, Bern, Switzerland). Anatomical landmarks were determined on HRCT sections for 3D reconstruction. Cochlear length, height, width and duct length were measured.

Results: HRCT images of a total of 69 patients (120±63 months; boy:34, girl:35), were analyzed. All parameters except cochlear height were statistically greater in boys than girls ($p=0.001$). Right cochlear height was found to be significantly lower in patients with hearing loss than in healthy control group ($p=0.03$). In patients with hearing loss, right cochlear height increased significantly with age ($p=0.01$), and cochlear diameter decreased with age ($p=0.031$).

Conclusion: A lower cochlear height and a significant increase in cochlear height with age in children with HL may be a sign of a cochlear congenital malformation. Considering the etiological factors that cause HL, it is thought that evaluation of cochlear dimensions before surgery may be beneficial for surgeon in terms of electrode selection and minimizing surgical complications.

Keywords: cochlea anatomy, cochlear dimension, cochlear variation, hearing loss

O64 - Gender comparison of acromion section area, acromial index, lateral acromial angle and critical shoulder angle in patients with shoulder impingement syndrome

Ayşe Baydere¹, Alper Atasever²

¹Vocational School of Health Services, Istanbul Aydin University, Istanbul, Türkiye

²Department of Anatomy, Faculty of Medicine, Istanbul Medipol University, Istanbul, Türkiye

Objective: Shoulder impingement syndrome (OSS) is compression of the tendons due to narrowing of the subacromial space for any reason. OSS typically causes weakness and/or pain in the shoulder area, loss of movement in the affected shoulder, difficulty sleeping. Osteophytes, hypertrophic changes, bone spurs in the acromion are known to be the major causes. Shoulder biomechanics differ significantly between genders. It is also known that men have more strength, women have more endurance. It was done to compare patients with OSS between genders using parameters and to investigate whether gender has an effect on OSS.

Methods: In the study, 100 patients between the ages of 21-65, who underwent shoulder MRI examination at Istanbul Medipol University Hospitals Radiology Department and were diagnosed with OSS, after complaining of shoulder pain, were retrospectively examined. Classified as 50 women-50 men. Acromion cross-sectional area, acromial index, lateral acromial angle, critical shoulder angle were measured in MRI. The statistical significance limit was determined as $p < 0,05$.

Results: Although the acromial index, critical shoulder angle didn't show a significant difference between genders; lateral acromial angle was significantly lower in women ($79,92 \pm 5,75$ vs $82,44 \pm 4,51$; $p = 0,017$) and acromial cross-sectional area was significantly higher in men ($2,06 \pm 0,40$ vs $1,56 \pm 0,31$; $p = 0,001$) was found. No statistically significant difference was found between the age factor and the parameters.

Conclusion: Consequently, it was seen that one of the factors that predisposes to this disease in patients with OSS is the gender factor. A low lateral acromial angle in women, a large acromion cross-section in men pose a risk. We think that in surgeries in patients with OSS, interventions to increase the lateral acromial angle in women, attempts to reduce the acromion cross-sectional area in men may provide ideas for clinicians' surgery planning.

Note: This study is derived from my master's thesis.

Keywords: acromion, acromial index, acromion cross-sectional area, gender, critical shoulder angle, lateral acromial angle

O66 - Does sphenoidal sinus pneumatization influences adjacent structures?

Ayfer Metin Tellioglu¹, Umut Şener², Işık Tuncer², Yasemin Durum Polat³

¹Department of Anatomy, Faculty of Medicine, Aydın Adnan Menderes University, Aydın, Türkiye

²Department of Anatomy, Faculty of Medicine, Aksaray University, Aksaray, Türkiye

³Department of Radiology, Faculty of Medicine, Aydın Adnan Menderes University, Aydın, Türkiye

Objective: The sphenoidal sinus (SS) is highly variable cavity in terms of adjacent structures and pneumatization. The extent of pneumatization can affect access to different regions of skull base through transsphenoidal approach and the protrusion of adjacent structures into SS that may increase iatrogenic injuries. Therefore, we aimed to determine the patterns of SS pneumatization and their influence on protrusion of adjacent structures.

Methods: A total of 200 (18-54 years, avg:35±9years, male:100; female:100) temporal computed tomography scans (slice thickness:0.5mm) were analyzed. SS pneumatization was assessed relative to the sella turcica (conchal, presellar, incomplete sellar, complete sellar) and clivus (subdorsal, dorsal, occipital, dorsoccipital). Greater wing, pterygoid process, and lesser wing pneumatization was also evaluated. The protrusion levels of optic nerve (II), maxillary nerve (V_2), mandibular nerve (V_3), nerve of pterygoid canal (VC), and internal carotid artery (ICA) was recorded. Data was analyzed by chi-square and multinomial logistic regression tests.

Results: SS pneumatization was mostly the complete sellar type (right:56%, left:56.5%). While the most common clival extension was the dorsal type (right:26%, left:27.5%), the lateral extension was full lateral (greater wing and pterygoid process) (right: 40%, left:42%). Lesser wing was frequently pneumatized on both sides (70%). The most frequent protrusion degree was, *less than %50*; for V_2 (right: 34%, left:28%) and ICA (right: 44%, left:42%); However, *absence of protrusion* was the most common for VC (right:44%, left:43%), V_3 (right:88%, left:84%), and II (right-left:29%). The lateral pneumatization had significant main effect on VC, V_2 , and V_3 protrusion ($p<0.001$) and ala minor pneumatization on II ($p<0.001$); whereas ICA was affected by sellar (right: $p<0.001$, left: $p=0.021$), clival (right: $p<0.001$, left: $p=0.01$), and lateral (right: $p<0.001$, left: $p=0.001$) pneumatization. The association of increment in protrusion with pneumatization was found as follows; V_3 : Full lateral; V_2 and VC: Greater wing and full lateral; ICA: Full lateral, complete sellar, and dorsoccipital; II: Lesser wing on both sides ($p<0.001$, all parameters).

Conclusion: Our results indicate that the direction and extent of pneumatization influence the protruded structure and its protrusion degree. We think that evaluating pneumatization patterns preoperatively in transsphenoidal approach may be appropriate and can reduce the risk of iatrogenic injury.

Keywords: sphenoidal sinus, pneumatization, transsphenoidal

O67 - Evaluation of coccyx morphology and morphometry in patients with ankylosing spondylitis

Ayfer Metin Tellioglu¹, Dilara İlyay¹, Yasemin Durum Polat²

¹Department of Anatomy, Faculty of Medicine, Aydın Adnan Menderes University, Aydın, Türkiye

²Department of Radiology, Faculty of Medicine, Aydın Adnan Menderes University, Aydın, Türkiye

Objective: Ankylosing spondylitis (AS) is a chronic inflammatory rheumatic disease of unknown cause, which mainly affects the sacroiliac joint and columna vertebralis, causing structural and functional disorders. It is unclear whether the coccyx, the last part of the columna vertebralis, is affected in this disease. In our study, we aimed to evaluate the coccyx morphologically and morphometrically and detect changes.

Methods: In the study, the coccyx of 180 patients with ankylosing spondylitis (aged 18-64 years, mean 42 ± 9 years, 90 males, 90 females) and 180 healthy individuals in the control (C) group (aged 18-64 years, mean 41 ± 13 years, 90 males, 90 females) was retrospectively examined using computerized tomography images. In the evaluation of coccyx morphology, coccyx type (according to the modified Postacchini-Massobrio classification), sacrococcygeal joint fusion and intercoccygeal joint fusion; in the evaluation of coccyx morphometry, coccygeal straight length, intercoccygeal angle and coccyx anterior-posterior diameter thickness were examined. Mann-Whitney U Test, Independent Samples T-Test and Chi-Square Test were applied in the statistical analysis of the data. $P < 0.05$ was considered significant.

Results: Coccyx type was found to be the most common type 2 in the AS (62.2%) and control (83.9%) groups. Type 3 coccyx was observed more commonly in AS (30.6%) than in the control group (6.1%) ($p < 0.001$). Sacrococcygeal joint fusion was present in 62.2% of patients with ankylosing spondylitis, while it was present in 36.1% of the control group ($p < 0.001$). Fusion of the first (AS:15%, C:7.8%; $P = 0.045$) and second (AS:79.4%, C:65%; $P = 0.002$) intercoccygeal joints was found to be more common in patients with ankylosing spondylitis. Statistically, coccygeal straight length and coccyx anterior-posterior diameter thickness were found to be larger and intercoccygeal angle was smaller in patients with AS ($p < 0.001$).

Conclusion: Our findings showed that coccyx morphology and morphometry changed in patients with ankylosing spondylitis. For this reason, we think that it is important to evaluate the coccygeal region for coccydynia in patients with AS.

Keywords: ankylosing spondylitis, coccyx, morphology, morphometry

O68 - Three-dimensional analysis of the difference in asymmetry between the feet of patients with cerebrovascular events and healthy individuals

Mehmet Karagülle¹, Yılmaz Yıldırım², Hatice İkizler May³, Umut Özsoy², Lütfiye Bikem Süzen⁴

¹Department of Therapy and Rehabilitation, Vocational School of Health Services, Antalya Bilim University, Antalya, Türkiye

²Department of Anatomy, Faculty of Medicine, Akdeniz University, Antalya, Türkiye

³Department of Physical Medicine and Rehabilitation, Antalya Atatürk State Hospital, Antalya, Türkiye

⁴Department of Basic Medical Sciences, Faculty of Dentistry, Antalya Bilim University, Antalya, Türkiye

Objective: This study aimed to conduct a three-dimensional analysis of foot asymmetry in patients who have suffered cerebrovascular events (stroke) compared to healthy individuals.

Methods: A total of fourteen patients experiencing right-sided paralysis and twenty healthy individuals participated in this study. All subjects enrolled in this study were scanned using a three-dimensional scanner to examine their feet. Scanning was conducted with the subject supinely, capturing slightly above the ankle level. The digital image of the left foot was mirrored and superimposed with the right foot to measure asymmetry. Asymmetry was quantified through the root mean square (RMS) difference values, with a higher RMS value indicating increased asymmetry. The study findings illustrate the occurrence of foot asymmetry.

Results: The mean RMS values of healthy participants were markedly lower than those of participants with cardiovascular events ($p < 0.05$). Additionally, upon comparing the asymmetry between the right and left feet of healthy participants with identical values in the cardiovascular event group, it was discovered that the right foot of the cardiovascular event group was significantly smaller than the left foot ($p < 0.05$).

Conclusion: Patients with cardiovascular events necessitate rehabilitation programs addressing balance and walking difficulties. Furthermore, certain patients with stroke may require orthotic devices. Our study's results will aid in creating rehabilitation programs and orthotic device designs for stroke patients.

Keywords: cerebrovascular event, foot asymmetry, three-dimensional analysis

O71 - The effect of high-fat diet during prenatal and postnatal periods on subcutaneous white adipose tissue adipocyte diameters

Gülay Madan¹, Yüksel Aydar²

¹Orthopedic Prosthesis Orthosis Program, Atatürk Health Services Vocational School, Afyonkarahisar Health Sciences University, Afyonkarahisar, Türkiye

²Department of Anatomy, Faculty of Medicine, Eskişehir Osmangazi University, Eskişehir, Türkiye

Objective: Changes in adipocyte diameters play a crucial role in the pathogenesis of obesity and related metabolic diseases. This study aimed to elucidate how a high-fat diet (HFD) during both prenatal and postnatal periods affects the morphology of subcutaneous white adipose tissue (WAT) adipocytes.

Methods: Eight female Wistar-Albino rats were divided into standard diet (SD) and HFD groups after mating. The offspring were further categorized into SD and HFD subgroups (SDSD, SDHF, HFSD, HFHF) after weaning. On postnatal day 63, animals were sacrificed, subcutaneous WAT samples were collected. Sections with a thickness of 5 μm were obtained from paraffin-embedded tissues and stained with hematoxylin-eosin (H&E). Stereological analysis was performed using Stereoinvestigator to calculate the mean diameter of adipocytes. Approximately 200-300 adipocytes from each group were measured for their long and short (a and b) axis lengths using systematic random sampling (SRS) with an 80x80 frame at 10X magnification. The mean diameter of adipocytes was calculated using the formula $\bar{D} = \sqrt{axb}$.

Results: Adipocyte diameters in subcutaneous WAT varied among diet groups, with the HFHF group having the largest median diameter (56.76) and the SDSD group the smallest (32.17). Differences in adipocyte diameters among groups were statistically significant ($p < 0.001$). In groups exposed to HFD, either maternally or in offspring diet, adipocyte diameters were significantly larger than the SDSD group.

Conclusion: Maternal and/or offspring exposure to HFD led to significantly larger adipocyte diameters in subcutaneous WAT throughout the study compared to the standard diet group (SDSD). This suggests a lasting impact of HFD during pregnancy and lactation on offspring adipose tissue growth and adipocyte diameter. Furthermore, both maternal and offspring exposure to HFD may have cumulative effects on adipocyte expansion, underscoring the potential long-term consequences of dietary choices during critical developmental periods.

Keywords: adipocyte diameter, stereology, subcutaneous white adipose tissue, high fat diet

O72 - The frequency of the bony parameters of femoroacetabular impingement syndrome in young asymptomatic individuals: a computed tomography study

Menekşe Cengiz¹, Serra Öztürk², Ayşe Keven³, Hande Salim⁴, Murat Gölpinar⁴, Kemal Gökkuş⁵, Muzaffer Sindel²

¹Department of Therapy and Rehabilitation, Physiotherapy Program, Vocational School of Health Services, Antalya Bilim University, Antalya, Türkiye

²Department of Anatomy, Faculty of Medicine, Akdeniz University, Antalya, Türkiye

³Department of Radiology, Faculty of Medicine, Akdeniz University, Antalya, Türkiye

⁴Department of Anatomy, Faculty of Medicine, Hitit University, Çorum, Türkiye

⁵Department of Orthopedics and Traumatology, Alanya Application and Research Center, Başkent University, Antalya, Türkiye

Objective: Femoroacetabular impingement syndrome (FAIS) is a painful hip disorder that develops as a result of abnormal contact between the femoral head-neck junction and the acetabulum edge in hip joint movement, especially in flexion. The main aim of our study is to determine the prevalence of radiological FAIS findings in the young asymptomatic adult Turkish population.

Methods: Patients who applied to Akdeniz University Medical Faculty Hospital with the diagnosis of acute appendicitis between 2015-2020 and 500 patients between the ages of 18-40 who had abdominal pelvic computerized tomography (CT) from renal transplant donor candidates were included in the study. Patients with previous pelvic trauma, oncological history and orthopedic disorders were excluded from the study. Alpha angle and femoral head offset measurement, which are indicators of glass-type deformity, acetabular version angle and central edge angle parameters, which are indicators of pincer deformity, were evaluated.

Results: In our study, FAIS was detected at a rate of 2.3%. Pincer was found in 56.5% of patients with FAIS and cam-type deformity was found in 43.5%. Pincer-type deformity was found in 83.3% of female and 47.1% of male, cam-type deformity was found in 16.7% of female and 52.9% of male. Pincer-type deformity is seen on the right side in 58.3% and on the left side in 54.5%; cam-type deformity was detected on the right side in 41.7% and on the left side in 45.5%

Conclusion: In our study, the prevalence of glass type deformity was lower in male, pincer type deformity in female asymptomatic adult population compared to the literature. While there was no significant difference between male and female alpha angles, the head and neck offset, central sharp edge angles were higher in male and the acetabular version angles in female were higher.

Keywords: femoroacetabular impingement syndrome, computed tomography, cam deformity, pincer deformity

O73 - The major arterial supply of the musculus temporalis: a cadaveric study

Necati Salman¹, Simel Kendir², Mehmet Yılmaz², Murat İçde³, Süleyman Tuna Karahan², Aysun Uz²

¹Department of Anatomy, Gülhane Faculty of Medicine, University of Health Sciences, Ankara, Türkiye

²Department of Anatomy, Faculty of Medicine, Ankara University, Ankara, Türkiye

³Department of Plastic Reconstructive and Aesthetic Surgery, Gülhane Faculty of Medicine & Gülhane Training and Research Hospital, University of Health Sciences, Ankara, Türkiye

Objective: The aim of the study is to determine topographically the starting points of the three main arteries supplying the temporalis muscle.

Methods: An observational cadaveric study was performed with 15 hemicraniums of 8 embalmed cadavers at the Ankara University School of Medicine Department of Anatomy. Before dissection, the external carotid artery was filled with red acrylic paint and liquid latex mixture. Measurements were made with a vernier digital caliper.

Results: A total of 8 cadavers, 6 male and 2 females were included in the study. The middle temporal artery, the posterior deep temporal artery, and the anterior deep temporal artery originated at a vertical distance of 22.8 mm, 23.2 mm, and 28 mm respectively below the upper line of the zygomatic arch. When the temporal root of the zygomatic arch was taken as a criterion, these three arteries' origin were found to be 6.8, 22.8, and 41.4 mm anterior, respectively, in the horizontal plane.

Conclusion: The origins of the three main arteries supplying the temporal muscle are located below the upper edge of the zygomatic arch and in front of the temporal root of the zygomatic arch. In dissection studies of the second part of the maxillary artery instead of the complete removal of the zygomatic arch as a dissection method; we suggest separating the zygomatic arch from its roots with the cranium and replacing the arch to the outer side.

Keywords: maxillary artery, temporalis muscle, zygomatic arch, superficial temporal artery, cadaveric study.

O75 - Could the biomechanical characteristics of the crural fascia in the anterior compartment be related to the levels of anterior leg pain occur in athletes?

İnci Kesilmiş^{1,2}, Zeliha Kurtoğlu Olgunus¹

¹Department of Anatomy, Faculty of Medicine, Mersin University, Mersin, Türkiye

²Department of Coaching Education, Faculty of Sports Science, Mersin University, Mersin, Türkiye

Objective: To determine whether the anatomical and biomechanical properties of the crural fascia in the anterior compartment of the leg indicate the levels of tibial stress fracture (TSF) and the “dreaded black line” phenomenon, which are often pointed as the cause of pain in athletes, and to evaluate the potential role of fascial tension in pain.

Methods: In 18 cadaveric legs (11 male, 7 female) fixed with 10% formalin, the fascia between the caput fibulae and the intermalleolar line was dissected, detached from the attachment line of the anterior intermuscular septum laterally, and deviated medially. The muscle fiber attachment area was mapped. Four equal parts was separated as upper-upper, upper-middle, lower-middle, lower-lower. Horizontal-vertical samples of 0.5 cm width and 2.5 cm length were taken from the parts.

Results: The muscle attachment area in all cases was approximately covered the proximal 1/3, while there was no muscle attachment in the lower-middle and lower-lower parts. Young’s modulus (E) values of vertical samples were higher than the horizontal samples for all levels. The E value of the horizontal samples of the four segments increased from proximal to distal, whereas the E value of the vertical samples decreased. There was no significant difference according to gender and side.

Conclusion: Biomechanical studies taking samples from a single level or in a single direction of the crural fascia can be misleading. The levels of muscle fiber attachment free areas in the study overlapped with the TSF levels. It was found noteworthy that for horizontal samples which represents the attachment/force transmission form of the crural fascia to the tibia, the elasticity decreases significantly towards the distal. The biomechanical and anatomical findings were interpreted with the literature related to fascial tension-related pain as well as TSF.

Keywords: crural fascia, biomechanics, Young’s modulus, lower extremity, stress fracture

O77 - Investigation of basis cranii interna morphology in anencephalic and normal fetuses

Mustafa Umut Çağlar¹, Kübra Erten¹, Derya Çağlar², Ali Faruk Özyaşar¹

¹Department of Anatomy, Faculty of Medicine, Karadeniz Technical University, Trabzon, Türkiye

²Güneysu Vocational School of Physical Therapy and Rehabilitation, Recep Tayyip Erdogan University, Rize, Türkiye

Objective: This study was planned to examine the basis cranii interna (BCI) morphology in anencephalic and normal fetuses.

Methods: The cranial base of 21 fetuses, 14 normal and 7 anencephalic, between 20.5 and 39.2 weeks of gestation, in 10% formaldehyde solution in our laboratory, were examined. Morphometric measurements of the BCI were performed. The scalp, calvarium, cerebrum, tentorium cerebelli and cerebellum were removed to reveal the BCI. The dura mater was carefully removed. BCI was photographed. The areas of anterior cranial fossa (ACF), middle cranial fossa (MCF), posterior cranial fossa (PCF), angles of cranial fossa (CF), lengths of cranial fossa, midline distances of foramen rotundum (FR), foramen ovale (FO), jugular foramen (FJ), vertical and transverse length and area of foramen magnum (FM) were measured with Image-J program. Fetuses were grouped according to gender and presence of neural tube defects. The data obtained were compared between the groups.

Results: CF areas, angles, vertical and transverse lengths; midline distances of FR and FJ, vertical and transverse lengths, areas of FM were not statistically significant when compared between genders and according to the presence of neural tube defects ($p>0.05$). Despite the asymmetry in the midline distance of the FO between male and female fetuses, the difference was not statistically significant ($p>0.05$); however, the FO in anencephalic fetuses was closer to the midline and this difference was statistically significant when compared with normal fetuses ($p<0.05$).

Conclusion: To know the BCI morphometry; It is important in interpreting the normal developmental process, identifying anomalies in the prenatal period, detecting possible malformations, surgical interventions for intracranial pathologies and congenital defects. When the findings were analyzed, the differences of some structures in BCI according to gender and neural tube presence are remarkable for a better understanding of the developmental process.

Keywords: anencephaly, basis cranii interna, fetus, morphometry

O78 - Radiologic identification and clinical significance of gastroduodenal artery origin; preliminary study

Buket Oğuz¹, Sezer Nil Yılmaz Zorlu², Aleyna Öner³, Emre Can Çelebioğlu², Selma Çalışkan¹

¹Department of Anatomy, Faculty of Medicine, Yildirim Beyazıt University, Ankara, Türkiye

²Department of Radiology, Faculty of Medicine, Ankara University, Ankara, Türkiye

³Clinic of Emergency Medicine, Safranbolu State Hospital, Karabük, Türkiye

Objective: Although endoscopic intervention is the gold standard treatment option in upper gastrointestinal tract bleeding it is not always sufficient to stop gastroduodenal artery (GDA) bleeding. In such cases, radiological embolization is a vital treatment option. Aim of the current study is to indicate the origin point of the GDA to prevent misembolization and lower procedural complication rates related with the origin of GDA.

Methods: 102 patients who underwent angiographic examination for various indications were retrospectively evaluated. Distance from the origin of common hepatic artery (CHA) to origin of gastroduodenal artery were measured from 2D digital subtraction angiographic (DSA) images.

Results: Of the 102 patients 52 (51 %) were men and 50 (49%) were women. 12(11 %) patients had active bleeding. Of the patients with active hemorrhage 66 % were men and 33% were women. Mean distance of origin point of GDA from origin of CHA was longer in men than in women. Mean distance of origin point of GDA from origin point of CHA was shorter in patients without hemorrhage (38,31 mm) than in patients with bleeding (39,65 mm).

Conclusion: Hemorrhage secondary to peptic ulcer is a significant risk for morbidity and mortality. Patients who are not able to be treated by endoscopic techniques and who are prone to rebleeding are the candidates for radiologic embolization. Insufficient anatomical knowledge of branching pattern of celiac trunk leads life-threatening complications as misembolization or unexpected tissue necrosis. Present study serves proper measurements among genders with or without gastrointestinal bleeding and demonstrates vascular anatomy.

Keywords: angiography, embolization, gastroduodenal artery, gastrointestinal bleeding

O79 - Morphological differences of nasal turbinates in pulmonary transplant candidate patients: a radiological study

Ekin Kartal¹, Eda Tezgör Aksakal², Sinem Akkaşoğlu¹, Hüseyin Çetin³

¹Department of Anatomy, Faculty of Medicine, Ankara Yıldırım Beyazıt University, Ankara, Türkiye

²Department of Radiology, Ankara City Hospital, Ankara, Türkiye

³Department of Radiology, Ankara Yıldırım Beyazıt University, Ankara, Türkiye

Objective: Aim of this study is to reveal the morphological differences of the middle and inferior turbinates in pulmonary transplant candidate patients and to compare them with the control group.

Methods: Paranasal sinus computed tomography images of 119 pulmonary transplant candidates were compared retrospectively with of 119 patients who underwent tomography for various indications. It was recorded whether there was atrophy in the middle and inferior turbinates and whether there was polypoid degeneration in the inferior turbinate.

Results: Of the 119 patients in the group which included pulmonary transplant candidate patients 80(%67) were men and 39 (%33) were women. In the control group 42 (%35) of 119 were men and 77 (%65) were women. The frequency of atrophy in the middle and inferior turbinates in male patients was found to be higher in the transplant group than in control group ($p<0,05$). The frequency of atrophy in the middle and inferior turbinates in women was found to be higher in the transplant group than control group. In the transplant group the frequency of atrophy in the right middle turbinate was found to be higher in women than in men.

Conclusion: Turbinates located on the lateral wall of the nasal cavity control the nasal air flow with their cavernous tissues. The cavernous tissue defined as 'corpora cavernosa' is especially well developed on the inferior turbinate and the overhanging border of the middle turbinate. The result of cyclic congestion and decongestion in the cavernous tissues appears as morphological diversity in the turbinates. Changes in turbinate morphology cause nasal air resistance to increase and decrease. The presence of atrophic turbinates in pulmonary transplant candidate patients leads to less nasal airway resistance. To our opinion this situation may be a adaptation to facilitate the work of breathing and occurs as a result of the reason that led to transplantation.

Keywords: paranasal sinus tomography, turbinate atrophy, pulmonary transplantation

O80 - Prevalence of Haglund deformity in Turkish population

Esin Özşahin¹, Mahmut Tunç², Sema Polat³, Zafer Altun⁴, Pınar Göker³

¹Department of Anatomy, Faculty of Medicine, Başkent University, Adana, Türkiye

²Program of Physiotherapy, Adana Vocational School of Health Service, Başkent University, Adana, Türkiye

³Department of Anatomy, Faculty of Medicine, Çukurova University, Adana, Türkiye

⁴Department of Radiology, Adana Dr. Turgut Noyan Application and Research Center, Başkent University, Adana, Türkiye

Objective: Pain may occur in the back of the ankle due to various reasons. Haglund deformity, which has the potential to be one of these, is defined as an abnormal bone protrusion in the posterosuperior region of the os calcaneus. The aim of this study is to determine the prevalence of Haglund deformity in Turkish society.

Methods: This study was conducted on lateral radiographic images of ankle recorded in PACS (Picture Archiving and Communication System) archive system of 420 healthy individuals consisting of 210 male and 210 female between the ages of 18-65, who had applied to Başkent University Adana Dr. Turgut Noyan Teaching and Research Hospital. This is a cross sectional retrospective study. In the study, measurements were made by an expert radiologist and anatomist using electronic calipers. In the study, Fowler-Philip angle, Heneghan-Pavlov parallel pitch lines tests and the X/Y ratio defined by Tourne et al. were performed bilaterally to determine Haglund deformity.

Results: According to the Heneghan-Pavlov parallel pitch lines test, the incidence of Haglund deformity was found to be 35.7% among 420 individuals with an average age of 42.41 ± 13.23 . In addition, 13.3% was seen unilaterally, while 22.4% was seen bilaterally. The rate of occurrence in the left foot (8.8%) is almost twice as high as in the right foot (4.5%). There was no statistically significant difference between genders ($p > 0.05$). For 420 individuals, the average Fowler-Philip angle was recorded as 64.24 ± 4.72 degrees on the right and 63.86 ± 4.70 degrees on the left. Additionally, a pathological angle value above 74 degrees was recorded in only 6 individuals (1.4%). According to the X/Y ratio defined by Tourne et al., the prevalence of Haglund deformity was found to be 31.9%. Moreover 22.6% were seen unilaterally, while 9.3% were seen bilaterally. Furthermore, the rate of occurrence in the right foot (15.2%) was more than twice as high as the rate in the left foot (7.4%).

Conclusion: In our study the prevalence of Haglund deformity was determined as 35.7% according to the Heneghan-Pavlov parallel pitch lines test, 1.4% according to the Fowler-Philip angle and 31.9% according to the X/Y ratio defined by Tourne et al. We believe that the results of the study will constitute reference values for the Turkish society and will also help clinicians in planning possible surgical interventions.

Keywords: calcaneus, haglund deformity, fowler-philip angle, prevalence

O81 - Do Turkish anatomists prefer to continue teaching anatomy after death?

Begümhan Turhan¹, [Melike Akcaalan](#)¹, Menekşe Karahan²

¹Department of Anatomy, Faculty of Medicine, Başkent University, Ankara, Türkiye

²Department of Anatomy, Faculty of Medicine, Kırklareli University, Kırklareli, Türkiye

Objective: Many anatomists work with donated bodies, although acquiring cadavers has been a big issue for a long time. The literature of medicine has been occupied with the attitudes of anatomists toward donating their own bodies. The objective of the study is to evaluate the attitudes of Turkish anatomists related to the donation of their own bodies' instruction material in the afterlife.

Methods: A descriptive cross-sectional investigation was carried out among anatomists in Türkiye during the months of March and April in 2023. Participants having anatomy instruction experience, lectured on cadavers, and had Ph.D. graduates were allowed for the investigation. An online survey was conducted whence a questionnaire constituted with Google Forms®. The survey includes a demographic data section, Likert-type multiple-choice items, open-ended questions, and yes-or-no questions.

Results: The questionnaire was replied by 133 anatomists from the anatomy departments in Türkiye. The mean age was 38.9 ± 7.30 years. 48% of the anatomists who replied were male, and 52% were female. Approximately 5% of the participants explained that they donated their bodies as cadavers. 76.7% of anatomists proposed to raise body donation as a solution to cadaveric inadequacy. There was a significant proportion (36.4%) of anatomists who donate organs but do not donate bodies.

Conclusion: Although many anatomists explain that there is a necessity for body donation, the rate of donating their own bodies seems quite low. We think that anatomists approve the importance of body donation, however they do not think of themselves as donors. Therefore, anatomists should be aware of body donation with the help of advance training, activities, and programs regarding to body donation. For this reason, we think that programs and activities should be scheduled, especially for the indecisive ones about body donation and those who only donate organs but do not donate bodies.

Keywords: body donation, anatomy teaching, attitude, anatomist

O84 - Safe zone for great auricular nerve block

Bahar Selenay Bulut¹, Mehmet Yılmaz¹, Aysun Uz¹, Ali Fırat Esmer¹

¹Department of Anatomy, Faculty of Medicine, Ankara University, Ankara, Türkiye

Objective: Although great auricular nerve neuropathy is often seen iatrogenically or as a result of cervical trauma, it is a very rare condition. In this neuropathic pain, anesthetic blockade can generally be performed as cervical plexus blockade from the punctum nervosum, or from the bifurcation in front of the sternocleidomastoid muscle with the help of US. In our study, we aimed to create safe areas for selective branch blockade by describing the position and bifurcation of the nerve branches with anatomical points.

Methods: In this study, dissections were performed on 3 heads fixed with 10% formaldehyde on 6 different sides. Our measurements were: A- distance from the lower border of the mastoid process to the great auricular nerve. B- distance from anterior branch of great auricular nerve to superficial temporal artery at tragus level C- distance of the great auricular nerve to posterior auricular artery at the lower border of the mastoid process

Results: In all samples, the nerve was divided into two terminal branches. Their approximate thicknesses were measured as 1.68 mm and 1.45 mm, respectively. The average distance from the lower border of the mastoid process to the bifurcation of the great auricular nerve is 21.54 mm. The distance between the anterior branch of great auricular nerve and the superficial temporal artery was measured as an average of 4.66 mm at the tragus level.

Conclusion: As a result, although great auricular nerve neuropathy is very rare, anesthetic great auricular nerve block provides relief for weeks or months, and this process can be repeated.

Keywords: great auricular nerve, superficial temporal artery, neuropathic pain, posterior auricular artery

O86 - Age estimation by using machine learning algorithms with parameters obtained from x-ray images of the calcaneus

Rukiye Çiftçi¹, Yusuf Seçgin², Zülal Öner³, Şeyma Toy², Serkan Öner⁴

¹Department of Anatomy, Faculty of Medicine, Gaziantep Islam Science and Technology University, Gaziantep, Türkiye

²Department of Anatomy, Faculty of Medicine, Karabük University, Karabük, Türkiye

³Department of Anatomy, Faculty of Medicine, İzmir Bakırçay University, İzmir, Türkiye

⁴Department of Radiology, Faculty of Medicine, İzmir Bakırçay University, İzmir, Türkiye

Objective: Determining the exact age of an individual is an important issue in forensic cases, medical applications and marketing sectors. In forensic cases, knowing the age of the individual is important in the application of criminal procedures, in medical applications in determining the correct dose and treatment protocol, and in the marketing sector in marketing the product correctly to the appropriate audience. This study was carried out to estimate age with high accuracy and reliability using machine learning (ML) algorithms with parameters obtained from direct radiographs (X-Ray) of the calcaneus bone.

Methods: The study was performed on X-ray images of 341 individuals aged between 20-80 years. The individuals were divided into three groups as 20-45, 46-64, and over 65 years of age. Maximum width, body width, maximum length, minimum length of the calcaneus, articular surface for cuboid height, maximum height (MAXH), calcaneal tuberosity width parameters were measured from the images. The obtained data were used in the introduction of ML algorithms to estimate age.

Results: As a result of the study, an accuracy of 0.85 was obtained with the Extra Tree Classifier (ETC) algorithm among the ML algorithms. The accuracy of other algorithms was between 0.78-0.82.

Conclusion: As a result of our study, it was concluded that high accuracy was achieved in age estimation using the ETC algorithm with the parameters we determined.

Keywords: calcaneus, X-Ray, machine learning algorithms, age estimation

O90 - Investigation of the effects of curcumin and resveratrol on the hippocampus in a streptozotocin induced Alzheimer's rat model

Derya Öztürk Söylemez¹, Dilek Sağır², Erdoğan Unur³

¹Department of Medical Services and Techniques, Vocational School of Health Services, Sinop University, Sinop, Türkiye

²Occupational Health and Safety, Faculty of Health Sciences, Sinop University, Sinop, Türkiye

³Department of Anatomy, Faculty of Medicine, Erciyes University, Kayseri, Türkiye

Objective: Alzheimer's is a progressive neurodegenerative disease. It is well-known that curcumin and resveratrol are used to reduce neuroinflammation and oxidative stress, which play an essential role in the pathogenesis of Alzheimer's disease. Therefore, this study aimed to investigate the effect of curcumin and resveratrol on neurotoxicity, which causes learning and memory loss, using behavioral, biochemical, histopathological, and stereological analyses.

Methods: Sixty male Wistar Albino rats were used as experimental models in the study. Six groups were formed, such as a control, SHAM, Streptozotocin-induced Alzheimer's, Alzheimer+curcumin, Alzheimer+resveratrol and Alzheimer+curcumin+resveratrol. Morris water tank test, open field test, and passive avoidance tests for behavioral tests, while GFAP and caspase-3 tests for immunohistochemical analyses, whereas total antioxidant/ total oxidant values for biochemical analyses and the Cavalieri method were used for stereological analyses.

Results: The current study showed that streptozotocin causes degeneration in neurons, while antioxidants positively affect cell survival. The biochemical analyses showed that the total oxidant level increased in the Alzheimer group. In the same group, cell density stained by caspase-3 (+) as a marker of apoptosis and cell density stained by GFAP (+), indicating astrocyte activity were higher than all other groups. It was observed that hippocampal volume loss was less for the groups in which curcumin and resveratrol were applied compared to the Alzheimer group. On the other hand, the combination of the two polyphenols did not cause a significant change in hippocampal volume compared to the Alzheimer group.

Conclusion: All the findings obtained from the study show that curcumin and resveratrol reduce the oxidative stress caused by streptozotocin application and neurodegeneration, decrease the hippocampal volume loss, and improve learning and memory functions. I believe that the results of our study will contribute to the literature on Alzheimer's, which has increased prevalence in recent years.

Keywords: Alzheimer disease, curcumin, hippocampus, streptozotocin, stereology

O92 - Examination of hippocampus volume in brain magnetic resonance images by age and gender using Volbrain

Kemal Emre Özen^{1,2}, Özge Coşkun², Cansu Kibar², Hatice Yenigül², Hassan Bagheri², Turgay Şahin³, Gülhan Ertan Akan⁴, Kadir Bozdoğan⁴, Niyazi Acer²

¹Department of Anatomy, Faculty of Medicine, İzmir Katip Çelebi University, İzmir, Türkiye

²Department of Anatomy, Faculty of Medicine, İstanbul Arel University, İstanbul, Türkiye

³Department of Physiotherapy and Rehabilitation, Faculty of Health Sciences, İstanbul Medipol University, İstanbul, Türkiye

⁴Department of Radiology, Faculty of Medicine, İstanbul Medipol University, İstanbul, Türkiye

Objective: The hippocampus is a neuroanatomical structure that plays a significant role in learning and spatial orientation that enables navigation. In this study, our aim is to examine the characteristics the hippocampus and its subregions (subiculum, dentate gyrus, cornu ammonis (CA1-CA4)) in our healthy population retrospectively through the analysis of magnetic resonance images with the Volbrain.

Methods: 138(female:66, male:72) no pathology on brain MRI individuals aged 4-88 years were included. High-resolution T1-weighted 3D images of subjects were used for the hippocampal volumes' analysis. Data analyses were performed using "VolBrain [<https://www.volbrain.net/>]-HIPpocampus subfield Segmentation (HIPS)" online system that performs automatic hippocampal segmentation. The hippocampus's ratios and hippocampal subfield volumes to total intracranial volume and total hippocampus volume were calculated.

Results: In volume measurements (cm³) of the hippocampus and its subregions, findings for males were found to be larger and statistically significant compared to females ($p < 0.05$). However, when we ratioed the hippocampus and its subregions to total intracranial volume and total hippocampal volume, no significant difference was found between genders. In females, the left subiculum was found to be larger than the right in both absolute volume (0.99 ± 0.14 cm³) and the ratio of total intracranial volume (0.08 ± 0.01 %) to total hippocampal volume (30.15 ± 3.70 %), and this difference was statistically significant ($p < 0.001$). In males, only a statistically significant difference was found in the ratio of total hippocampal volume of the left subiculum compared to the right ($p < 0.001$).

Conclusion: We believe that understanding how the hippocampal volumes of healthy individuals in the Turkish population will change depending on age and gender can contribute to understanding brain function. Therefore, we think that information about total hippocampus volume should also be taken into account in volume calculations, and that information about the ratio to total intracranial volume alone will not be sufficient.

Keywords: hippocampus, Volbrain, MRI

O93 - 'Neurocranium bones' in Miftah-ı Teşrih: Up-to-date explanation of anatomical terms

Mine Farımaz¹, M. Mustafa Aldur²

¹Department of Anatomy, Faculty of Medicine, Ufuk University, Ankara, Türkiye

²Department of Anatomy, Faculty of Medicine, Hacettepe University, Ankara, Türkiye

Objective: In the study, the relationship between the nomenclatures given on the neurocranium bone figures in the book titled Miftah-ı Teşrih, translated from French into Ottoman Turkish by Hristo Stambolski (1843-1932), who is considered one of the founders of modern anatomy in Turkish medical history, and current anatomical terms is examined.

Methods: Hristo Stambolski translated Joseph-Nicolas Masse's book titled Petit Atlas Complet d'Anatomie Descriptive du Corps Humain [1843] into Ottoman Turkish under the name Miftah-ı Teşrih (Rumi 1290, Gregorian 1874). The translated book was published as a single volume, 236 pages, by Mekteb-i Tıbbiye-i Şahane Printing House. Additionally, a 93-page dictionary (Lugat-ı Teşrih) is presented in French and Ottoman Turkish at the end of the book. This study was prepared by obtaining the exact edition of the book. Examinations were made regarding the naming of all anatomical formations in the figures of neurocranium bones in the book.

Results: The book titled Miftah-ı Teşrih, published by Hristo Stambolski, the dissection instructor at Mekteb-i Tıbbiye-i Şahane, has an important place among the medical school textbooks of the period. Based on this importance, in this book translated from French into Ottoman Turkish, neurocranium bones are examined specifically with their nomenclature. Differences and similarities have been tried to be shown by making comparisons with the terms used in Terminologia Anatomica, which is used as a reference book for terminology today.

Conclusion: The anatomical nomenclatures in Stambolski's translation of the figures have been observed to be compatible with the terms found in Terminologia Anatomica, as well as with the Latin terms used today to describe the bones of the neurocranium in atlases and books.

Keywords: anatomy, terminology, cranial bones, neurocranium, history of medicine

O94 - Anatomical variations of the petrosphenoidal ligament: a systematic review

Burak Oğuzhan Karapınar^{1,2}, Aymen Ahmed Warille², Orhan Baş³, Mehmet Emirzeoğlu²

¹Department of Medical Services and Techniques, Vocational School of Health Services, Ondokuz Mayıs University, Samsun, Türkiye

²Department of Anatomy, Faculty of Medicine, Ondokuz Mayıs University, Samsun, Türkiye

³Department of Anatomy, Faculty of Medicine, Ordu University, Ordu, Türkiye

Objective: Petrosphenoidal ligament (PSL) is an important structure located in the petroclival region. It usually extends between the petrous apex and the clivus or posterior clinoid process and forms the posteromedial wall of the Dorello canal. It is in close proximity to anatomical structures such as the abducens nerve, trigeminal nerve and carotid artery. PSL is used as an anatomical landmark in surgical approaches to the petroclival region. Dorsal meningeal artery and abducens nerve passes under this ligament. The morphology of PSL and its relationship with surrounding structures may vary. This situation is important from a clinical and surgical perspective. This study aims to examine the anatomical variations of PSL found in the literature and the clinical significance of these variations.

Methods: Various databases such as PubMed, Scopus, Google Scholar and Web of Science were used to collect cadaver and skull studies on the morphological features, common and rare anatomical variations and mineralization of PSL.

Results: When the morphology of PSL is examined, the butterfly-shaped (79.02%), triangle-shaped (4.99%) and Y-shaped (4.84%) are commonly seen. PSL shows partial or complete mineralization at a rate of 7.61%. Although mineralization is usually unilateral, there are rare cases where bilateral mineralization is observed. There are also rare cases where the right and left PSL join in the midline on the clivus, the anterior connection of the PSL is adherent to the carotid artery, and the PSL is hypoplastic or absent.

Conclusion: We think that increased knowledge about the morphological features and variations of PSL will make a significant contribution to surgical procedures related to the petroclival region, transnasal surgical approaches and surgical interventions involving the carotid artery.

Keywords: petrosphenoidal ligament, dorello canal, petroclival region, skull base

O96 - Morphometric evaluation of mitral valve apparatus and its clinical relations

Buse Naz Çandır^{1,2}, Çağla Ergin³, Kader Yılar¹, Osman Coşkun¹, Erdoğan Kara³, Ayşin Kale¹, Nilgün Bozbuğa⁴, Adnan Öztürk^{1,5}, Özcan Gayretli¹

¹Department of Anatomy, Istanbul Faculty of Medicine, Istanbul University, İstanbul, Türkiye

²Department of Anatomy, Faculty of Medicine, Istanbul Yeni Yüzyıl University, İstanbul, Türkiye

³Morgue Department, Council of Forensic Medicine, İstanbul, Türkiye

⁴Department of Cardiovascular Surgery, Istanbul Faculty of Medicine, İstanbul University, İstanbul, Türkiye

⁵Department of Anatomy, Istanbul Health & Technology University, İstanbul, Türkiye

Objective: The purpose of this study is to evaluate the morphologic and morphometric characteristics of the mitral valve apparatus (MVA) (fibrous ring, valve leaflets, tendinous cords and papillary muscles) and to reveal its clinical significance.

Methods: In total, 120 fresh human hearts were examined at the Forensic Medicine Institute. Cases aged 30 years and older, less than 24 hours after their death, were included in the study. As a result of macroscopic and histopathological laboratory examinations, 31 cases diagnosed as “cardiovascular disease” (CVD) were classified as pathological. Heart size, annulus anteroposterior and mediolateral diameters and area, length and width of leaflets, number and attachment sites of tendinous cords, number, shape, size and spatial configuration of papillary muscles were recorded. These parameters were compared with the sex, age, body mass index (BMI) and pathological conditions of the cases, risk factors affecting the presence of CVD were determined by logistic regression analysis, and diagnostic markers that could be used to determine pathological groups were determined by receiver operating characteristic (ROC) analysis.

Results: Heart length and width, and age and BMI of the individuals’ were identified as the main risk factors for the presence of CVD. Also, it was determined that BMI (>26.7), heart weight (>414 g), heart length/width ratio (≤ 1.24), mitral valve width (>99.96 mm), left ventricular wall thickness (>15.08 mm), annular area (>619.37 mm²) and mediolateral diameter of the annulus (>30.71 mm) are important diagnostic criteria in determining CVD if they are outside the specified reference values.

Conclusion: This study provides anatomical information and recommendations for proper coaptation, preservation of left ventricular function and prevention of technical errors in mitral valve repair and replacement operations. Therefore, we believe that our findings will help clinicians in the diagnosis, treatment plan and management of the surgical process of pathologies involving the MVA.

Keywords: mitral valve apparatus, left fibrous ring, mitral leaflets, tendinous cords, papillary muscles

O97 - Investigation of the protective effect of chrysin against pemetrexed-induced liver injury in rats

Beyza Özdemir¹, Evren Köse¹, Azibe Yıldız², Nesibe Yılmaz³, Kevser Tanbek⁴, Ayşegül Kısaoğlu¹, Süleyman Sandal⁴

¹Department of Anatomy, Faculty of Medicine, İnönü University, Malatya, Türkiye

²Department of Histology and Embryology, Faculty of Medicine, İnönü University, Malatya, Türkiye

³Department of Anatomy, Faculty of Medicine, Karabük University, Karabük, Türkiye

⁴Department of Physiology, Faculty of Medicine, İnönü University, Malatya, Türkiye

Objective: The aim of our study is to investigate the possible harmful effects of pemetrexed on rat liver and the protective role of chrysin against it.

Methods: In this study 50 male Sprague-Dawley rats were used. Group I was used a control group. Group II received a p.o. corn oil (chrysin solvent) (5 mg/kg/day for 28 days), group III received an i.p. PMTX (1 mg/kg/week for 4 weeks), group IV received a p.o. chrysin (50 mg/kg/day for 28 days), and group V received an i.p. PMTX (1 mg/kg/week for 4 weeks) + chrysin (50 mg/kg/day). After collecting blood and liver tissues, all rats were slaughtered at the conclusion of the 28th day. Serum samples were used to determine the levels of AST and ALT. The levels of SOD, MDA, TAS, and TOS in liver tissue were measured. Hematoxylin and eosin staining were used histologically, as well as caspase-3 and TNF-alpha immunohistochemistry.

Results: AST and ALT levels of the groups, PMTX group were detected significantly increased when compared to other groups ($p < 0.005$). When MDA levels were compared, the PMTX group increased significantly ($p < 0.005$) compared to the control, sham, and CHR groups, whereas SOD enzyme activity was found to be significantly lower in the PMTX group compared to the other groups ($p < 0.005$). TAS levels in liver tissue were examined to be considerably lower in the PMTX group than in the control, sham, and CHR groups ($p < 0.005$). Although TOS levels in the PMTX group were higher than in the other groups, the difference was not statistically significant. There was no histopathologically significant difference between the groups. Pemetrexed treatment was found to enhance caspase-3 and TNF- immunoreactivity, which was statistically significant when compared to other groups ($p < 0.01$). In the PMTX+CHR group, immunoreactivity to caspase-3 and TNF- was significantly reduced ($p < 0.001$).

Conclusion: In our study, it was determined that chrysin protects tissues against damage in pemetrexed-induced liver toxicity by acting as an antioxidant.

Keywords: pemetrexed, chrysin, liver toxicity, oxidative stress

O98 - Correlation of craniovertebral junction morphological values in the Anatolian population

Asrın Nalbant¹, Özden Bedre Duygu¹, Halide Temelci¹, Zülal Öner¹, Serkan Öner²

¹Department of Anatomy, Faculty of Medicine, İzmir Bakırçay University, İzmir, Türkiye

²Department of Radiology, Faculty of Medicine, İzmir Bakırçay University, İzmir, Türkiye

Objective: The number of studies examining the typical structure of the craniovertebral junction (CVJ) is insufficient. This study aimed to evaluate the typical structure of the CVJ on computed tomography (CT) and to determine the correlation of the parameters with each other.

Methods: 100 individuals (50 women, 50 men) between the ages of 25-45, who applied to İzmir Bakırçay University Çiğli Training and Research Hospital between 2018 and 2022 and had a head and neck CT scan were evaluated and 14 craniometric measurements evaluated on the sagittal plane in the study. These measurements are Cobb angle, anterior atlantodental length, posterior atlantodental length, length between McRae line and dens axis, Wackenheim clivus canal angle, Welcher basal angle, craniocervical tilt angle, Powers ratio, foramen magnum width, clivus length, length between the line extending from the lower border of the basion to posteroinferior of the axis and posterosuperior of the dens axis (pB-C2 line), dens axis width, dens axis length and dorsum sellae, basion, ophisthion angle.

Results: The average age of female and male patients are 37.24 ± 6.52 and 35.04 ± 5.75 , respectively. A significant positive correlation was found between the Cobb angle and dorsum sellae, basion, ophisthion angle. A significant positive correlation was detected between anterior atlantodental length and posterior atlantodental length variables. Posterior atlantodental length was correlated significantly with length between the McRae line and dens axis, Wackenheim clivus canal angle, foramen magnum width, dens axis width, and dens axis length. Significant positive correlations were found between the length of the McRae line and dens axis, and posterior atlantodental length, Wackenheim clivus canal angle, craniocervical tilt angle, foramen magnum width, clivus length, dens axis width.

Conclusion: CVJ anatomy and detection of CVJ anomalies are important for radiologists and neurosurgeons, and CT is the substantial method to evaluate them. We suppose that this study will significantly contribute to the literature and these findings obtained from healthy individuals with CT imaging will guide the evaluation of CVJ anomalies.

Keywords: craniometry, craniovertebral junction, cobb angle, mcrae line, cranium

O99 - Evaluation of the relationship between mylohyoid ridge and mandibular morphometry

Selva Şen¹, Melike Nur Girit¹, Gamze Ansen¹, Kadriye Betül Pençe¹, Neslihan Yüzbaşıoğlu¹

¹Department of Anatomy, Faculty of Medicine, İstanbul Medipol University, İstanbul, Türkiye

Objective: The mylohyoid line (linea obliqua interna/ mylohyoid ridge), the attachment site of the mylohyoid muscle, is a bony structure that can be both palpated and visualized radiologically in the posterior mandible. The aim of this study was to determine the relationship between mylohyoid line (ML) and mandibular morphometry to guide surgical interventions in the oral region.

Methods: The shortest and longest depths of the ML, the distances between the depth of the ML and the upper and lower edges of the mandible, the distances between the top of the ML and the upper and lower edges of the mandible, the distances between the mandibular canal and the depth of the ML, and the distances between the mandibular canal and the top of the ML were measured from the point between the second molar and the first molar tooth root using RadiAnt radiological examination program on Cone Beam Computed Tomography images.

Results: In total, 29 right (48.3%) and 31 left (51.7%) hemi-mandibles were evaluated in 60 cases, 24 females (40%) and 36 males (60%). Mean longest depth of ML: 7.34 ± 1.71 mm, ML shortest depth 3.65 ± 0.95 mm, ML to mandibular lower edge distance 12.60 ± 1.54 mm, ML to mandibular upper edge distance 13.79 ± 2.69 mm, ML upper point to mandibular lower edge distance 18.76 ± 2.37 mm, LM upper point-mandibular upper edge distance 7.71 ± 2.19 mm, ML upper point-mandibular canal distance 9.16 ± 1.95 mm, ML depth-mandibular canal distance 3.92 ± 0.87 mm. There was no statistically significant difference between the measured parameters according to gender and hemi-mandibular side evaluated.

Conclusion: Knowledge of the relationship between the mylohyoid line and mandibular morphology may guide clinicians as a safe landmark during interventions in the posterior mandibular region.

Keywords: mylohyoid line, mylohyoid ridge, mandibular morphology, anatomy, CBCT

O101 - Cystic duct opening variations: A preliminary study

Zekiye Karaca Bozdağ¹, Emre Bozdağ², Ayla Kürkçüoğlu³, Buse Naz Çandır¹, Süleyman Sönmez⁴

¹Department of Anatomy, Faculty of Medicine, Istanbul Yeni Yüzyıl University, İstanbul, Türkiye

²Gastroenterology Surgery Clinic, Kanuni Sultan Süleyman TRH, Health Sciences University, İstanbul, Türkiye

³Department of Anatomy, Faculty of Medicine, Kırıkkale University, İstanbul, Türkiye

⁴Radiology Clinic, Kanuni Sultan Süleyman TRH, Health Sciences University, İstanbul, Türkiye

Objective: The aim of this study is to demonstrate different anatomical variations of the cystic duct using Magnetic Resonance Cholangiopancreatography (MRCP) and to determine the prevalence of extrahepatic bile duct length measurements in our sample population.

Methods: In this retrospective study conducted between 2020 and 2022, a total of 67 patients who presented with severe abdominal pain and underwent MRCP for suspected acute pancreatitis at Kanuni Sultan Süleyman Training and Research Hospital were evaluated for the presence of cystic duct variations. The most commonly used classification based on the common hepatic duct (posterior, anterior, superior, parallel) was then applied.

Results: Evaluation of cystic duct variations showed that 52.2% (n=35) were normal, 22.4% (n=15) posterior, 14.9% (n=10) superior, 7.5% (n=5) parallel and 3.0% (n=2) anterior. The cystic duct angle was 41 degrees (range: 23-67), interquartile range (IQR): 13.25, Q1: 35, Q3: 49. The length of the cystic duct was 28 mm (range: 4-63), IQR: 10, Q1: 23, Q3: 33, while the length of the common hepatic duct was 31 mm (range: 17-56), IQR: 10, Q1: 25, Q3: 36. The length of the common bile duct was 38 mm (range: 24-60), IQR: 12, Q1: 33, Q3: 45.

Conclusion: Variations in cystic duct size are not uncommon. Recognition of anatomical variations not only aids in accurate interpretation of the disease process, but also has implications for preoperative and surgical approaches.

Keywords: cystic duct, variation, extrahepatic biliary tract, MRCP

O104 - Topographic and morphometric anatomy of the distal part of the dorsal scapular nerve

Beyza Çelikgün^{1,2}, Özcan Gayretli², İlke Ali Gürses³, Osman Coşkun², Adnan Öztürk¹, Ayşin Kale²

¹Department of Anatomy, Faculty of Medicine, Istanbul Health and Technology University, İstanbul, Türkiye

²Department of Anatomy, Istanbul Faculty of Medicine, Istanbul University, İstanbul, Türkiye

³Department of Anatomy, Faculty of Medicine, Koç University, İstanbul, Türkiye

Objective: A review of the literature shows that most studies of the dorsal scapular nerve (DSN) have focused on morphological evaluation of the proximal part of the nerve. Morphometric studies contributing to clinical applications are limited. Therefore, we aimed to examine the topographic and morphometric anatomy of the distal part of the DSN.

Methods: In our study, 13 cadavers in the Department of Anatomy, Istanbul Faculty of Medicine were examined bilaterally. DSN dissection was performed on the anterior surface of the levator scapulae and rhomboids, and the distance to the medial border of the scapula (MBS) was recorded at different levels. The insertion lengths of the levator scapulae and rhomboids were also measured. SPSS 23 program was used for statistical analysis of the data and T test, Mann-Whitney U test, ANOVA test and Chi-square test were applied.

Results: Two types of DSN were observed according to the level of termination in the muscle. Contrary to its classical course, the nerve ran laterally to the MBS on the 4 sides. The shortest distance between the nerve and the MBS was at the level of the superior border of the rhomboid minor. The insertion lengths of the levator scapulae and rhomboids according to gender and the insertion length of the rhomboid minor according to the level of termination in the muscle were significant ($p < 0.05$).

Conclusion: In our study, we obtained results that may be useful during Eden-Lange triple tendon transfer for restoration of trapezius muscle function. The DSN is not always located medial to the MBS, it may be located lateral to it. In order to avoid nerve damage, we believe it is important to identify the nerve on the anterior surface of the muscles for a successful surgery.

Keywords: dorsal scapular nerve, Eden-Lange tendon transfer, levator scapulae muscle, rhomboid muscles

O105 - Investigation of the relationships between craniofacial asymmetries and trunk asymmetries

Begümhan Turhan¹, Fatma Nur Alçın², Hilal Doğan³, Nilufer Çetişli-Korkmaz⁴

¹Department of Anatomy, Faculty of Medicine, Başkent University, Ankara, Türkiye

²Göhlisar Vocational School of Health Services, Burdur Mehmet Akif Ersoy University, Burdur, Türkiye

³Vocational School of Health Services, Harran University, Şanlıurfa, Türkiye

⁴Faculty of Physiotherapy and Rehabilitation, Pamukkale University, Denizli, Türkiye

Objective: The relationships between the trunk and facial asymmetries were not clearly shown in the literature. Based on the fact that asymmetries in the body are a holistic alignment problem, we aimed to investigate in this study whether craniofacial asymmetries could be a predictor of spine asymmetries or not.

Methods: Female individuals aged between 18 and 25 years (n=110) participated in this cross-sectional descriptive-analytic study. The angle of trunk rotation was measured by a scoliometer in conjunction with the Adams forward-bending test. Individuals in the control group (n =57) had spinal curvature of 0-3 degrees, and individuals in the study group (n=53) had spinal curvature of between 4-6 degrees. Facial anthropometric measurements of individuals were evaluated by referencing anatomical landmarks determined on the face with 2-dimensional photogrammetry using ImageJ (Version 1.53q) program.

Results: The mean age of the participants was 21.03 ± 1.95 years. Most of them were right-handed (n=103) and their chewing side was right (n=89). Both groups were similar in terms of facial anthropometric measurements ($p > 0.05$). Axial trunk rotation values of the midthoracic and thoraco-lumbar regions were significantly higher on both sides of the asymmetry group ($p < 0.05$). The distances between facial landmarks are not associated with asymmetries of spine regions ($p > 0.05$).

Conclusion: Although the sensitivity and predictive value of facial asymmetries in determining trunk asymmetries and sagittal spinal posture were low, it was concluded that comparative studies are needed, especially in individuals with asymmetry at the level of scoliosis, as the asymmetries of the individuals in our study were not at the level of scoliosis.

Keywords: craniofacial morphology, face anthropometry, spinal posture, trunk asymmetry

O106 - Morphometric examination of the relationship between spina ossis sphenoidalis and anatomical landmarks at the skull base

Eda Duygu İpek¹, Berrin Özüstün¹, Ilgaz Akdoğan¹

¹Department of Anatomy, Faculty of Medicine, Aydın Adnan Menderes University, Aydın, Türkiye

Objective: Spine of sphenoid bone (SOS), is a projection located on sphenoid bone, proximity to medial and lateral sides with chorda tympani, auditory tube, and auriculotemporal nerve respectively, attached tensor veli palatini and tensor tympani muscles, sphenomandibular ligament, anterior ligament of malleus. Foramen spinosum variable localization concerning SOS can impact the course of middle meningeal artery, making this proximity significant from both surgical, clinical perspectives. The aim of this study is to evaluate anatomical structures associated with SOS, and their distance from surgical entry points, to assess foramen spinosum localization in relation to SOS.

Methods: A total of 65 adult skulls from archive of Anatomy Department were used. Using digital calipers, measurements were taken distance of SOS to articular tubercle, mastoid process, external opening of carotid canal, infratemporal crest, and point where sphenosquamosal suture intersects infratemporal crest and its length. The SOS was morphologically categorized. Foramen spinosum localization relative to SOS was evaluated. In statistical analysis, morphometric measurements were compared between sides and among different types of SOS. Localization of foramen spinosum according to SOS types determined with chi-square test.

Results: SOS length was found different between sides. In our study, most common SOS type was square-shaped on both sides, with percentages of 33.8% and 36.9%, respectively, followed by spine-shaped at 23.1% and 18.5%. On the left side, SOS length was significantly lower in bones with chalice-type SOS compared to bones with spine-shaped SOS. According to chi-square results, there was a relationship between foramen spinosum position and SOS type on both sides ($p < 0.05$). Foramen spinosum was most commonly located anteromedially relative to SOS on both sides, and least commonly anterolaterally.

Conclusion: Our study provides morphometric data about localization of SOS with respect to anatomical structures and surgical points, reports a relationship between localization of foramen spinosum and SOS type. We think that more detailed research on this issue will provide important clinical contributions.

Keywords: spine of sphenoid bone, skull base, foramen spinosum, morphometry

O107 - Evaluation of cerebellum lobule volumes using magnetic resonance imaging in patients followed by the diagnosis of schizophrenia

Vahide Tutuk¹, Çiçek Hocaoğlu², Özdemir Sevinç³

¹Department of Anatomy, Faculty of Medicine, Ankara Yıldırım Beyazıt University, Ankara, Türkiye

²Department of Psychiatry, Faculty of Medicine, Recep Tayyip Erdoğan University, Rize, Türkiye

³Department of Anatomy, Faculty of Medicine, Sanko University, Gaziantep, Türkiye

Objective: Measurement of cerebellum volume in schizophrenia is important to detect neuroanatomical changes that occur in the etiology and process of the disease. The aim of the study is to measure cerebellar lobule volumes in patients diagnosed with schizophrenia automatically through the VolBrain program using cranial magnetic resonance images (MRI) and compare the results with the healthy group.

Methods: The study was conducted retrospectively in the psychiatry outpatient clinic with 57 patients aged 20-45, diagnosed with schizophrenia according to DSM-IV-TR diagnostic criteria, who were followed up as outpatients or inpatients, with a disease duration of 5 years or less, and 50 healthy controls. In the control and case groups, cerebellar lobule volumes in cranial MRI were measured automatically with the online VolBrain program CERES technique.

Results: It was determined that the total volume of lobule V and lobule VI, the volume of left lobule V and left lobule X decreased in schizophrenic patients. In addition, it was found that the total volume of lobules I-II, III, as well as VIIB, the right and left lobules I-II, lobule III and lobule VIIB had larger volumes compared to the normal population.

Conclusion: In patients with schizophrenia, emotional dysfunction may be caused by decreased volume of cerebellar lobules I-II-III and decreased volume of lobule V may also explain sensorimotor, emotional and motor process disorders. The cognitive dysfunctions, underlying the disease, are revealed by volume reduction in lobule VI and lobule X. In addition, the volume reduction in lobule VI reflects the anatomical localization of the impairment in emotion, memory and information retrieval functions observed in schizophrenia patients.

Keywords: cerebellum volume and lobules, schizophrenia, Volbrain

O110 - Evaluation of thalamus volume and cell numbers in adolescent autistic rats: A stereologic study

Erdal Horata¹, Hakan Ay²

¹Department of Orthopedic Prosthesis-Orthosis, Atatürk Health Services Vocational School, Afyonkarahisar Health Sciences University, Afyonkarahisar, Türkiye

²Department of Anatomy, Faculty of Medicine, Eskişehir Osmangazi University, Eskişehir, Türkiye

Objective: Autism spectrum disorder (ASD), a neurodevelopmental condition, primarily consists of social, communication, and sensory-related behavioral issues. The involvement of different brain regions such as the thalamus is also thought to be related to these problems. This study, in which a valproic acid (VPA)-induced ASD model was applied, aimed to demonstrate the changes in thalamus volume and cell number by stereological methods.

Methods: On gestation day 12.5, 10 pregnant rats were injected intraperitoneally with a single dose (600 mg/kg) of VPA (VPA group), and 5 rats were injected with 5 ml of saline (control group). ASD-like behavior of the male pups was assessed with three-compartment social interaction test and light-dark transition test. The VPA group that did not exhibit ASD-like behavior and the control group that exhibited ASD-like behavior were excluded from the study. The brains of the included subjects (10 VPA, 10 control) were removed on postnatal day 55. Sagittal sections of the brains were stained with toluidine blue and cresyl violet. Hemisphere and thalamus volumes, the ratio of these volumes to each other, and total cell, neuron, and non-neuron cell numbers in the thalamus were calculated by stereological methods. Data were statistically analyzed by t-test.

Results: Hemisphere volume was 23% higher, thalamus volume ~15%, and thalamus/brain volume ratio 48% lower in the VPA group compared to the control group. However, the total number of thalamic cells was ~21% lower, the total number of neurons was ~19% lower, and the total number of non-neuronal cells was ~27% lower in the VPA group.

Conclusion: This study emphasizes the role of the thalamus in the neuropathogenesis of ASD by demonstrating that the thalamus volume shrinks while the brain volume grows, that is, cortical and subcortical structures develop differently, and thalamic cell numbers decrease accordingly.

Keywords: autism spectrum disorders, valproic acid, behavioral test, thalamus, stereology

O111 - A different perspective on anatomy education: modelling and virtual reality

Eda Sağıroğlu¹, [Aya Aldashash](#)²

¹Department of Anatomy, Faculty of Medicine, Lokman Hekim University, Ankara, Türkiye

²Pi Health Technologies Sağlık Teknolojileri Limited Company, Ankara, Türkiye

Objective: Basic sciences education in medical school is evolving rapidly, with Virtual Reality (VR) visualization enhancing anatomy instruction. VR simplifies complex 3D structures, aiding comprehension and shifting from rote memorization to active engagement. This educational approach fosters a deeper understanding of anatomy, making learning efficient and enjoyable, saving time. This study's objective is to model vertebrae, generate visuals, and compare them to traditional anatomy atlases for educational use.

Methods: The 3D design process of the anatomical models was performed using Blender and Maya programs. After the modeled cervical, thoracic, lumbar vertebrae and sacrum bone were colored in the computer environment, they were transferred to the virtual reality environment using C# and Unity programs. Afterwards, these images were photographed and compared with the images in anatomy atlases.

Results: As a result of designing the anatomical models, images of 4 vertebrae from the cervical region, 2 vertebrae from the thoracic region, 1 vertebra from the lumbar region, sacrum and coccyx were taken and recorded. They were compared with the pictures in anatomy atlases. The details found and visualized in the basic structures on the anatomical models were marked to make the similarities and differences more apparent.

Conclusion: In the faculties of medicine and other basic medical sciences, dentistry, pharmacy, dentistry, pharmacy and vocational schools of health services, students should be integrated into an education model in which they will actively learn by eliminating anatomy education based on classical learning models. It is an indisputable fact that 3D digital models make great contributions to anatomy education. These digital models make complex and difficult subjects in theoretical education easy to understand and memorize. It is certain that education needs to be supported by VR in order for students to better comprehend subjects that are difficult to understand and imagine.

Keywords: virtual reality, anatomy, 3-dimension

O112 - Comparison of different radiology-based measurement programs in cerebellar volume analysis of individuals with Alzheimer's disease

Muhammed Emre Yüzer¹, Büşra Zencirci¹, Zümrüt Doğan¹

¹Department of Anatomy, Faculty of Medicine, Adiyaman University, Adiyaman, Türkiye

Objective: Alzheimer's disease (AD) causes neurodegenerative damage to the brain, leading to atrophy. MR imaging methods are frequently used for morphometric analysis of the disease. Although VolBrain and HOROS programs are frequently used in anatomical and radiological studies, they have differences in data transfer and measurement methods. In this study, VolBrain and HOROS programs were used in cerebellar volume measurements of people diagnosed with Alzheimer's disease and it was aimed to compare these programs in terms of interface, ease of use and compatibility of morphometric analysis.

Methods: All patients (50) were filtered from the records of individuals over 65 years of age diagnosed with AD who underwent brain MRI between 01/01/2000 - 01/01/2022 at the Department of Radiology, Adiyaman University Training and Research Hospital. Volumetric measurements were made on MRI using VolBrain and HOROS programs.

Results: As a result of the study; when the manual measurements were examined, the volumetric data measured with HOROS were found to be higher, albeit with a slight difference. However, no statistically significant difference was found when the measurements made with the two applications were compared ($p > 0.05$). When the Shapiro-Wilk normality test was performed, the value was found to be greater than 0.05, that is, normal.

Conclusion: In conclusion, both radiological imaging programs were useful for volumetric examination of anatomical structures. Although VolBrain MRI provides quantitative data online free of charge regardless of image quality, the disadvantage is that 2D and 3D reconstructions of anatomical structures cannot be examined in detail. HOROS, on the other hand, is more useful in 2D and 3D imaging, but being a MAC-based program and requiring good image quality for the accuracy of the analysis may reduce its usefulness in volumetric calculations. The researcher's data and software and hardware capabilities are important in the selection of these programs.

Keywords: Alzheimer, cerebellum, Horos, Volbrain

O113 - Application of patellar type and patella related measurements in chondromalacia patella classification

Nizameddin Fatih Karamus¹, Mehmet Zahit Gül², Firat Sustam², Mustafa Büyükmumcu³, Serdar Balsak⁴, Özge Pasin⁵

¹Department of Anatomy, Faculty of Medicine, Altinbas University, Istanbul, Türkiye

²Department of Physiotherapy and Rehabilitation, Faculty of Health Sciences, Bezmialem Vakif University, Istanbul, Türkiye

³Department of Anatomy, Faculty of Medicine, Bezmialem Vakif University, Istanbul, Türkiye

⁴Department of Radiology, Faculty of Medicine, Bezmialem Vakif University, Istanbul, Türkiye

⁵Department of Bioistatistics, Faculty of Medicine, Bezmialem Vakif University, Istanbul, Türkiye

Objective: Chondromalacia patella (CP) is a disease characterized by softening and degeneration of the patellar cartilage tissue, causing chronic anterior knee pain. The aim of this study was to determine the type of patella and the degree of CP in patients with CP and to correlate the results with morphological measurements of the knee joint.

Methods: Fifty-three patients, aged 18 to 65 years, who underwent routine knee MRI images and did not have any knee pathology other than CP were evaluated retrospectively. Baumgartle classification was used to determine patella types and morphological measurements included Insall-Salvati ratio (ISR), patella-patellar tendon angle (P-PTA), quadriceps-patella angle (Q-PA) and sagittal plane knee alignment.

Results: CP was first grade in 13.2%, second grade in 56.6%, third grade in 15.1% and fourth grade in 15.1% of cases. Type I patella was found in 32.1%, type II in 39.6% and type III in 28.3% of cases. The ISR value was 1.20 ± 0.17 , P-PTA $146.36 \pm 4.04^\circ$ and Q-PA $32.38 \pm 9.67^\circ$. No significant relationship was found between patella types and CP grades ($p=0.511$), but a significant relationship was found between CP grades and ISR ($p=0.022$), with patella alta occurring in individuals with fourth degree CP. No significant relationship was found between P-PTA ($p=0.775$) and Q-PA ($p=0.380$) values and CP grades.

Conclusion: It is important to identify the morphological changes that may occur in the knee joint during clinical follow-up of CP. The results suggest that the ISR may be a useful guide in the morphological evaluation of CP. Other knee joint pathologies that may affect knee mechanics should also be considered when evaluating the biomechanical effects of CP.

Keywords: chondromalacia, magnetic resonance imaging, patella

O114 - Am I a fraud? Evaluation of the prevalence of Imposter phenomenon among students receiving postgraduate education in the field of Anatomy in Turkey

Fatma Ok¹, Mehmet Yiğit¹, Aysin Çetiner Kale¹, Özcan Gayretli¹, Osman Coşkun¹

¹Department of Anatomy, Faculty of Medicine, Istanbul University, Istanbul, Türkiye

Objective: Imposter phenomenon was defined by Clance and colleagues in 1978 as an internal feeling of intellectual dishonesty and worthlessness. Individuals showing symptoms of this syndrome are characterized by anxiety, low self-esteem, hopelessness, and the feeling of not being able to meet one's own standards of success. There are no studies investigating the prevalence of this syndrome in students receiving postgraduate education in the field of anatomy in Turkey. This study revealed to what degree and frequency Imposter syndrome is seen among postgraduate students in the field of anatomy.

Methods: A web-based (Google form) survey was conducted among postgraduate students (master's, doctoral and medical specialization) in Turkey between February 1, 2023 and September 5, 2023. The survey was created by Clance in 1985 and is a one-way, 5-point Likert type (1: not at all true, 5: definitely) 20-question data collection tool that aims to measure people's tendencies towards the Imposter phenomenon. Of the 58 people who participated in the survey, 32 (55.1%) were men and 26 (44.8%) were women. The survey consisted of a gender questioning in addition to the Clance IP scale. Independent t test was used in the study.

Results: As a result of the survey, it was revealed that 31.03% of the participants showed limited Imposter phenomenon character, 36.2% experienced moderate Imposter phenomenon, 29.31% frequently experienced Imposter phenomenon and 3.44% experienced severe Imposter phenomenon. No statistical difference was observed between men and women ($p < 0.05$) who have an academic career in the field of anatomy.

Conclusion: The psychology of the instructor is extremely important when giving anatomy education. This study will draw attention to the existence of this phenomenon, which is frequently encountered but has never been mentioned in the academic life of anatomy.

Keywords: Imposter phenomenon, anatomy education, graduate education

O116 - Is the morphometry of the medially protruding part of os naviculare related to the medial longitudinal arch?

Turan Koç¹, Asena Ayça Özdemir², Zeliha Kurtoğlu Olgunus³, Alev Bobuş Örs³

¹Department of Anatomy, Faculty of Medicine, Kahramanmaraş Sütçü İmam University Kahramanmaraş, Türkiye

²Department of Medical Education, Mersin University, Mersin, Türkiye

³Department of Anatomy, Faculty of Medicine, Mersin University, Mersin, Türkiye

Objective: Pes planus is a common deformity with the collapse of the foot arch, which makes it difficult to perform daily activities such as walking and running. Although it has been suggested that this deformity is related to the morphometry of medial protrusion of navicular bone and the insertion of the tibialis posterior, which is the main muscle supporting the medial longitudinal arch (MLA), there is not sufficient evidence. This study aimed to reveal the relationships between the MLA, navicular bone and tibialis posterior tendon.

Methods: In our study, 34 cadaver feet (15 women, 19 men) (age 68.68 ± 12.81) in the inventory of Mersin University Anatomy Department were dissected. Attachment sites of the tibialis posterior tendon were revealed. Morphometric measurements of medial protrusion (width, length, lower part) were performed. The distribution areas of the tibialis posterior tendon were classified and connections with other muscles were mapped. To evaluate the MLA, pes planus was grouped via navicular index and the 1st Metatarsal-Calcanus angle and parameters between groups were evaluated.

Results: In all feet, the navicular bone extended medially from the determined reference line, but dimensions of the protruding part did not prevent distribution of the main tendon. Between normal and pes planus foot groups; No significant difference was detected in terms of its connections with the muscles, number of tendon extensions, and morphometry of the navicular bone. However, it is found that the cross-sectional area and thickness of tendon attached to the IV. metatarsal bone was higher in the pes planus groups.

Conclusion: We believe that involvement of the cornuate type accessory navicular bone, in which the medial protrusion part of the navicular bone is large, in the etiology of pes planus should be reconsidered and it should be aware that this mass may lead to an erroneous diagnosis of pes planus.

Keywords: tibialis posterior tendon, pes planus, morphometry, medial longitudinal arch

O118 - Development of temporal muscle in fetal period

Gizem Çizmeci¹, Mehmet Ali Malas¹, Selen Akyol Bahçeci²

¹Department of Anatomy, Faculty of Medicine, Izmir Kâtip Celebi University, Izmir, Türkiye

²Department of Histology and Embryology, Faculty of Medicine, Izmir Kâtip Celebi University, Izmir, Türkiye

Objective: Temporal muscle is a masticatory muscle that fills the temporal fossa. In our study, it was aimed to examine both macroscopic and microscopic development of temporal muscle in human fetuses according to gestational age.

Methods: Our study was carried out bilaterally on 20 human fetuses (13 Male, 7 Female). Fetuses with external anomalies were not included in our study. In our study, temporal muscle was examined in terms of general morphometric features and distance from adjacent anatomical landmarks. Then, histological sections were prepared from the samples harvested from temporal muscle, and representative fiber count per unit area, parenchyma/stroma ratio and mean muscle fiber diameter were examined on muscle cell microscopy from a stereological perspective.

Results: The general morphometric parameters of temporal muscle such as height, width and area and the distances of temporal muscle to the glabella, vertex and opisthocranium of the cranium increased with gestational age. The representative fiber count per unit area of muscle microscopy, the mean muscle fiber diameter, and the parenchyma/stroma ratio increased with gestational age. Both macroscopic and microscopic variables were strongly correlated with gestational age. No difference was found between the sides in all measurements ($p > 0.05$).

Conclusion: It is thought that the data obtained in our study regarding the development of the temporal muscle in the intrauterine period will lead to scientific studies to be conducted on masticatory muscles. In addition, it is hoped that it will help in the diagnosis and treatment applications to be made in the fields of obstetrics and perinatology in order to examine the development of the temporal muscle in the prenatal period.

Keywords: temporal muscle, fetal period, muscle development, human fetus, morphometry

O120 - Effect of various doses of metformin on map-kinase and apoptosis in penicillin-induced secondary rat cortical astrocytes- can metformin be antiepileptic?

Hülya Özdemir¹, Mehmet Bülent Özdemir²

¹Department of Anatomy, Faculty of Medicine, Uşak University, Uşak, Türkiye

²Department of Anatomy, Faculty of Medicine, Pamukkale University, Denizli, Türkiye

Objective: Astrocytes in the brain and spinal cord; they perform many functions such as the biochemical support of endothelial cells that make up the blood-brain barrier and the supply of nutrients to the nerve tissue, preservation of extracellular ion balance, and the process of repair and scarring of the brain and spinal cord after traumatic injuries. Astrocytes also express plasma membrane carriers, for various neurotransmitters, including glutamate, ATP and gamma aminobutyric acid (GABA). Often sclerotic areas in the hippocampus are known as the cause of epilepsy. In reality, astrocytes initiate glutamate release in sclerotic tissue. Glutamate excites neurons in the environment and seizure activity occurs. In experimental epilepsy, penicillin is widely used to initiate this neuronal stress and establish the epilepsy model. Hippocampal atrophy, neuronal cell loss and astrocyte cell proliferation have been demonstrated after epileptic seizures. In contrast, previous studies have shown that metformin can protect neuronal cells at appropriate concentrations. Aim of this study is to demonstrate the protective effect of metformin, which has been proven to be effective in neurodegenerative diseases, on penicillin-induced astrocyte degeneration on the primary astrocyte cell line. This study is thought as the first study about the effect of metformin on penicillin-induced astrocyte death.

Methods: For this purpose, secondary astrocyte cell culture which previously obtained from the newborn rat brain was used. Different concentrations of metformin (0.25, 0.5, 1, 2, 4 mM) were applied to in penicillin-free medium and 500-1000 IU penicillin-containing medium at the cell line.

Results: Penicillin significantly reduced the viability of the astrocyte cell. We conclude that metformin has protective effects on damage caused by penicillin secondary astrocyte cell line. Cell survival was strongly dependent on metformin concentrations.

Conclusion: The results of this study will contribute to the literature as an initial study on the use of metformin as an antiepileptic.

Keywords: astrocyte, penicillin, metformin, rat, cell culture

O121 - Penicillin dose dependant effect on primer astroglial cell line: It might be cell base epilepsy model

Mehmet Bülent Özdemir¹

¹Department of Anatomy, Faculty of Medicine, Pamukkale University, Denizli, Türkiye

Objective: This study was designed to define the effect of penicilline on astrocytic glial cell in terms of dose-response relationship between penicillin and astrocyte cell viability on primer astroglial cell line. Astrocytes secrete glutamate in a vesicular Ca²⁺ + dependent manner. Glutamate excitotoxicity is associated with neuronal stress and initiates epileptic seizures. Today, astrocytes have become prominent as the cause of epilepsy seizures. So, the aim of the study is to evaluate dose dependent penicilline induced astroglial cell degeneration in order to develop cell base epilepsy model.

Methods: For this purpose, newborn rat brain was extracted and then mechanically dissociated to astroglial cell suspension and finally grown in culture medium. Clusters were maintained for 2 weeks prior to being used in these experiments. Then, primer astroglial cell line were induced with PBS, 300, 500, 1000, 1500 and 2000 IU of penicillin- G. Cell viability in control group were accepted 100 percent.

Results: The dose of 1000, 1500 and 2000 IU of penicillin- G decreased the viability of astroglial cell seriously. The dose smaller than 1000 IU of penicillin- G had no effect on cell viability according to control group. We concluded that astroglial cell survival depends on concentrations of penicillin- G strongly and the effects were statistically significant when compared to the control group ($P < 0.009$).

Conclusion: Today, intensive studies are carried out for more powerful, precise and safe antiepileptic agents for epilepsy. Astroglial cell line induced with penicillin might be cell base epilepsy model and these results suggest that the appropriate dose of penicillin has to be selected for a given experimental epilepsy study in order to demonstrate the relevant epileptic seizure and its effects. 1000 IU penicillin-induced epilepsy model may be a good choice to practice studies that investigate neuroprotective mechanisms of the anti-epileptic drugs.

Keywords: astrocyte, penicillin, rat brain, cell culture, cell death, cell survival, epilepsy

O123 - Investigation of temporal fossa morphometry in dry skull bones

Mehmet Ali Malas¹, [Hatice Kübra Yeşil Aksoy¹](#)

¹Department of Anatomy, Faculty of Medicine, Kâtip Celebi University, Izmir, Türkiye

Objective: In our study, it was aimed to morphometrically examine the bone structures forming the borders of the temporal fossa (TF) in dry skull bones.

Methods: Our study was carried out on a total of 32 dry skull bones [23 bilaterally, 9 unilaterally (right:4, left:5)]. Totally 55 TF structures were studied. ImageJ program was used on digital images obtained from skulls and silicone molds taken from zygomatic orifices (ZO). Morphological features and different shape types of zygomatic arch (ZA), localization of pterion and marginal tubercle (MT), typing and morphometric parameters of ZO were determined.

Results: In ZA settlement; asymmetry was observed between the sides in the distance of the ZA posterior root to the MT and zygion. In ZA dimensions; asymmetry was observed between the sides in the height of the most posterior point of the ZA and the external angle of the zygoma. In ZA shape typing, 5 types were determined according to Frankfurt Horizontal Plane (FD): Type 1 (Flat), Type 2 (Ascending), Type 3 (Descending), Type 4 (Convex) and Type 5 (Concave). In the ZA localization type, 2 types were determined according to the FD: the type FD passes through ZA (Type A) and the type FD is above ZA (Type B). Asymmetry was observed in the placement of the MT relative to the anterior point of the porus. There was no asymmetry between the sides in ZO dimensions, but it was determined that the ZO shape type differed between cases and that it wasn't a standard type in terms of length and width index ratio, and ZO could be seen in different index sizes.

Conclusion: We hope that the morphological parameters determined in our study on the TF structures in dry skull bones will be useful in research studies, surgical interventions and medical applications in this region.

Keywords: temporal fossa, zygomatic arch, pterion, marginal tubercle, zygomatic orifice

O124 - Anatomical relationship of crista intersesamoidalis with first metatarsal axis and distal metatarsal joint angle in hallux valgus foot deformity

İsmail Türkten¹, Semih Ayanoğlu²

¹Department of Anatomy, Faculty of Medicine, İstanbul Medipol University, İstanbul, Türkiye

²Department of Orthopedics and Traumatology, Faculty of Medicine, Altınbaş University, İstanbul, Türkiye

Objective: The crista intersesamoidalis is important in the context of hallux valgus (HV) development as it stabilizes the sesamoids located on its edges. In HV surgery, the axis of the crista can change, but the direction of this change is not clear. This study aims to compare the crista angle between HV and control groups and also examine its relationship with the distal metatarsal angle (DMAA).

Methods: A total of 107 different feet (56 HV, 51 control) were used for this study. CT and radiographic images were examined retrospectively. HV groups were determined based on the measurement of hallux valgus angles from radiographs: mild (15° - 20°), moderate (21° - 39°), severe ($\geq 40^{\circ}$). 3D surface models of the first metatarsal (1MT) were created, and the angle between the crista and the long axis of 1MT (crista angle) was determined. Additionally, 3D-DMAA measurements were taken. 3D-Slicer and Ansys software were used for analyses.

Results: The average Crista angle was 15.5° (± 8.5) in the HV group and 4.3° (± 3.2) in the control group, and the difference was statistically significant ($p < 0.05$). The average DMAA in the HV group was 13.6° (± 4.9), while in the control group, it was 4.3° (± 2.6), and this difference was also statistically significant ($p < 0.05$). An average correlation was found between crista angle and DMAA ($p < 0.05$). Particularly in the severe group, both crista angle and DMAA were higher compared to the other groups.

Conclusion: There is a significant positive correlation between crista angle and DMAA, and both are significantly higher in the HV group compared to the control group. The correction of DMAA in HV cases, depending on the surgical technique applied (such as distal metatarsal osteotomy), implies the correction of the crista angle as well.

Keywords: crista angle, distal metatarsal articular angle, distal metatarsal osteotomy, hallux valgus, metatarsosesamoid joint

O125 - Investigation of the effectiveness of atmospheric pressure cold plasma on sciatic nerve injury in rats

Nesibe Yılmaz¹, Ömür Gülsüm Deniz², Şeyda Seçgin³, Yusuf Secgin¹, Ferhat Bozduman⁴

¹Department of Anatomy, Faculty of Medicine, Karabük University, Karabük, Türkiye

²Department of Histology and Embryology, Faculty of Medicine, Bolu Abant İzzet Baysal University, Bolu, Türkiye

³Department of Medical Biochemistry, Faculty of Medicine, Karabük University, Karabük, Türkiye

⁴Department of Biophysics, Faculty of Medicine, Karabük University, Karabük, Türkiye

Objective: Under 1 atm pressure and 1000K temperature, the plasma obtained by ionization of various gases is called atmospheric pressure cold plasma jet. Plasma activated medium (PAM) is obtained by introducing the jet into distilled water. Plasma is used in the medical field for wound healing, tissue regeneration and anticancer activity. The aim of this study was to investigate the effectiveness of atmospheric pressure cold plasma on sciatic nerve injury (SNI) in rats.

Methods: In the study, 60 female rats weighing 250-300 g were used. The rats were divided into six groups (n=10) as group 1 (Control), group 2 (SNI), group 3 (SNI +Jet 5 min), group 4 (SNI+Jet 10 min), group 5 (SNI+Pam 5 min), group 6 (SNI+Pam 10 min). Plasma was administered to rats in groups 3, 4, 5 and 6 on the 1st, 8th, 15th and 22nd days of the study. Hot plate test was performed in all groups on the same day after the treatments and the scores were recorded.

Results: According to the mean of hot plate tests, a significant difference was found between the 1-2, 1-3, 1-4, 1-5, 1-6, 2-4, 2-5, 2-6 groups ($p<0.05$). When evaluated within each week, a significant difference was found between 1-2, 1-3, 1-5, 1-6, 2-4 groups in week 1, between 1-2, 1-3, 1-4, 1-5, 1-6, 2-5, 2-6 groups in week 2, between 1-2, 1-3, 1-5, 2-4, 3-4, 4-5 groups in week 3, between 1-2, 1-3, 2-4, 2-6 groups in week 4 ($p<0.05$).

Conclusion: As a result of the study, improvement was found in the atmospheric pressure cold plasma jet 10 min, PAM 5 min and 10 min groups compared to the sciatic injury group. We believe that our study will guide sciatic injury treatment studies, protocols and clinical applications.

*This study was supported by Karabük University scientific research projects coordination with project number KBÜBAP-23-DS-049.

Keywords: atmospheric pressure cold plasma jet, plasma activated media, sciatic injury, rats

O126 - Investigating the effects of trigeminal impression and internal acoustic opening morphology differences for possible surgical applications

Ayhan Comert¹, Ihsan Dogan², Niyem Pelin Cavdar Yilmaz¹, Yigit Gungor¹

¹Department of Anatomy, Faculty of Medicine, Ankara University, Ankara, Turkey

²Department of Neurosurgery, Faculty of Medicine, Ankara University, Ankara, Turkey

Objective: The exhaustive information regarding the types of trigeminal pore (TP) or trigeminal impression (TI), internal acoustic opening (IAO) and related surgical approach is lacking in the literature. Therefore, this study is performed to elucidate further the types of TP or TI, IAO and the relationships with critical surgical landmarks in the skull base.

Methods: TI and IAO found in 11 dry skulls, 24 right temporal bones and 25 left temporal bones were examined on both sides to define their relationship to each other and to nearby structures. Age and sex of these bones were not identified. Besides these, 77 skulls were examined by radiological imaging methods. These skulls were identified by gender.

Results: According to test results, there was a significant difference between left and right internal acoustic opening in case of horizontal dimension (HD). The left HD-IAO is bigger than the right one. In addition, right -HD-IAO, vertical dimension (VD) of right internal acoustic opening, left HD-IAO, left VD-IAO, values differed significantly in male and female patients.

Conclusion: Investigating the relationship of TI and IAO with relevant structures suggest that surgical approaches involving the TP and IAO indicated that surgical approaches considering the TI and IAO variations may be used in the development of surgical processes and primary surgical interventions.

Keywords: trigeminal pore, trigeminal impression, internal acoustic opening, jugular foramen, superior petrosal sinus

O128 - Radiographic analysis of spinopelvic alignment anatomy in scoliosis patients

Ozden Bedre Duygu¹, Figen Govsa Gokmen²

¹Department of Anatomy, Faculty of Medicine, Izmir Bakircay University, Izmir, Türkiye

²Department of Anatomy, Faculty of Medicine, Ege University, Izmir, Türkiye

Objective: Spinopelvic balance disorder is observed in scoliosis patients. There are no sufficient studies evaluating sagittal spinopelvic alignment in Anatolian human population. In our study, it is aimed to evaluate the sagittal alignment of the pelvis and spine in scoliosis patients.

Methods: Radiological images of 100 scoliosis patients between the ages of 5-20 who were treated at Ege University Hospital Orthopedics and Traumatology Clinics were evaluated in this study. 9 measurements were made on the sagittal plane using the ImageJ program. These measurements; thoracic kyphosis angle (TKA), lumbar lordosis angle (LLA), pelvic incidence angle (PIA), pelvic tilt angle (PTA), sacral slope angle (SSLA), spinosacral angle (SSA), C7 tilt angle (C7-TA), sagittal vertical axis length (SVL) and odontoid process-hip axis angle (OPHA).

Results: The average age of female patients participating in our study was 13.42, and average age of male patients was 13.04. The average scoliosis degree of female and male patients participating in our study was 19.3 and 15.16, respectively. Pelvic incidence angle, pelvic tilt angle, sacral slope angle and spinosacral angle values in woman were found to be statistically significantly higher than in men ($p < 0.05$). Pelvic incidence angle, pelvic tilt angle, sacral slope angle, spinosacral angle and odontoid process-hip axis angle values were found statistically significantly lower in the patient group with low scoliosis degree ($p < 0.05$). Between the lumbar lordosis angle and thoracic kyphosis angle, pelvic incidence angle, spinosacral angle, C7 tilt angle, moderately positive relationship was detected. A moderate positive relationship was found between spinopelvic alignment parameters and the patients' scoliosis degrees.

Conclusion: PIA, PTA, SSLA, SSA and OPHA values which are easily measured in the orthopedics or physical therapy clinic, may be a predictor of vertebral column deformity in patients. We suppose that this study will contribute significantly in the follow-up of scoliosis patients and surgical planning.

Keywords: scoliosis, spinopelvic alignment, radiography

O130 - A situs inversus totalis case and an anatomical review of the situs anomalies

Çağatay Erşan¹, Ali Enes Aldur², Zeynep Yılmaz², Ayşegül Fırat²

¹Department of Radiology, Faculty of Medicine, Hacettepe University Ankara, Türkiye

²Department of Anatomy, Faculty of Medicine, Hacettepe University Ankara, Türkiye

Objective: Situs Inversus is a congenital anomaly that was first described by Aristotle in animals. Fabricius was first demonstrated transposition of the liver and spleen in humans in 1600. Transposition of the organs is established in fetal life and more than 100 genes have been responsible for such disorders. Being a rare condition, clinicians usually do not have much experience with this abnormality. In addition, situs inversus is an asymptomatic condition and in symptomatic cases, diagnosis may be difficult for the reversed location of symptoms and organs. Clinically this abnormality causes diagnostic and therapeutic difficulties.

Case: In this presentation, we want to evaluate a 46 years old male patient with chronic liver disease and review the clinical and surgical importance of the situs anomalies in the literature. Our patient was diagnosed as a situs inversus totalis case with asplenia when an abdominal magnetic resonance imaging was performed for portal vein occlusion.

Conclusion: Epidemiologically there are only a few studies in the literature and the incidence is reported as 1/10.000 and it is seen more frequent in male (1,5/1). Abdominal ultrasound imaging and thoraco-abdominal magnetic resonance imaging were best diagnostic methods for evaluation of the solid organs especially for the anatomical details. Traditional and advanced medical imaging modalities can be used for visualizing the details of situs inversus cases and is essential before any further medical intervention and diagnosis of such patients.

Keywords: situs inversus, situs inversus totalis, magnetic resonance imaging, asplenia

O131 - Radiological investigation of development of the knee joint in fetal period

Nazlı Ateş¹, Mehmet Ali Malas¹, Sevgi Ünal²

¹Department of Anatomy, Faculty of Medicine, İzmir Katip Çelebi University, İzmir, Türkiye

²Department of Radiology, Atatürk Training and Research Hospital, İzmir Katip Çelebi University, İzmir, Türkiye

Objective: Evaluation of the development of the epiphyses in the knee joint (KJ) region and the bones forming the joint surfaces during the fetal period is used in fetal age estimation, forensic medicine and obstetrics. Our study aimed to evaluate the development of the KJ region in human fetuses using radiological methods.

Methods: In our study, the KJ was investigated bilaterally in 20 dead human fetuses aged 12-38 weeks of gestation. Radiologic images of the lower limbs of the fetuses were taken with a digital mammography device. After providing calibration on radiological images, measurements in the KJ region were taken in the Image J program. These measurements are; the measurements of the bones forming the KJ, the distance between the femur and the tibia, and the measurements of the epiphyses in the KJ region.

Results: Morphometric measurements were taken from femur, tibia which are the bones forming the surfaces of the KJ, and the fibula. Depth measurements of the distal femur and proximal tibia were obtained, and it was observed that all parameters increased with the gestational age. No statistically significant difference was found between the right and left sides of the fetuses ($p>0.05$). All morphometric parameters are strongly correlated with each other. In our study, bilateral distal femoral epiphyses measurements in 3 fetuses aged 28, 32 and 38 weeks, and proximal tibial epiphyses measurements in a 38 week fetus were obtained as transverse and sagittal parameters.

Conclusion: We hope that the information obtained in our study will contribute to the evaluation of the KJ development of fetuses in the prenatal period, the determination of fetal anomalies and pathologies related to the lower limbs and especially the KJ, and the clinical evaluations and definitions to be made in perinatology, obstetrics, forensic medicine and obstetric radiology.

Keywords: knee joint, femur, tibia, fetus, fetal development

O132 - Morphology and typing of the auriculotemporal nerve

Gülden Kayan¹, Deniz Uzmanse¹, Turan Koç², Ali Türker Çiftçi³, Nail Can Öztürk¹

¹Department of Anatomy, Faculty of Medicine, Mersin University, Mersin, Türkiye

²Department of Anatomy, Faculty of Medicine, Kahramanmaraş Sütçü İmam University, Kahramanmaraş, Türkiye

³Department of Biostatistics and Medical Informatics, Faculty of Medicine, Niğde Ömer Halisdemir University, Niğde, Türkiye

Objective: Auriculotemporal nerve (AN), located in infratemporal fossa and arising from mandibular nerve, is an important sensory nerve. It is in close proximity to maxillary (MA) and middle meningeal (MMA) arteries. In cases of trauma, neuralgia has been reported to occur in form of seizures and is characterized by piercing pain, mostly over the temporal region. Knowing the morphometry of AN, its formation pattern and its status in relation to surrounding structures. It is important in terms of trauma, regional surgery and anesthesia. Our study aimed to reveal the morphometry, formation pattern, relationship vascular structures and position of the AN.

Methods: Bilateral infratemporal fossa (IF) dissections were performed on 15 adult cadavers (age 76.07 ± 14.1 years) and 15 fetuses (23.87 ± 3.40 weeks) in the inventory of Mersin University Anatomy Department. Number of roots forming the AN, their morphometry and its neighborhood with vascular structures were recorded. Typing was done by considering three parameters: number of roots forming the AN, connection configuration between the roots and the neighborhood relationship of roots forming the nerve with MA and MMA.

Results: Typing was done by determining that the AN exhibited different arterial relations with various roots and connection combinations in all materials. While number of roots forming the AN was observed to be a maximum of 5 in adult cadavers, it was be 4 in fetuses. Having 2 roots (60%) was the most common pattern in both materials. It was determined that the first root was lateral to the MMA in 87% of adult cadavers and 90% of fetuses, and the second root was medial in 81% and 79% of cases, respectively.

Conclusion: Understanding of characteristic structure of the AN is necessary for applications to be performed in IF. Elucidating this diversity, especially through dissection studies, will contribute to invasive procedures in the region.

Keywords: auriculotemporal nerve, infratemporal fossa, middle meningeal artery, morphometry

O134 - Treatment of rat uteruses with iloprost in experimental ischemia and reperfusion injury

Zümrüt Doğan¹, Ebru Annaç², Seda Çetin¹, Talip Karaçor³

¹Department of Anatomy, School of Medicine, Adiyaman University, Adiyaman, Türkiye

²Department of Histology and Embryology, School of Medicine, Adiyaman University, Adiyaman, Türkiye

³Department of Obstetrics and Gynecology, School of Medicine, Adiyaman University, Adiyaman, Türkiye

Objective: Ischemia-reperfusion injury (IRI) is defined as damage to the tissue that occurs when reoxygenation begins after a certain period of time as a result of decreased blood flow and inability to meet tissue oxygen needs. IRI damage is a process that causes serious tissue changes and plays an important role in organ transplantation. The uterus is the last organ removed during organ donation prolongs the ischemic process and reduces the survival rate of the transplanted uterus. Additionally, transient ischemia of the uterus is frequently encountered condition in the clinic. The aim of the study is to determine the effects of iloprost on IRI-induced tissue damage in the uterus.

Methods: 32 10-week-old, 280–300 g female Sprague Dawley rats; we divided it into four groups: Sham, ischemia, I/R, I/R + iloprost. Ischemia; was exposed to ischemia for 3 h. I/R; 3 h of ischemia + 3 h of reperfusion was applied. I/R + iloprost; 3 h ischemia + 3 h reperfusion + intravenous (IV) iloprost infusion was administered for 60 minutes from the beginning of reperfusion. Biochemical and histomorphological evaluations were performed on uterine tissue.

Results: Histomorphological examination; inflammation and vascular occlusion were observed level high in ischemia group, moderate in I/R group. No inflammation or vascular occlusion was observed in the Sham and I/R+ iloprost groups. There was epithelium and gland degeneration level high in ischemia group and moderate in I/R group. Among all groups, hemorrhage was observed only in the I/R + iloprost group. GSH level was significantly decreased in the I/R group. MDA level was significantly higher in the ischemia group.

Conclusion: We believe that has therapeutic and damage-preventing effect of iloprost against tissue damage that may occur due to IR in organ transplantation and uterine surgery. The results of this study can contribute to the literature and clinical.

Keywords: ischemia, reperfusion, iloprost, uterus, rat

O135 - Is there a brain asymmetry difference in unilateral temporal lobe epilepsy patients?

Edibe Bilişli Kara¹, Zeynep Fırat², Aziz Uluğ³, Gazanfer Ekinci², Ümit Süleyman Şehirli⁴

¹Department of Anatomy, Faculty of Medicine, Yeditepe University, Istanbul, Türkiye

²Department of Anatomy, Faculty of Medicine, Yeditepe University, Istanbul, Türkiye

³CorTechsh Labs, San Diego, CA, USA

⁴Department of Anatomy, Faculty of Medicine, Marmara University, Istanbul, Türkiye

Objective: Temporal lobe epilepsy (TLE) with mesial temporal atrophy accompanying hippocampal sclerosis (HS) is the most seen focal epilepsy type. Hemispheric asymmetry is a feature of brain organization in both invertebrates and vertebrates and is a key for some neurodegenerative diseases. Recently cortical and subcortical asymmetries have been reported based on cranial MRIs. In this context, we aimed to investigate the volumetric asymmetry difference in cerebral structures between TLE patients and healthy controls (HC), based on MRI data that may be new biomarkers for TLE cases.

Methods: In this retrospective study the cranial MRIs of fourteen clinically manifesting, radiologically HS-identified, and diagnosed TLE and fourteen HCs were collected from Yeditepe University Hospital, Radiology Department. Volume measurements and asymmetry index (AI) calculations in the total brain, hippocampus, temporal lobe, amygdala, thalamus, nucleus accumbens, premotor cortex, primary and somatosensory cortices were executed with medical NeuroQuant software. A negative AI represents asymmetry towards the right with reduced left side volume; positive AI represents asymmetry towards the left with reduced right side volume. Subsequently, differences in volume and asymmetric patterns were investigated among TLE subgroups (right and left-sided seizure focus TLE, RTLE: LTLE) and the HCs.

Results: Compared to the HCs, the LTLE patients showed significant bilateral total brain volume reduction. Also, considerable ipsilateral volumetric declines were detected in the nucleus accumbens with remarkable asymmetry to the right side, the premotor cortex, and the temporal lobe. No significant changes were detected in RTLE patients compared to the HCs or LTLE.

Conclusion: Overall, findings suggest that TLE patients had volumetric alterations with symmetry changes beyond the mesial temporal structures. With further investigations, the AI values can provide additional knowledge into TLE diagnosis.

Keywords: brain asymmetry, temporal lobe epilepsy, asymmetry index, nucleus accumbens

O138 - Pronator quadratus musculo-osseous free flap for wide hard palatal defect reconstruction: An anatomical study

Murat Igde¹, Necati Salman², Yigit Gungor², Mehmet Yilmaz², Ela Comert³, Murat Enes Saglam⁴, Yigit Baykara⁵, Ayhan Comert²

¹Plastic and Reconstructive Surgery Clinic, Ankara City Hospital, Health Sciences University, Ankara, Türkiye

²Department of Anatomy, School of Medicine, Ankara University, Ankara, Türkiye

³Department of Otolaryngology, School of Medicine, Kirikkale University, Kirikkale, Türkiye

⁴Department of Plastic Reconstructive and Aesthetic Surgery, Ankara City Hospital, Yildirim Beyazit University, Ankara, Türkiye

⁵Department of Pathology and Laboratory Medicine, Brown University, Providence, RI, USA

Objective: Wide hard palate defects include congenital and acquired defects that are six square centimeters or larger in size. Obturator prostheses and autologous soft tissue transfers have been used to reconstruct palatal defects. This study aims to repair wide, hard palatal defects by using a pronator quadratus musculo-osseous free flap to achieve subtotal reconstruction.

Methods: Seventeen formalin-fixed cadavers were dissected. Free musculo-osseous pronator quadratus flaps were prepared after a 12 cm curvilinear volar skin incision. Standard 30 × 23 mm (690 ± 52.12 mm²) hard palate defects were made by chisels and saws. A subcutaneous tunnel was created between the mandibular edge cross point of the facial vessels and the retromolar trigone through the subcutaneous to the superficial musculoaponeurotic system by dissection. Area measurements of the pedicle and palate defects were performed by the ImageJ program (National Institutes of Health, Bethesda, MD, USA) on drawings over an acetate layer of materials.

Results: Mandibular distances of gonion-facial vessel cross point (a), gonion-gnathion (m), and facial vessels' cross point-retromolar entrance point (h) were measured. Ratios of h/m and a/m were calculated. The mean pronator quadratus area was 2349.39 ± 444.05 mm², and the arterial pedicle pronator quadratus diameter was 2.32 ± 0.34 mm. The mean pedicle length of the pronator quadratus was 117.13 ± 8.10 mm.

Conclusion: Study results showed that musculo-osseous pronator quadratus flaps' bone and muscle parts perfectly fit on the defects in all cadavers. Pronator quadratus musculo-osseous flap is a feasible surgical option for wide, hard palatal defect reconstruction strategies.

Keywords: hard palate reconstruction, pronator quadratus, cadaveric study, anatomy

O142 - Evaluation of the ankle and foot in MR images of patients with knee osteoarthritis

Ümmühan Yağmurkaya¹, Banu Ordahan², Ülkü Kerimoğlu³, Duygu Akın Saygın⁴, İsmihan İlknur Uysal⁴

¹Department of Anatomy, Faculty of Medicine, Ankara Medipol University, Ankara, Türkiye

²Department of Physical Therapy and Rehabilitation, Faculty of Medicine, Department of Physical Therapy and Rehabilitation, Konya, Türkiye

³Department of Radiology, Faculty of Medicine, Necmettin Erbakan University, Konya, Türkiye

⁴Department of Anatomy, Faculty of Medicine, Necmettin Erbakan University, Konya, Türkiye

Objective: Knee osteoarthritis (KOA) can cause degenerative changes in the knee joint and also affects the mechanical adaptation, function and posture of the foot. This study aimed to draw attention to possible foot deformities in patients with KOA who have no complaints about the ankle or foot.

Methods: 101 patients between the ages of 40-69, who were diagnosed with KOA and did not have complaints about ankle and foot joints, who applied to the Physical therapy and rehabilitation clinic with complaints of knee pain, were included in the study. MR images of 84 patients (62 women, 22 men) could be obtained for various reasons. The postures of the feet were determined according to the foot posture index obtained during clinical examination. Tendon cross-sectional areas of the muscles crossing the ankle and plantar heel thickness (PHT) were measured on MR images. Images results reported by the radiologist were evaluated.

Results: Patients with KOA mostly had neutral foot posture (right 71%; left 74%). The average PHT was 1.78 cm bilaterally. The ratio of the tendon cross-sectional areas of the muscles effective in supination (S) to the tendon cross-sectional areas of the muscles effective in pronation (P) (S/P) was largest in the pronated feet and smallest in the supinated feet (1.76 cm²; 1.28 cm²). MRI reports detected edema (45%), tenosynovitis (36%), tarsal coalition (29%), epine calcanei (27%), degenerations of the ligaments (25%), cysts (16%) and sinus tarsi syndrome (8%).

Conclusion: Although patients with KOA have neutral foot posture, it was observed that degenerations in the feet and ankles accompanied the event. Evaluating the foot complex before determining the KOA treatment protocol will ensure that the problems that may occur in the foot are minimized and an effective treatment option is offered.

Keywords: knee osteoarthritis, magnetic resonance imaging, tendon cross-sectional areas, plantar heel thickness

O144 - Morphometric study of fibular notch

Damla Şahin¹, Ebru Yolaçan¹, Necdet Kocabıyık¹

¹Department of Anatomy, Gülhane Faculty of Medicine, University of Health Sciences, Ankara, Türkiye

Objective: The distal tibiofibular joint is considered a syndesmosis type joint. This joint is a complex structure consisting of anterior, interosseous and posterior ligaments. The aim of this study is to compare the morphometric characteristics of this joint in the Turkish population with other populations and to contribute to the literature.

Methods: This study was performed on 62 tibia bones in the inventory of the Anatomy Laboratory of Gülhane Medical Faculty, University of Health Sciences. 17 tibia bones were excluded from the study. The width, depth, height, anterior and posterior facet lengths of the fibular notch and tibia lengths of 45 tibia (20 right, 25 left) were measured. Measurements were performed with digital calipers. Mean, minimum and maximum values were obtained. Statistics were performed with Jamovi version 2.4.8 software.

Results: The mean height of the fibular notch was 36.48 ± 4.06 mm, depth 4.47 ± 1.13 mm and width 23.30 ± 3.05 mm. The anterior facet length was 11.03 ± 1.44 mm and the posterior facet length was 14.40 ± 1.74 mm. The mean height of the tibial length was 350.50 ± 25.60 mm. The relationship between tibia length and fibular notch height, anterior facet length, posterior facet length and fibular notch width was statistically significant, but there was no statistically significant relationship between tibia length and fibular notch depth. For the right and left leg, the relationship between height, width, depth, anterior and posterior facet lengths did not differ statistically.

Conclusion: Fractures and fracture dislocations of the distal tibiofibular joint are common clinical pathologies. We believe that the data revealed in our study regarding incisura fibularis morphometry will guide radiologists in detecting the distal joint between the tibia and fibula in radiological imaging and will guide surgeons in the operations of this region.

Keywords: fibular notch, tibia, tibiofibular syndesmosis

O146 - The vascular supply of the lateral compartment of the leg with emphasis on fibular graft harvesting

Nihal Apaydin^{1,2,3,4}, Aybegum Balci¹, Marios Loukas⁵, Richard S. Tubbs⁶, Simel Kendir¹

¹Department of Anatomy, School of Medicine, Ankara University, Ankara, Türkiye

²Department of Multidisciplinary Neuroscience, Institute of Health Sciences, Ankara University, Ankara, Türkiye

³Brain Research Center (AU-BAUM), Ankara University, Ankara, Türkiye

⁴Neuroscience and Neurotechnology Center of Excellence (NÖROM), Ankara, Türkiye

⁵Department of Anatomical Sciences, St. George's University, Grenada, West Indies

⁶Neurosurgery, Neurology, and Structural & Cellular Biology, Tulane University, LA

Objective: Necrosis of the fibularis longus (FL) and brevis (FB) muscles after fibular osteocutaneous flap harvest or graft is a common problem experienced in orthopedic reconstructive surgeries. FL and FB are known to be supplied primarily by anterior tibial artery (ATA) and the fibular artery (FA). However, the literature on these vascular pedicles doesn't provide details on their exact location, sources, or branching patterns. The aim of this study is to determine the exact localization of vascular pedicles which supply the FL and FB, to identify the morphometric features of these vessels on the lateral compartment of the leg and, to indicate the branching points of these pedicles from main arteries.

Methods: The popliteal artery of the 40 lower extremities of 20 adult cadavers (12 male, 8 female) were filled with colored latex injection bilaterally. Following dissection, distances between branching points of pedicles coming from ATA, FA, and posterior tibial artery (PTA) and, the apex of the head of the fibula that run to the FL and FB were measured.

Results: The FL and FB were supplied by pedicles branching from FA, ATA and PTA. In all cases, a single artery branching from ATA and supplied the fibular muscles was identified. The distance between origin of this artery and the apex of fibular head was on average 8.65cm. The mean length and number of branches of this artery was 10.9 cm and 4.7 respectively. In all specimens, the FA supplied the proximal and distal portions of the posterior aspect of the fibular muscles.

Conclusion: In this study for the first time, morphometric features are detailed described for branch of ATA which gives branches to FL and FB. We suggest denominating this artery as "lateral fibular artery". Conservation of this branch is imperative in order to preserve blood supply to fibularis muscles during operations in this region.

Keywords: anterior tibial artery, lateral fibular artery, fibular graft, fibularis longus muscle, fibularis brevis muscle

O147 - A rare anomaly noticed during coronary angiography intervention: Coiled common iliac artery

Ersin Doğanözü¹, Pınar Demir Gündoğmuş², Burcu Erçakmak Güneş²

¹Department of Cardiology, ²⁹ Mayıs State Hospital, Ankara, Türkiye

²Department of Anatomy, Faculty of Medicine, Hacettepe University, Ankara, Türkiye

Objective: The common iliac artery is a large terminal branch of the abdominal aorta. During the coronary angiography usually prefer femoral artery access that continued with common iliac artery. Although its anomalies were extremely rare it can be result with complications while perform a coronary angiography if there is an anomaly. In this case we want show the common iliac artery anomaly in an angiographic view.

Case: A 86 years woman with non-ST segment elevation myocardial infarction performed conventional coronary angiography. Also, she had hypertension and coronary artery disease at the same time. During the entrance into the femoral artery, the guidewire was obstructed after about 15 cm passed the artery. We performed a cineangiography and saw the iliac artery coiling. We used a 6F Judkins right catheter to pass the iliac artery. After obtained the coronary angiographic saw there was a left anterior descending artery (LAD) occlusion. For coronary stenting the LAD we had to do reshape to extra back-up guiding catheter for access the common iliac artery. By this way we completed the intervention successfully.

Conclusion: The common iliac artery anomalies are extremely rare but if needed an artery intervention it can be a hardly manageable problem. We suggest, the clinicians must be careful before the artery intervention not to cause a big artery complication such as dissection, rupture etc. Even in situations that doesn't need intervention it should be taken into consideration that the common iliac artery anomalies can cause some arterial complications such as embolic disorders.

Keywords: common iliac artery, arterial coiling, angiography

O155 - A rare case: Persistent primitive olfactory artery

Ersel Ziyilan¹, Rukiye Öncel², Yeşim Eroğlu¹, Hasan Barış Ilgaz²

¹Department of Radiology, Faculty of Medicine, Firat University, Elazığ, Türkiye

²Department of Anatomy, Faculty of Medicine, Hacettepe University, Ankara, Türkiye

Objective: Persistent primitive olfactory artery (PPOA) is a rare variant of the anterior cerebral artery (ACA). It is suggested that it is prone to cerebral aneurysms due to its sharp hairpin-like rotation. Therefore, it is clinically important. Embryologically, PPOA arises from the rostral portion of the primitive internal carotid artery. Thanks to its high resolution, computed tomography (CT) angiography is the preferred imaging method in the evaluation of vascular structures. In this report, we presented a case of PPOA that was diagnosed incidentally with the help of computed tomography (CT) angiography.

Case: The 74-year-old male patient, who complained of double vision, had additional diseases such as hypertension, diabetes, and ischemic heart disease. On physical examination, there was a limitation in outward vision in the left eye. Cerebral CT angiography performed to exclude cranial pathologies revealed an arterial structure compatible with PPOA originating from the A1 branch of the right anterior cerebral artery and extending anteriorly towards the olfactory bulb.

Conclusion: Persistent primitive olfactory artery is a relatively rare variation of ACA. Its prevalence is reported as 0.14%. Although it is mostly detected incidentally, anosmia may occur. In addition, since saccular aneurysms can be seen at the sharp turn site, it is important to diagnose and follow up with these patients for the development of aneurysms. Rare vascular variations should be kept in mind when evaluating cerebral radiological images. CT angiography is useful in diagnosing these rare vascular anomalies and monitoring possible complications.

Keywords: olfactory artery, persistent, angiography

O157 - The relationship between cortical thickness and facial recognition performance in Parkinson's Disease

Necati Emre Şahin¹, Bünyamin Şahin², Zülal Öner³, Gülhan Ertan Akan⁴

¹Department of Anatomy, Faculty of Medicine, Karabük University, Karabük, Türkiye

²Department of Anatomy, Faculty of Medicine, Ondokuz Mayıs University, Samsun, Türkiye

³Department of Anatomy, Faculty of Medicine, İzmir Bakırçay University, İzmir, Türkiye

⁴Department of Radiology, Faculty of Medicine, İstanbul Medipol University, İstanbul, Türkiye

Objective: This study aims to investigate the relationship between cortical thickness and facial recognition performance in individuals with Parkinson's Disease (PD).

Methods: A total of 56 Parkinson's patients and 24 healthy control (HC) participants were selected for the study. Parkinson's patients were categorized into three subgroups based on neurological examination and neuropsychological assessment: Parkinson's patients without cognitive impairment (PD-NC), Parkinson's patients with mild cognitive impairment (PD-MCI), and Parkinson's patients with dementia (PDD). Mini-Mental State Examination (MMSE) and Benton Facial Recognition Test (BFRT) were used for visual perceptual assessment of all participants. Structural MRI images were obtained using a 3 Tesla MRI scanner. FreeSurfer software was used for cortical thickness analysis. Statistical analyses included One-Way ANOVA, Kruskal-Wallis test, and Pearson chi-square test.

Results: Significant differences were observed among groups in terms of age, gender, MMSE score, and BFRT score ($p < 0.05$). Cortical thinning was observed in the right parsorbitalis region in the PD-MCI group. In the PDD group, cortical thinning was observed in the left hemisphere in the superior temporal, middle temporal, superior frontal, and fusiform gyrus, and in the right hemisphere in banks of the superior temporal sulcus (bankssts), temporal pole, postcentral gyrus, and inferior parietal lobulus. BFRT score correlations revealed negative associations in HC's left lateral occipital, PD-NC's left lingual, PD-MCI's left superior parietal, and right precentral regions, and positive associations in PDD's left and right precuneus, and right precentral regions ($p < 0.05$).

Conclusion: Cortical thickness is linked to facial recognition in Parkinson's Disease. Cortical thinning may impair facial recognition and serve as a cognitive marker. Further research is needed for mechanistic insights and new Parkinson's Disease treatments.

Keywords: Parkinson's disease, cortical thickness, facial recognition performance, cognitive impairment

O165 - The relationship between sternum ossification process and age with gender: A retrospective computed tomography study

Menşure Şahin¹, Necati Emre Şahin², Serkan Öner³, Şeyma Toy², Zülal Öner⁴

¹Department of Medical Services, Forensic Assistance Program, School of Health Services, Karabük University, Karabük, Türkiye

²Department of Anatomy, Faculty of Medicine, Karabük University, Karabük, Türkiye

³Department of Radiology, Faculty of Medicine, İzmir Bakırçay University, İzmir, Türkiye

⁴Department of Anatomy, Faculty of Medicine, İzmir Bakırçay University, İzmir, Türkiye

Objective: The aim of this study was to evaluate the relationship between the ossification of the sternum parts and the fusion processes of their segments with gender and to determine the cut-off values of these parameters according to age.

Methods: In this study, the thorax computed tomography images of 480 individuals, including 215 females and 265 males aged 0-25 years, were retrospectively analyzed. The number of ossification centers in the manubrium, body, and xiphoid process parts of the sternum was determined. Ashley's classification was applied to the ossification centers in the body part. The ossification and fusion of sternum segments of the participants were evaluated. ROC analysis was performed to determine the area under the curve (AUC) values for age in both genders, age-specific cut-off values, sensitivity, specificity, and p-values.

Results: According to Ashley's classification, no type 3 and type 4 sternum was observed, and there was no statistically significant relationship between type 1 and type 2 sternum and gender ($p=0.389$). The best cut-off value for the age of manubrium of sternum ossification was 4 years in females and 5 years in males, 15 years for body of sternum ossification in both genders, and 14 years for xiphoid process ossification in females and 13 years in males. The fusion of segment 3 and segment 4 was estimated to be 8 years in females, while all other fusions were calculated to be 10 years and above in both genders, and all cut-off values were statistically significant ($p<0.05$).

Conclusion: Gender differences play a role in sternum ossification processes and fusions. Additionally, age-specific cut-off values determined in this study can be used to evaluate these parameters. However, according to Ashley's classification results, no significant differences were found between genders. These findings may help evaluate parts of the sternum taking into account gender and age in clinical practice.

Keywords: sternum, ossification, fusion, gender, age

O166 - A new free functional split gracilis flap design for natural smile reanimation in patients with total facial paralysis: a cadaveric study

Murat Enes Saglam¹, Murat Igde², Mehmet Yilmaz³, Mehmet Aydin³, Necati Salman⁴, R. Shane Tubbs⁵, Ayhan Comert³

¹Plastic, Reconstructive and Aesthetic Surgery Clinic, University of Health Sciences, Ankara City Hospital, Ankara, Türkiye

²Plastic, Reconstructive and Aesthetic Surgery Clinic, University of Health Sciences, Gülhane Training and Research Hospital, Ankara, Türkiye

³Department of Anatomy, Faculty of Medicine, Ankara University, Ankara, Türkiye

⁴Department of Anatomy, Gülhane Faculty of Medicine, University of Health Sciences, Ankara, Türkiye

⁵Department of Neurosurgery, School of Medicine, Tulane University, Tulane Center for Clinical Neurosciences, New Orleans, USA

Objective: The aim of this cadaveric study was to delineate the detailed anatomy of the gracilis muscle flap and explore the anatomical feasibility of split muscle flap transfer for periorbital and perioral facial reanimation.

Methods: Free split gracilis flap transfer was evaluated on 20 gracilis muscles from 10 embalmed cadavers. Harvested flaps were located between the temporal area and the oral and eyelid regions. Morphological measurements of the gracilis were obtained. The vascular pedicle of the flap was examined at the hilum. Distal vessel distribution was visualized on radiographic imaging.

Results: The width of the gracilis was 55.94 ± 6.83 mm. The number of distal branches of the major pedicle was a minimum of four and a maximum of six. There was no correlation between number of vessels and muscle width. The appropriate length of the distal muscle was cut from the hilum. Vessels within the sagittal sections at the distal edge of the flap were examined under an operating microscope (4x magnification). The uppermost part (1st part) had a weak vascular network (1.70 ± 0.45). All neurovascular morphological measurements indicated suitability for anastomosis sites.

Conclusion: The results showed that the distal part of the gracilis muscle flap in all cadavers could be split into four equal parts, each having vessels. The new free functional split gracilis flap design and transfer is suitable for periorbital and perioral facial reanimation.

Keywords: facial palsy, gracilis flap, microsurgery, vascular pedicle, anatomy

O168 - Evaluation of basal nuclei volumes in Multiple Sclerosis patients; preliminary report presentation

Fatma Nur Türkoğlu^{1,2}, Nadire Ünver Doğan², Şerefnur Öztürk³, Zeliha Fazlıoğulları², Mustafa Koplay⁴, Ahmet Kağan Karabulut²

¹Department of Anatomy, Faculty of Medicine, KTO Karatay University, Konya, Türkiye

²Department of Anatomy, Faculty of Medicine, Selcuk University, Konya, Türkiye

³Department of Neurology, Faculty of Medicine, Selcuk University, Konya, Türkiye

⁴Department of Radiology, Faculty of Medicine, Selcuk University, Konya, Türkiye

Objective: The aim of our study is to analyze Magnetic Resonance Imaging (MRI) data of Multiple Sclerosis (MS) patients with VolBrain, to make volumetric calculations for total intracranial volume and basal nuclei, and to determine the statistical differences of the obtained data in terms of gender, lateralization and MS subtypes.

Methods: In our study, MRI data of 156 MS patients were calculated using VolBrain, right-left and total intracranial volumes and basal nuclei volumes, and volumetric differences between MS subtypes and gender were statistically examined. Correlation analysis between age and parameters was also performed.

Results: Total intracranial tissue volume, right and left cerebral hemisphere volumes, putamen, substantia nigra and subthalamic nucleus total, right and left volumes were found to be significantly ($p < 0.05$) higher in male MS patients than in females. Statistical differences were observed between the putamen, substantia nigra and subthalamic nucleus asymmetry indices and right-sided substantia nigra and subthalamic nucleus volume measurements between MS subtypes. Putamen and amygdala volumes are significantly higher on the right side, and nucleus accumbens and subthalamic nucleus volumes are significantly higher on the left side ($p < 0.05$). In addition, significant positive and negative correlations were observed between age and volume measurements of total, right and left intracranial cavities and basal nuclei in MS patients.

Conclusion: Our study allowed us to investigate the relationships between basal nuclei volumes and total intracranial tissue volume in MS patients, and to show the differences between MS subtypes, gender and lateralisation of these volumes. As a result, a study was conducted to evaluate basal nuclei volumes in MS patients using the VolBrain method, which has been increasingly used in the literature in recent years. Our results contribute to the literature as they will guide future volumetric studies using computerised imaging techniques in neurodegenerative diseases.

Keywords: nuclei basales, VolBrain, volumetry, multiple sclerosis.

O170 - 3D printed anatomical models as pre-catheterization training material in interventional radiology

Vahide Tutuk¹, Emre Can Çelebioğlu², Selma Çalışkan¹

¹Department of Anatomy, Faculty of Medicine, Ankara Yıldırım Beyazıt University, Ankara, Türkiye

²Department of Radiology, Faculty of Medicine, Ankara University, Ankara, Türkiye

Objective: Angle between aorta and celiac trunk (ACTA) and angle between aorta and superior mesenteric artery (ASMA) are of great importance in endovascular treatments in interventional radiology clinics. Aim of the present study is to compare the angle measured on computed tomography angiography (CTA) images and 3D printed models of same patients.

Methods: This study consists of seven patients (4 men and 3 women) admitted to emergency clinics and underwent CTA with preliminary diagnosis of aortic aneurysm /dissection or mesenteric ischemia. ACTA and ASMA of patients were measured on CTA images. 3D models of the CTA images were created and printed with a high speed commercial fused deposition modeling device. For high speed printing polylactic acid filaments were used.

Results: Mean value of ACTA measured on CTA images was 58,75° and measured on 3D printed models was 67,36° in men. Mean value of ACTA measured on CTA images was 30,3° and measured on 3D models was 64,16° in women. Mean value of ASMA measured on CTA images and 3D models were respectively 56° and 60,26° in men. Mean value of ASMA measured on CTA images and 3D models were respectively 38,3° and 48,2° in women.

Conclusion: Endovascular treatments (transcatheter chemoembolization, transcatheter chemotherapy, balloon angioplasty, stenting, selective thrombolytic treatment) are common, minimally invasive options. ACTA and ASMA are critically important for interventional radiologists when choosing catheter and trans arterial approach site. While it is easy to catheterize an upward or a horizontal celiac trunk (CT) or superior mesenteric artery (SMA) through femoral arterial approach, catheterization downward CT and SMA through radial arterial approach is easier. 3D printed models of arteries of patients who are candidates for endovascular treatment provide opportunity to improve catheterization technique for physicians. Besides these models give idea for proper catheter choice, to prevent complication and predict approach site.

Keywords: interventional radiology, 3D anatomical models, anatomy

O175 - Morphological features of carotid body in children: A computed tomography angiography study

Zeynep Yılmaz¹, Dilek Yıldırım², Ayşegül Fırat¹, Raşan Göçmen³

¹Department of Anatomy, Faculty of Medicine, Hacettepe University, Ankara, Türkiye

²Public Health Specialist, MD, Ankara, Türkiye

³Department of Radiology, Faculty of Medicine, Hacettepe University, Ankara, Türkiye

Objective: The carotid body (CB) is a structure located within the wall of the common carotid artery (CCA) and usually located near the bifurcation of CCA. CB has chemo-baroreceptor functions that regulates blood pressure, heart rate and respiratory status. It usually has 5-7 mm dimensions and 2,5- 4 mm³ volume in adults. As it is a quite small structure, it is difficult to observe directly during gross anatomical dissections. In this study, we have described the morphology of the human CB in children to provide a basis for clinical purposes, especially for changes with age.

Methods: The computed tomography angiography (CTA) is a gold standard minimally invasive method for visualizing blood vessels. We have evaluated CB of 1months-18 years of patients bilaterally by reviewing CTAs obtained between 2017-2023 in Hacettepe Medical Center Department of Radiology.

Results: We have evaluated 73 patients who underwent CTA at childhood period. The patient group consisted of 45 (61,6%) boys and 28 (38,4%) girls and 75,3% were between 0-6 years old (n=55). In CTA we reported right sided CB in 63%, left sided CB in 50,7% of patients. Right sided CBs were mostly rounded (45,7%) and located equally on the bifurcation and medial side of internal carotid artery (%39,1). Left sided CBs were ellipsoid in shape (37,8%) and mostly located at the bifurcation of CCA (43,2%).

Conclusion: In this study we have demonstrated that CB can be visualized and assessed by CTA in children. As the most important limitation is the visualization of the CB; CTA is a more suitable and non-invasive method for assessment of vessel adventitia. Especially for differentiation of paragangliomas and normal adventitial structures, we should be aware of their morphology. As far we know that this is the first study that was evaluated the CB of children.

Keywords: carotid body, computed tomography angiography, carotid bifurcation

O176 - Volumetric analysis of subcortical structures in obese individuals in Turkish population with MRICloud method

Beyza Nur Urul¹, Tuğrul Örmeci², Alper Atasever¹

¹Department of Anatomy, Istanbul Medipol University, Istanbul, Türkiye

²Department of Radiology, Medicana Ataköy Hospital, Istanbul, Türkiye

Objective: Our study aims to provide more information about the energy homeostasis of some subcortical structures in the brain and their role on obesity and to reveal the relationship between brain anatomy and BMI in obese individuals in the Turkish population.

Methods: 80 individuals between the ages of 18-50 were included in the study. Among these individuals, those with a BMI greater than or equal to 30 kg/m² were classified as obese. Of the individuals in the obese class, 22 were male and 18 were female. Individuals with a BMI between 18,5 kg/m² and 24,99 kg/m² were included in the control group, and 22 of the individuals in this group were male and 18 were female. Magnetic resonance imaging (MRI) was used to obtain anatomical details of subcortical structures. Thanks to MRI, local concentration differences of brain tissues were analyzed volumetrically with Web-based MRICloud software.

Results: When we compared the control and patient groups, a significant difference was found between the groups in the volume of the left white matter, left claustrum, right hippocampus, left thalamus, right hypothalamus and bilateral nucleus accumbens, putamen, globus pallidus, nucleus caudatus, substantia nigra ($p < 0.05$).

Conclusion: Based on our results, we observed that subcortical structures are associated with feeding behavior and sensory function in obese individuals, and subcortical structure volumes vary about BMI. Although we could not explain the reason for the observed structural differences from our results, we found an association. Future studies are needed on the biological basis of changes in brain structure in obesity.

Keywords: MRICloud, nuclei basales, obesity, subcortical structure, white matter

O177 - The geometric morphometric and morphometric analysis of distal humerus

Beyza Nur Caymaz¹, Kübra Erdoğan¹

¹Department of Anatomy, Faculty of Medicine, İzmir Katip Çelebi University, İzmir, Türkiye

Objective: Our study aimed to determine the differences in gender, side and landmark variations of the distal end of dry humerus using morphometric and geometric morphometric methods.

Methods: Our study was performed on 40 (21 right, 19 left) dry humerus bones. Linear measurements and geometric morphometric analysis were performed on ImageJ and MorphoJ softwares, respectively. In 36 humeri, Rogers' method was used to estimate sex in the humerus. Then, geometric morphometry was used to determine the gender and side differences on the landmarks in the posterior and inferior views.

Results: In linear measurements, only the trochlea humeri width and the internal rotation angle differed between the sides ($p < 0.05$). Using Rogers' method, 15 of the 20 humerus on the right side and 9 of the 16 humerus on the left side were estimated as male. There was no difference in all parameters except the trochlea humeri width and humerus distal end internal rotation angle between the sides in both genders. In the comparison between genders, differences were found in all parameters except the distance between the fossa olecrani and epicondylus medialis and the internal rotation angle ($p < 0.05$). In the shape analysis, the landmarks that most affected the shape variation in terms of sides and gender were located in the epicondylus medialis, epicondylus lateralis and supracondylar regions in the posterior images and in the landmark where the trochlea humeri contacted the table in the inferior images.

Conclusion: The landmarks in the epicondylus medialis and lateralis regions affected the shape variation the most in both views. Landmarks around the fossa olecrani and trochlea humeri were observed to affect the shape variation less. In this study, the lower incidence of shape variations in the fossa olecrani region supports that the posterior approach is a more reliable method in surgical treatment.

Keywords: humerus, morphometry, geometric morphometry, shape analysis.

O179 - Analysis of idh-1 genotype in glioblastomas: A radiomics study

Aslı Beril Karakaş¹, Figen Gökmen², Mehmet Asım Özer², Hüseyin Biçeroğlu³, Cenk Eraslan⁴, Deniz Tanır⁵

¹Department of Anatomy, Faculty of Medicine, Kafkas University, Kars, Türkiye

²Department of Anatomy, Faculty of Medicine, Ege University, Izmir, Türkiye

³Department of Neurosurgery, Faculty of Medicine, Ege University, Izmir, Türkiye

⁴Department of Radiology, Faculty of Medicine, Ege University, Izmir, Türkiye

⁵Department of Management Information Systems, Faculty of Economics and Administrative Sciences, Kafkas University, Kars, Türkiye

Objective: The aim of this study is to apply a radiomics approach using various machine learning classifiers to evaluate the prognosis and survival, which is an important factor in IDH-1 mutation. A mutation that affects the isocitrate dehydrogenase-1 (IDH-1) gene has been found in approximately 5% of primary glioblastomas (GBMs), and in over 70% of secondary GBMs, oligodendroglial, and astrocytic tumors.

Methods: The diagnostic performance and generalizability of traditional machine learning models were evaluated to distinguish glioblastoma from IDH-1 mutant and IDH-1 wild type using radiomics. Six different machine learning algorithms were used in this study, including discriminant, support vector machines (SVM), decision tree (DT), logistic regression (LR), K-nearest neighbors (KNN), and ensemble.

Results: The area under the curve (AUC) values of DT, discriminant, SVM, ensemble, logistic regression, and KNN algorithms were found to be 74%, 84%, 87%, 85%, 64%, and 90%, respectively, indicating the highest diagnostic performance in terms of sensitivity, specificity, and accuracy parameters. It was determined that KNN and SVM were the most successful algorithms. Additionally, there was a correlation between IDH-1 mutation and P53 gene, epilepsy, age, and radiomics features such as major axis length (MAJAL), maximum 2D diameter (Max2Ddia), maximum 3D diameter (Max3Ddia), minor axis length (MINAL), surface area (surfarea), low gray level emphasis (LGLE), short-run low gray level emphasis (SRLGLE), gray level nonuniformity (GLNUNA), large area high gray level emphasis (LAHGLE), low gray level zone emphasis (LGLZE), and small area low gray level emphasis (SALGLE).

Conclusion: As a result, the radiomics prediction model based on preoperative advanced magnetic resonance imaging can effectively predict the IDH-1 genotype of high-grade glioma. Thus, it can be used as a routine pre-treatment evaluation method that determines the prognosis and treatment effect of glioma, directing to radiotherapy and chemotherapy instead of surgical resection.

Keywords: artificial intelligence, machine learning, glioma, radiomics, survival prediction.

O183 - 3D reconstruction of kidneys in cadaver fetus

Şenol Pişkin¹, Özlem Elvan², Kaan Esen³, Deniz Uzmannel⁴, Samir Donmazov⁵

¹Department of Mechanical Engineering, of Engineering and Natural Sciences, İstinye University, İstanbul, Türkiye

²İçel School of Health, Mersin University, Mersin, Türkiye

³Department of Radiology, School of Medicine, Mersin University, Mersin, Türkiye

⁴Department of Anatomy, School of Medicine, Mersin University, Mersin, Türkiye

⁵Department of Mathematics, College of Arts and Sciences, Kentucky University, Lexington, USA

Objective: The aim of this study was to determine the morphological and morphometric analysis of fetal kidneys radiologically to highlight the use of reconstruction and modeling methods for cadaver scanning.

Methods: Two formalin-fixed fetuses (a 33-week-old boy and a 40-week-old girl) were utilized. Radiological images of the fetuses were acquired using a 1.5 Tesla MR system with T2-weighted sequences. The image sections obtained in DICOM format were organized into a single directory and processed using Slicer3D software. The clinically obtained datasets with the most suitable sequence and image quality were selected. The segmentation phase was initiated by staining kidneys. This staining process began by outlining the outer boundaries of the kidneys in specific sections. The areas within the boundaries were automatically filled to encompass the entire kidney region. This approach allowed for the capture of the 3D shape of the kidneys. Following this procedure, all stained kidney sections were merged, resulting in the 3D reconstruction of the anatomical structure. Subsequently, the created 3D node cluster was saved in stereolithography file format, which is one of the most suitable standard formats for 3D modeling, editing, and printing. Using this model, the size and volume of the kidneys were measured.

Results: Measurements of 3D reconstructed kidney models of a 33-week-old male fetus: 1- Kidney length from the top to bottom edges: Right kidney: 38.32 mm, left kidney: 35.72 mm. 2- Medial-lateral width at the midpoint of the length: Right kidney: 21.23 mm, left kidney: 23.30 mm. 3- Volume; Right kidney: 8879.36 mm³, Left kidney: 8941.18 mm³.

Conclusion: This study combines engineering and an anatomical case study. Such studies can be used to help determine the approach for planned surgery in patients. Continuing this study, we aim to utilize a convolutional neural network, an artificial intelligence method, to achieve high-accuracy image segmentation.

Keywords: fetus; anatomy; reconstruction; convolutional neural network; artificial intelligence

O189 - Fractal geometry for determining the shapes and sizes of anatomical structures

Behice Durgun¹

¹Department of Anatomy, Faculty of Medicine, Çukurova University, Adana, Türkiye

Objective: Fractal is the common name for complex shapes that often exhibit self-similarity or proportional diffraction properties. The aim of this study is to review the importance of fractal geometry for determining the shapes and sizes of anatomical structures in the light of both literature knowledge and the author's experiences.

Methods: A fractal can be generated by a repeating pattern, typically iterative process. The concept, first put forward by mathematician Mandelbrot in 1975, has led to the emergence of a new geometry system that has had significant effects on various fields such as physical chemistry, physiology, fluid mechanics, cosmology, diagnosing of diseases, engineering, computer sciences and genetics - and art- and music, too. According to Mandelbrot's definition, fractal dimension; $D = \lim_{a \rightarrow 0} \frac{\log N}{\log(1/a)}$. In some cases, the value of the fraction is the same every time the fraction approaches the limit D , which is a constant value. In this situation; The formula $D = \log N / \log(1/a)$ is used.

Results: There are many fractals in the human body, for example arteries, neurons, cerebral gyri, cerebellar white matter and intestines. The measuring of any structure by classical geometry or fractal geometry gives different results. A normal Euclidean shape, such as a circle, looks flatter and flatter as it is magnified. At infinite magnification, the difference between the circle and a straight line disappears. Instead, with a fractal, increasing the magnification reveals more detail that was previously invisible.

Conclusion: Fractal geometry has received little attention in the field of anatomy. Whereas fractal geometry is used to measure the size of objects which cannot be explained easily by Euclidean geometry, and human body is the best example of this. Therefore, the use of fractal geometry in shape and size analysis in anatomy becomes more important to find the differences between healthy and diseased structures.

Keywords: fractal, fractal dimension, anatomical structures, Koch curve, Mandelbrot set

P5 - A variation of the lateral circumflex femoral artery

Elif Cansu İbiş¹, Ercan Tanyeli¹, Mehmet Üzel¹, Ali İhsan Soyluoğlu¹

¹Department of Anatomy, Faculty of Medicine, Istanbul University-Cerrahpaşa, Istanbul, Türkiye

Objective: The aim of this study is to report a variation of the lateral circumflex femoral artery (LCFA) and to guide the clinicians performing radiological and surgical interventions in this area.

Case: During dissections for the thesis study in 2021-2022, it was observed that the ascending and descending branches of the LCFA originated from the deep femoral artery (DFA) with separate origins on the anterior aspect of the left thigh of a 70-year-old female cadaver. Meticulous dissection revealed that the descending branch of the LCFA originated anterolaterally, 0.7 cm distal to the origin of the DFA, whereas the ascending branch originated posterolaterally, 1.8 cm distal to the DFA. When the diameters were measured, the descending branch was 0.35 cm, and the ascending branch was 0.4 cm. The distance of the descending branch to the mid-inguinal point was 3.2 cm, while the distance of the ascending branch was 5 cm. As the ascending branch traveled laterally, it gave a transverse branch with a diameter of 0.23 cm and deepened by piercing the vastus lateralis muscle. The medial circumflex femoral artery emerged from DFA as a thin branch.

Conclusion: The frequency of this variation in our case is between 0.6%, and 4% in the literature. Both branches of the LCFA are of clinical importance. While the ascending branch can be used in vascularized iliac grafting, the descending branch can be used as a collateral artery, an anterolateral pedicled tissue flap, and as a graft in various bypass procedures. Consideration of these variations in procedures to be performed in the hip region will guide the clinician during the intraoperative and postoperative periods.

Keywords: classification, deep femoral artery, dissection, lateral circumflex femoral artery, variations

P9 - Is there a difference between anatomy and gynecology textbooks in terms of female external genitalia?

Gönül Kotil Aslan¹, Çağatay Barut¹

¹Department of Anatomy, Faculty of Medicine, Istanbul Medeniyet University, Istanbul, Türkiye

Objective: With the increasing popularity of female cosmetic gynecology surgeries, interest in female external genital system anatomy is increasing. A wide variety of variations have been encountered in the vulva, both in shape and size. Therefore, there is no clear definition of what is normal in the female external genitalia. In order to reveal this situation, the structures defined by the term vulva in the anatomy and gynecology textbooks and the details given about these structures were evaluated. To achieve this goal, the existence of the structures defined by the term vulva, whether their dimensions are included, and whether the texts are supported by visuals have been reviewed.

Methods: 30 gynecology and obstetrics textbooks and 30 anatomy textbooks, each of which were published in English by international publishers, were scanned. The Chi-squared test was used for comparison of categorical variables which were presented by frequency and percent using SPSS 25.0.

Results: In anatomy textbooks vulva was included 90%, mons pubis 96.7%, hymen 83.3%, vestibulum vagina 96.7%, skene glands 50% while in gynecology textbooks vulva was included 96.7%, mons pubis 90%, hymen 83.3%, vestibulum vagina 90%, skene glands 60%. There was no statistically significant difference between anatomy and gynecology books in terms of including these structures. Glandula vestibularis minor was defined in 53.3% of the anatomy and 83.3% in the gynecology books, and the difference was statistically significant ($p < 0.05$). Clitoris, glandula vestibularis major, labia majora and labia minora are described in all anatomy and gynecology books. While the dimension of clitoris and glandula vestibularis major were included in 13.3% and 26.7% of the anatomy books respectively, this information is included for both structures in 30% of the gynecology books. Bulbus vestibuli is not defined at all in 16.7% of anatomy, 40% of gynecology books, and dimension information is included in 10% of both anatomy and gynecology books. The differences between book groups related to these structures were not statistically significant ($p > 0.05$).

Conclusion: Although the target groups for both textbook groups are not the same a consensus for inclusion of these structures and more details regarding the dimensions is crucial.

Keywords: female external genitalia, vulva, anatomy, gynecology, definition

P12 - Comparative evaluation of thickness, surface area, and volume data obtained by FreeSurfer and BrainSuite in brain segmentation and parcellation

Bünyamin Şahin¹, Yasemin Ekiz², Necati Emre Şahin³, Gülhan Akan⁴

¹Department of Anatomy, Faculty of Medicine, Ondokuz Mayıs University, Samsun, Türkiye

²Department of Anatomy, Faculty of Medicine, Istanbul Medipol University, Istanbul, Türkiye

³Department of Anatomy, Faculty of Medicine, Karabuk University, Karabuk, Türkiye

⁴Department of Radiology, Faculty of Medicine, Istanbul Medipol University, Istanbul, Türkiye

Objective: Accurate brain segmentation and parcellation are vital for neuroimaging studies. However, discrepancies in data may arise due to different atlases. This study compared the effectiveness of FreeSurfer (FS) and BrainSuite (BS) software packages.

Methods: We analyzed Magnetic Resonance images of 45 healthy individuals (23 females, 22 males) aged 20-40. We obtained the volume, surface area, and thickness of the brain, right motor cortex, and right thalamus using FS and BS. Findings of software and group differences between males and females were evaluated using both software.

Results: The mean volumes ($\text{cm}^3 \pm \text{SD}$) of the thalamus, motor cortex, and total brain were 7.20 ± 0.63 , 28.54 ± 2.89 , and 951.9 ± 80.02 for FS, and 6.25 ± 0.64 , 25.47 ± 2.18 , and 772.6 ± 55.43 for BS, respectively. The mean surface areas ($\text{cm}^2 \pm \text{SD}$) of the motor cortex and total brain were 59.30 ± 4.82 and 1966.71 ± 157.28 for FS, and 57.80 ± 4.80 and 1797.97 ± 135.92 for BS. The mean values of thickness ($\text{mm} \pm \text{SD}$) for the motor cortex and total brain were 2.32 ± 0.17 and 2.37 ± 0.10 for FS and 4.05 ± 0.35 and 3.95 ± 0.29 for BS. The volumes and surface areas derived from BS were significantly smaller, and the cortical thickness was larger than those obtained from FS ($P < 0.05$). Comparisons between males and females using both FS and BS data showed larger volumes and surface areas in males for all regions ($p < 0.05$).

Conclusion: Differences between the software packages were observed in thickness, surface area, and volume values. However, group comparisons using either FS or BS data yielded similar results. Therefore, group comparisons can be reliably conducted using either FS or BS.

Keywords: brain segmentation, parcellation, neuroimaging studies, FreeSurfer, BrainSuite

P16 - Evaluation of posterior cranial fossa anatomy in migraine patients

Ebru Otu¹, Tugrul Ormeci², Neslihan Yuzbasioglu¹

¹Department of Anatomy, School of Medicine, Istanbul Medipol University, Istanbul, Türkiye

²Department of Radiology, Medicana Ataköy Hospital, Istanbul, Türkiye

Objective: The aim of this study is to investigate whether the morphometric features of the posterior cranial fossa (PFC) are related to migraine disease by using magnetic resonance (MR) images.

Methods: We conducted a retrospective study with 60 patients diagnosed with migraine and 50 control subjects in the age range of 18-55 years who underwent magnetic resonance imaging (MRI). Based on the sagittal T1 weighted MR images, parameters referring to posterior fossa crowdedness were measured.

Results: The migraine group included 32 females, 28 males (mean age of 35.02 ± 7.9 years), the control group was included 25 females, 25 males (mean age of 38.02 ± 9.1 years). Patients with migraine had a significantly shorter distance from the clivus to the mid-pons than the control group (3.4 ± 1.4 mm vs 4.1 ± 1.2 mm, $p = 0,006$). There was no difference in other morphometric parameters that indicate the posterior fossa crowdedness between the migraine and control groups ($p > 0,05$).

Conclusion: Decreased prepontine distance in migraine patients may play a role in the development of migraine disease by causing compression of the basilar artery or stretching of the trigeminal nerve located in the prepontine cistern.

Keywords: migraine, posterior cranial fossa, basilar artery, trigeminal nerve, magnetic resonance imaging

P17 - How effective are acromion types and acromial morphometrics in musculus supraspinatus tear?

Semih Burak Sozcu¹, Tugrul Ormeci², Neslihan Yuzbasioglu¹

¹Department of Anatomy, School of Medicine, Istanbul Medipol University, Istanbul, Türkiye

²Department of Radiology, Medicana Hospital Atakoy, Istanbul, Türkiye

Objective: The morphology of the cavitas glenoidalis, acromion and humerus have not been fully explained in the literature whether they cause rotator cuff tears. Accordingly, the aim of this study was to investigate the effect of acromion types and acromion morphologies on musculus supraspinatus tears.

Methods: In our study, we retrospectively analyzed a total of 150 patients from different age groups (age range 27-86 years), including 50 patients with Type I acromion, 50 patients with Type II acromion and 50 patients with Type III acromion with musculus supraspinatus tear who underwent Magnetic Resonance (MR) examination. Accordingly, acromial tilt, acromial index, critical shoulder angle, lateral acromial angle, acromial slope and acromio-humeral distance were evaluated on two-dimensional (2D) conventional MR images of the patients and the relationship between musculus supraspinatus tears and these parameters was examined to see whether the type of acromion had an effect on the tears.

Results: There was a statistically significant difference in the acromial slope, lateral acromial angle, critical shoulder angle, acromio-humeral distance and acromial index values between acromion types ($p < 0.05$). Acromial tilt values measured between acromion types did not show statistically significant differences ($p > 0.05$).

Conclusion: Increased acromial slope, critical shoulder angle and acromial index values and decreased acromio-humeral distance are thought to be more likely to cause musculus supraspinatus tears in patients with Type III acromion. A decrease in the lateral acromial angle is thought to be more likely to cause musculus supraspinatus tears in those with a Type I acromion. Acromial tilt measurement is not thought to be effective in the likelihood of musculus supraspinatus tears.

Keywords: acromial index, acromion type, critical shoulder angle, lateral acromial angle, supraspinatus muscle

P21 - Condition of musculus rectus abdominis in patients with Covid-19

Dilek Aydemir¹, İlyas Uçar¹, Muhammet Değermenci², Muharrem Said Coşgun³

¹Department of Anatomy, Faculty of Medicine, Erciyes University, Kayseri, Türkiye

²Department of Anatomy, Faculty of Medicine, Ordu University, Ordu, Türkiye

³Department of Cardiology, Faculty of Medicine, Erzincan Binali Yıldırım University, Erzincan, Türkiye

Objective: Coronavirus 2019 (Covid-19) is an infectious disease that especially affects the respiratory system. Although there are studies investigating its effects on respiratory muscles in the literature, studies investigating the status of auxiliary respiratory muscles are limited. In our study, we aimed to determine the time-dependent changes in the size of the rectus abdominis (RA) on lung computed tomography (CT) in patients with Covid-19.

Methods: Images of 26 adult patients (13 females, 13 males) with stage I (0-4 days) and stage VI (>28 days) with two non-contrast chest CT images were obtained retrospectively. Cross-sectional areas of RA were calculated and statistically analyzed using the "Image J program".

Results: The values of RA in stage I and stage II were 4.34 – 3.87 and 4.40 – 3.84 cm² for right and left, respectively ($p < 0.05$). The differences of right and left measurements according to gender were not statistically significant ($p > 0.05$).

Conclusion: Auxiliary respiratory muscles appear to be atrophied in individuals with Covid 19. Considering that RA plays a role especially in the expiration phase, the inclusion of auxiliary respiratory muscles in the planned respiratory muscle training in these patients may positively affect the course of the disease.

Keywords: covid-19, computed tomography, accessory respiratory muscles, rectus abdominis.

P22 - Anatomy in the light of state archives documents

Yunus Emre Kundakcı¹

¹Department of Physiotherapy and Rehabilitation, Faculty of Health Sciences, Afyonkarahisar Health Sciences University, Afyonkarahisar, Türkiye

Objective: Anatomy has been a cornerstone of medical education throughout history, regardless of culture, civilization, nation, race, etc., and has undergone historical evolutionary processes. This study, it was aimed to analyze the documents related to anatomy science registered in the Presidency of State Archives.

Methods: The words “İlm-i teşrih” for the Ottoman Archive and “Anatomy” for the Republican Archive were scanned in the Document Scanning System of the Directorate of State Archives. The date, subject and archive record information of the first and last records in both periods and the documents belonging to Dr. Doğan Taner were obtained. In addition, the general perspective of the documents was synthesized and summarised.

Results: There were 57 documents in the Ottoman Archive between 1768-1909 and 73 documents in the Republican Archive between 1926-1989. The documents from the Ottoman period consisted of various contents such as medical education, promotions, salaries and teacher appointments. The documents from the Republican period, on the other hand, were related to appointments to the anatomy departments of the faculties of medicine, veterinary medicine and health sciences of different universities in Turkey, including Dr Dogan Taner, as well as appointments of academics and laboratory equipment purchased from abroad.

Conclusion: Archival records provide a history of academic appointments and assignments in the fields of medical education and health sciences in the Ottoman and Turkish periods. Since these documents provide an important historical perspective on the science of anatomy, they can be an important source for academic research in the fields of anatomy and history of medicine.

Keywords: anatomy, anatomy history, history of medicine, ilm-i teşrih

P25 - Neuroplasticity; the brain's lifelong power of change

Figen Koç Direk¹, Sibel Ateşoğlu Karabaş²

¹Department of Anatomy, Faculty of Medicine, Mardin Artuklu University, Mardin, Türkiye

²Department of Anatomy, Faculty of Medicine, Kahramanmaraş Sütçü İmam University, Kahramanmaraş, Türkiye

Objective: In this study, our aim is to summarize the basic concepts, biological mechanisms and contributions of neuroplasticity to human health.

Methods: Researches using keywords such as “neuroplasticity”, “nervous system”, “brain”, “synaptic plasticity”, “neurogenesis”, “neurotrophins” were scanned in PubMed, Web of Science and Google Scholar databases. Articles published in the last 10 years and containing experimental or clinical studies related to neuroplasticity were selected.

Results: Neuroplasticity occurs through three basic mechanisms: synaptic plasticity, neurogenesis and gliogenesis. Synaptic plasticity is the strengthening or weakening of connections between nerve cells. Neurogenesis is the formation of new nerve cells. Gliogenesis is the proliferation of glial cells, which are supportive nerve cells. Growth factors called neurotrophins play an important role in regulating neuroplasticity. Neurotrophins promote the survival, growth and differentiation of nerve cells. The measurement methods of neuroplasticity are brain imaging techniques, neuropsychological tests and electrophysiological methods. Brain imaging techniques are methods that show brain structure and function such as magnetic resonance imaging (MRI), functional magnetic resonance imaging (fMRI), positron emission tomography (PET) and single photon emission tomography (SPECT). Neuropsychological tests are tests that evaluate cognitive, emotional and behavioral functions. Electrophysiological methods are methods that measure brain electrical activity such as electroencephalography (EEG), magnetoencephalography (MEG) and transcranial magnetic stimulation (TMS). Neuroplasticity plays an important role in many clinical conditions such as brain injury (stroke, trauma, dementia), neurodegenerative diseases (Alzheimer's, Parkinson's), psychiatric disorders (depression, anxiety), learning and memory. Neuroplasticity can be increased by pharmacological (antidepressants, antipsychotics, nootropics) or non-pharmacological (physical activity, rehabilitation, cognitive therapy, music therapy) treatments.

Conclusion: Thanks to neuroplasticity, our brain can restructure itself against environmental stimuli, learning experiences and damages. Understanding and modulating neuroplasticity is of great importance for human health and quality of life.

Keywords: neuroplasticity, nervous system, synaptic plasticity, neurogenesis, neurotrophins

P28 - Bibliometric analysis of the one hundred most cited articles during the first hundred years of our republic

Hanife Ertürk¹, Kenan Öztürk¹, İhsan Hız¹, Yadigar Kastamoni¹

¹Department of Anatomy, Faculty of Medicine, Süleyman Demirel University, Isparta, Türkiye

Objective: Anatomy is one of the oldest medical sciences known to humankind. Bibliometric studies are the quantitative analysis of publications in the literature using statistical methods. In order to show trend topics in the field of anatomy or determine field trends, the top 100 articles cited in anatomy, written by researchers from our country, were analyzed using data obtained from Web of Science (WoS).

Methods: The data included in the study were collected by typing the word “anatomy” in the “all fields” category in the WoS database. The study included articles written by researchers from our country in English and published in international journals and that had at least one citation between 1980 and 10.09.2023. The data were transferred to the VOSviewer 1.6.19 program for detailed analysis and analyses were performed.

Results: Of the top 100 cited articles, 33 were cadaver studies, 25 were radiological studies, 13 were clinical studies, 6 were animal experiment studies, 6 were morphometry studies, 4 were dry bones, 3 were fetal cadavers, 2 were editor comments, and 2 were anatomy education topics. Six articles were related to veterinary anatomy. The article “Acknowledging the use of human cadaveric tissues in research papers: Recommendations from anatomical journal editors,” by Nihal Apaydin and Gülgün Sengül, with 234 citations, was the most cited article. According to keyword analysis, the authors used the words “anatomy, variation, stereology, MRI, and facial nerve” the most. Surgical and Radiologic Anatomy, Clinical Anatomy, Folia Morphologia were the most cited journals, respectively. In addition, author citation analysis, co-authorship analyses, country citation analysis, institution citation analysis were also performed.

Conclusion: The bibliographic analysis of the 100 articles in our study will help anatomists to understand which topics they need to study in the future and the place of anatomy in the literature.

Keywords: anatomy, attribution, bibliometric analysis, Web of Science (WoS), VOSviewer

P38 - Investigation of the protective effect of *lavandula stoechas* against the damage caused by bisphenol a in the liver tissue of rats

Merve Aydın¹, Evren Köse¹, Elif Taşlıdere², Kevser Tanbek³, Süleyman Sandal³

¹Department of Anatomy, Faculty of Medicine, İnönü University, Malatya, Türkiye

²Department of Histology and Embryology, Faculty of Medicine, İnönü University, Malatya, Türkiye

³Department of Physiology, Faculty of Medicine, İnönü University, Malatya, Türkiye

Objective: The aim of the study is to investigate the protective effect of *Lavandula stoechas* against the toxicity of Bisphenol A in the liver.

Methods: In this study, 32 Wistar Albino male rats were used. Eight rats each were divided into Control, LS (50 mg/kg LS oil), BPA (50 mg/kg BPA), and BPA+LS (50 mg/kg BPA + 50 mg/kg LS oil). No application was made to the control group. During the experiment (28 days), *Lavandula stoechas* oil was administered intraperitoneally, and BPA was administered by oral gavage. At the end of the study, rats were sacrificed by taking blood from the heart after an anesthetic agent was given. ALT, AST, and total bilirubin values were measured from serum samples. MDA, SOD, TAS, TOS, and OSI measurements were performed in liver tissue. In addition, hematoxylin and eosin staining methods were applied to observe the histological structure.

Results: In the serum examinations, AST levels increased in the BPA group compared to the control group but decreased significantly in the BPA+LS group compared to the BPA group ($p = 0.10928$). In addition, TB levels were found to be significantly lower in the BPA+LS group compared to the BPA group. When the tissue analyzes were examined, it was observed that the MDA level increased significantly in the BPA-treated groups compared to the other groups. SOD levels increased in the LS-treated groups compared to the control. In addition, it was observed that there was a significant increase in the BPA+LS group compared to the BPA group. When the OSI value was examined, it was observed that there was a significant increase in the BPA group compared to the control.

Conclusion: In our study, it was determined that *Lavandula stoechas* has a protective effect against BPA-induced liver toxicity.

Keywords: bisphenol a, *lavandula stoechas*, liver, oxidative stress

P39 - Radiological evaluation of the relationship of meniscocapsular thickness with anterior cruciate ligament and its clinical significance

Simge Kökcan^{1,2}, Burak Bilecenoglu³

¹Department of Anatomy, Health Science Institute, Istanbul Medipol University, Istanbul, Türkiye

²Sportoteam Sports and Spine Health Center, Istanbul, Türkiye

³Department of Anatomy, Faculty of Medicine, Ankara Medipol University, Ankara, Türkiye

Objective: The tear of the peripheral connection of the posterior horn of the medial meniscus, which is related to anterior cruciate ligament (ACL) injuries, is called meniscocapsular tear (ramp lesion). Ramp lesion cannot be detected by magnetic resonance imaging (MRI) and arthroscopy is needed for definitive diagnosis. However, since it is in an arthroscopic blind spot, it is a lesion that is often overlooked. In order to contribute to the diagnosis of this lesion by MRI, the relationship between meniscocapsular thickness and ACL was examined.

Methods: In this retrospective study, 48 people who met the criteria for admission were included. 24 people with ACL injuries and 24 people without were divided into two groups. Sagittal sections were used in the images taken with a 3 Tesla MRI device. Measurement; A horizontal line was drawn towards the end of the capsule, taking the end point of the posterior horn of the medial meniscus as the starting point. Images were evaluated using RadiAnt Dicom Viewer software.

Results: In the ACL injury group, meniscocapsular thickness (7.06 mm) was higher than in the other group (6.15 mm). In addition, the meniscocapsular thickness of the right knee is higher than that of the left knee. Men's meniscocapsular thickness was observed to be greater (6.96 mm) than women (6.25 mm). It has been shown that meniscocapsular thickness increases with age in individuals with ACL injuries.

Conclusion: It was concluded that meniscocapsular thickness was greater in individuals with ACL injuries. It can be thought that one of the reasons for the ramp lesion may be increased meniscocapsular thickness. Identification of this relationship may contribute to the diagnosis of ramp lesion with MRI without the need for arthroscopy or by supporting arthroscopy.

Keywords: meniscocapsular thickness, anterior cruciate ligament, ramp lesion

P40 - Morphometric examination of flexor pollicis brevis in human fetuses

Saliha Seda Adanır¹, Mehmet Koçbay², Orhan Beger¹, İlhan Bahşi¹, Mustafa Orhan¹, Piraye Kervancıoğlu²

¹Department of Anatomy, Faculty of Medicine, Gaziantep University, Gaziantep, Türkiye

²Faculty of Medicine, Gaziantep University, Gaziantep, Türkiye

Objective: Flexor pollicis brevis (FPB) is one of the thenar muscles, lies between flexor retinaculum and radial side of base of phalanx of thumb. It has been reported, FPB may be outside of normal pattern in thumb congenital anomalies. There is no study in the literature examining FPB anatomical features in human fetuses. In this study, it was aimed to examine FPB anatomical features in fetuses and to examine development pattern of muscle.

Methods: Fifty-four sides of 27 fetuses (mean age: 24.67 ± 3.93 weeks; gender: 11 boys, 16 girls) in the laboratory of Gaziantep University Anatomy Department, were dissected. FPB origin and insertion were determined. The dissected area was photographed with Canon Eos 600 D Digital Camera and x10 magnification. The muscle length, width, and area were measured 3 times by two observers using Image J. Descriptive statistics were made and muscle development equations were calculated according to weeks. The study was conducted in accordance with the Declaration of Helsinki.

Results: In the classification according to FPB origin, 3 types were detected, and in the classification according to insertion, 6 types were detected. It was found that FPB most frequently originate from the flexor retinaculum (52 sides, 96.29%), most frequently inserted in first metacarpophalangeal joint (44 sides, 81.48%). The mean FPB length was 7.32 ± 1.82 mm, mean width was 2.48 ± 0.74 mm, and mean area was 17.39 ± 9.20 mm². The equations showing development of muscle length, width and area according to weeks are respectively; $y = -0.606 + 0.334x$ week, $y = 0.336 + 0.088x$ week, $y = -12.53 + 1.23x$ week.

Conclusion: FPB can be used in tendon transfer to restore adductor pollicis function in ulnar nerve palsy. Therefore, knowing the variations and anatomical features of FPB is essential in reconstructive surgery for thumb. Our typing according to origin and insertion is the first in the literature and may be useful for future studies focusing on thumb surgeries.

Keywords: dissection, fetus, flexor pollicis brevis, thenar region

P41 - Anatomical variations of inferior phrenic arteries: Insights from computed tomography angiography

Serra Ozturk¹, Ayse Keven², Ekin Tuna Sahin², Basak Oguz Yolcular³, Muzaffer Sindel¹

¹Department of Anatomy, Faculty of Medicine, Akdeniz University, Antalya, Türkiye

²Department of Radiology, Faculty of Medicine, Akdeniz University, Antalya, Türkiye

³Biostatistics and Medical Informatics specialist, Antalya, Türkiye

Objective: The inferior phrenic artery, a crucial vessel supplying the diaphragm and surrounding structures, exhibits a range of variations in its origin that hold paramount significance in the context of embolization procedures. The aim of our study investigates these anatomical variations through computed tomography examinations.

Methods: In this retrospective study, we examined the variations in the origin and course of the inferior phrenic arteries (IPAs) through computed tomography angiography in 504 potential liver donors (281 female, 223 male; mean age 43.6 years). Computed tomography scans were obtained using a 128-detector computed tomography scanner, and image analysis was performed by experienced vascular imaging radiologists. Variations in the IPAs' origin and branching patterns were assessed using transverse, coronal, and sagittal sections, as well as maximum intensity projection images.

Results: The right IPA is originated from the aorta in 25.8% of cases, from the celiac trunk in 33.1%, and exhibited diverse origins from other arteries. Similarly, the left IPA showed diverse origins, with 20.4% originating from the aorta and 45.4% directly from the celiac trunk. In addition, it was observed that these branches first emerged from the aorta in 17.7% and from the truncus coeliacus in 12.3% as common roots, and then were divided into right and left IPA. Notably, cases of right-to-left branching and accessory arteries were identified.

Conclusion: This study emphasizes the complex anatomical variations in the origin of the inferior phrenic arteries, revealing variations that are important for surgical evaluations and clinical interventions involving the liver and surrounding structures.

Keywords: inferior phrenic artery, anatomical variations, computed tomography angiography, liver transplantation, vascular anatomy

P42 - Evaluation of pain with VAS scale in university students with and without smartphone addiction

Selma Solgun Dağ¹, Davut Özbağ²

¹Department of Anatomy, Faculty of Medicine, Inonu University, Malatya, Türkiye

²Department of Anatomy, Faculty of Medicine, Adiyaman University, Adiyaman, Türkiye

Objective: Although smartphones make our daily lives easier, their uncontrolled use can also cause many physical, psychosocial, mental and cosmetic problems. This study aimed to evaluate pain in university students with and without smartphone addiction.

Methods: This study was conducted with 239 Istanbul Medeniyet University medical faculty students aged between 17-27. In the study age, gender, purpose of smartphone use, smartphone addiction and pain parameters were evaluated. Smartphone addiction was evaluated with ATBÖ-KF and pain with Visual Analogue Scale (VAS).

Results: 131 of the students in the study are women and 108 are men. Students mostly use their smartphones to access social media. 75.5% of women and 91.6% of men are addicted to smartphones. In women, back ($p=0.044$), waist ($p=0.007$), right thumb ($p=0.012$), left thumb ($p=0.041$) and ear ($p=0.024$) pain were significantly higher in smartphone addicts. There is no significant difference in terms of pain areas in men with and without smartphone addiction. However, pain values were higher in those with smartphone addiction.

Conclusion: This study showed that smartphone addiction causes pain in students. If smartphone use is not done in a controlled manner, it may cause bigger health problems in the future. In addition, the time of cell phone use and body position are also factors that will affect the occurrence of pain. There is a need for more comprehensive studies that also evaluate these.

Keywords: pain, smartphone addiction, VAS

P52 - Analysis of the thigh aesthetic profiles: one of physical ideal body proportions

Gkionoul Nteli Chatzioglou¹, Figen Gövsa², Gökhan Gökmen³

¹Department of Anatomy, Faculty of Medicine, Istanbul Health and Technology University, Istanbul, Türkiye

²Department of Anatomy, Faculty of Medicine, Ege University, Izmir, Türkiye

³Faculty of Medicine, Dokuz Eylul University, Izmir, Türkiye

Objective: The aim of this study was to evaluate the thigh, which is one of the ideal body proportions, aesthetically in healthy young individuals.

Methods: Body photographs of the lower extremities of 200 healthy volunteers were obtained. Morphometric measurements such as vertical length (VLT) and transverse width (TWT), inferior and superior lateral width (LWI and LWS), inferior and superior posterior width (PWI and PWS), posterior gluteal angle (PGA) and lateral thigh angle (LAT) were analyzed. Variables related to thigh measurements and body mass index (BMI) were recorded and the relationships between them were determined by Pearson correlation and regression analysis.

Results: The mean LAT and PGA were $168\pm 3.9^\circ$ and $170\pm 3.4^\circ$ in males and $166\pm 2.8^\circ$ and $166\pm 2.8^\circ$ in females, respectively. The LWI/LWS ratio was found to be 0.90 most common (45%) and 0.99 with the lowest incidence 4%. The PWI/PWS ratio was 0.99 most common (84.70%), while the PWI/PWS ratio increased as the LWI/LWS ratio increased. The VLT/TWT ratio ranged between 0.46-0.50 and 0.42-0.45 on the right and left sides, respectively. A strong correlation was found between BMI and all thigh indices, while a significant positive correlation was found between the index and factors related to the hip and upper thigh.

Conclusion: The increasing emphasis on having an ideal thigh form in today's beauty standards has led to increased interest in the development of thigh profiles. However, the current field of cosmetic surgery requires further research and rigorous examination to define the most appropriate techniques and methodologies to evaluate the outcomes of thigh contouring operations.

Keywords: thigh, body contouring, ideal body, cosmetic surgery, aesthetic

P53 - Computer-aided analysis of the ideal umbilicus

Figen Gövsa¹, Gkionoul Nteli Chatzioglou², Gökhan Gökmen³

¹Department of Anatomy, Faculty of Medicine, Ege University, Izmir, Türkiye

²Department of Anatomy, Faculty of Medicine, Istanbul Health and Technology University, Istanbul, Türkiye

³Faculty of Medicine, Dokuz Eylül University, Izmir, Türkiye

Objective: This study aimed to determine the defining characteristics of an ideal umbilicus. In particular, to establish a quantitative index by examining anatomical landmarks on the anterior abdominal wall to determine the normal anatomical position of the umbilicus among young Turkish individuals.

Methods: In this descriptive cross-sectional study, standardized photographs of 63 volunteers, aged 19-21 years, were evaluated. Morphometric and morphological characteristics of the umbilicus were analyzed. To determine the ideal position of the umbilicus, its mathematical relationship with nearby anatomical landmarks such as the xiphoid process (XP), pubic symphysis (PS), anterior superior of the iliac spine (ASIS) and iliac crest (IC) was established. The obtained data were subjected to standard statistical analysis.

Results: Umbilicus were categorized according to their morphological features: vertical-oval (superior hooding) (29%), rounded (27%), vertical-regular (21%), protruding (11%), T-shaped (7%), star/irregular (3%) and lunate (lunar) (2%). The proportions measured between the various anatomical points are as follows:(a/b), distance between the XP and the upper edge of the umbilicus/distance between the lower edge of the umbilicus and the SP was 1.64 ± 0.40 ;(c/d), distance between the lateral edge of the umbilicus and ASIS superior-distance between ASISs was 0.51 ± 0.04 ; (c/b), distance between the lateral edge of the umbilicus and the ASIS - distance between the lower edge of the umbilicus and the PS was 28 ± 0.22 ; (d/f), distance between the SIAS-distance between the inter ASIS and the umbilicus was 5.76 ± 1.90 ; (f/e), distance between the inter ASIS center point and the umbilicus-distance between the inter IC center and the umbilicus was 1.78 ± 0.55 .

Conclusion: This study may help in repositioning the umbilicus for abdominoplasty, and we believe that it will contribute in defining the typical anatomical position and shapes of the umbilicus among Turkish individuals.

Keywords: umbilicus, aesthetic umbilicus, umbilicoplasty, abdominoplasty, morphology

P56 - Total injury of the flexor tendons, which is not noticed due to a small incision the finger, surgery and rehabilitation process: a rare case

Sevda Canbay Durmaz¹, Ali Canbay²

¹Elit Special Education and Rehabilitation Center, Malatya, Türkiye

²Department of Orthopedics and Traumatology, Malatya Battalgazi State Hospital, Malatya, Türkiye

Objective: Since late detection of tendon rupture in the hand and therefore late intervention will cause contracture formation and decline in hand functions, we aimed to emphasize that in traumatic hand injuries, the muscle activity in the hand should be evaluated in detail, without being affected by the size of the incision, and possible tendon damage should not be ignored.

Case: A 56-year-old male patient was admitted to the emergency with a small suture his hand after being stabbed by a cutting tool on his middle finger, and was discharged with a superficial suture to the skin. He went to the orthopedic clinic a week later when he saw that he had lost movement in his finger and there was no improvement. It was understood that there was a total cut of the flexor digitorum superficialis and flexor digitorum profundus tendons in the area. With primary repair using the Kessler method, the structures in the region were preserved and the operation was performed. From the first post-operative day, the physical therapy and rehabilitation process started with early passive mobilization technique along with splint application. Grip and strengthening exercises started at the 12th week. At the end of the 6th month, his hand functions fully recovered and the loss of strength was eliminated.

Conclusion: The hand, which is one of the organs used a lot in daily life activities, can therefore be exposed to a lot of trauma. As in our case, serious injuries can occur even in very small sutures on the hand. However, although post-injury complications were high due to the complex structure of the region, the fact that only the tendons were injured was a rare situation in this case. The success rate increases significantly in tendon injuries where early intervention and the correct rehabilitation program is applied.

Keywords: hand anatomy, tendon injuries, hand surgery

P58 - Comparison of the outcomes of online and face-to-face education in anatomy courses

Elif Sena Ozcan¹, Inci Oktay², Hulya Erbagci¹

¹Department of Anatomy, Faculty of Medicine, Altinbas University, Istanbul, Türkiye

²Department of Public Health, Faculty of Medicine, Altinbas University, Istanbul, Türkiye

Objective: Covid-19 was spread around the world and affected many socioeconomic conditions, especially education. Switching to online education due to Covid-19 has become a much discussed issue. Aim of our study is to investigate the effects of online theoretical and practical anatomy courses during the pandemic on students and compare them with face-to-face education.

Methods: 197 students from Altınbaş University Faculty of Medicine and Dentistry participated in our study. Students were given a survey with questions comparing online and face-to-face education in the anatomy course. Additively, students' exam success scores in the online and face-to-face periods were compared.

Results: The responses "I agree" to "Face-to-face practices, working with cadavers and models helped me understand the subjects better." were significantly high in both faculties (165 students, 83.75%). The answers "I agree" to "Online theoretical courses have reduced the quality of anatomy education." were statistically significant in both faculties and in the distribution according to classes (122 students, 62.56%). The answers "I disagree" to "I prefer online anatomy education to face-to-face education." were found to be statistically significant (106 students, 53.80%). The discriminative and difficulty indexes of the questions in the face-to-face and online exams were compared and no significant difference was detected. Accordingly, when the exam success scores were evaluated out of 100, the average score in online education was 77.74, while the average score was 55.72 in the face-to-face exam.

Conclusion: It has been determined that online theoretical and practical anatomy courses aren't an effective method in both faculties, students prefer face-to-face education to online education, and face-to-face practice provides better understanding of the subjects. Although the discriminative and difficulty indexes of online and face-to-face exam questions are the same, the high exam scores during the online education draw attention to the cheating activities.

Keywords: online anatomy education, covid-19, pandemic

P61 - Three-Dimensional (3D) printing technology in anatomy

F. Fatih Kesmezacar¹, Özge Çoşkun², Duygu Tunçman¹, Cem Kopuz³

¹Istanbul University-Cerrahpaşa School of Health Services, Istanbul, Türkiye

²Department of Anatomy, Faculty of Medicine, Istanbul Arel University, Istanbul, Türkiye

³Department of Anatomy, Faculty of Medicine, Kütahya University of Health Sciences, Kütahya, Türkiye

Objective: 3D printing products are becoming more widespread in education, scientific research, and clinical services, thanks to advances in medical visualization. The aim of this study is to investigate the use of 3D printing technologies in the field of anatomy and the methodological use of the technique in multidisciplinary anatomical studies.

Methods: Studies published on Google Scholar and PubMed search engines were reviewed using keywords such as 3D printing, technology, anatomy, and clinical anatomy.

Results: As a result of the review of publications, it has been seen that 3D printing technologies have been frequently used in anatomical research, practice and training in recent years. However, this technology is also used in various fields of clinical sciences, especially those directly related to anatomy (surgical applications, medical instruments, orthosis-prosthesis production, nuclear medicine phantoms, radiation oncology phantoms).

Conclusion: Advances in 3D printing technology and computer software have increased the use and prevalence of 3D printers in various sectors. The healthcare sector is no exception, with frequent utilization of 3D printing technology. Anatomy, which forms the basis of most health sciences, has also started to utilize this technology. With 3D technology, a new production model and rapid prototyping are achieved by going beyond the standard design and production approach in basic anatomy models. Rapid prototyping provides a cost-effective solution tailored to specific needs. In summary, 3D printing technology in anatomy allows for the cost-effective, efficient, and rapid production of products for education, research, and clinical applications.

Keywords: 3D printer, technology, anatomy, clinical anatomy

P63 - Anatomical formation and clinical importance of facial lines

Furkan Mehmet Özden¹, Serpil Çilingiroğlu Anlı², Ayla Kürkçüoğlu²

¹Department of Anatomy, Faculty of Medicine, Kocaeli University, Kocaeli, Türkiye

²Department of Anatomy, Faculty of Medicine, Kırıkkale University, Kırıkkale, Türkiye

Facial lines are permanent or temporary lines that occur on the forehead, around the eyes, nose, and mouth, depending on the natural structure of the skin or intrinsic and extrinsic factors. These lines are shaped by natural microanatomic structures such as the mechanical tensions the skin was exposed to and the orientation of collagen fibers it contains. Additionally, intrinsic factors such as the aging process, hormonal effects, oxidative stress, as well as extrinsic factors like exposure to ultraviolet radiation, smoking, diet, environmental pollution, sleep, alcohol consumption, and chronic stress can influence the formation of these lines. Knowledge of the anatomical structure of facial lines can be useful in planning and evaluating aesthetic or functional surgical interventions in the region. This topic has long piqued the interest of anatomists. Research into the anatomy of facial lines began with Langer in the 1800s and has evolved with different methods, from puncturing cadavers at frequent intervals with a pointed object to modeling skin lines using 3D simulation. Despite the numerous studies conducted in this field, none of the data on facial lines have yet been universally accepted as the gold standard for surgical incisions and other invasive procedures. These lines are important in surgery for their ease of incision, rapid wound healing, and minimal scar formation. This review aims to compare previous studies on facial lines, elucidate the relationships between effective factors and mechanisms in skin wrinkling and aging within a clinical context.

Keywords: langer's lines, face lines, skin lines, skin tension lines, skin aging

P65 - Clinical significance of crista galli anatomy, types and morphometric features

Meltem Çelik¹, Kadirhan Doğan², Derya Öztürk Süylemez³, Hatice Güler⁴, Mehtap Nisari⁴

¹Radiotherapy Program, Cappadocia Vocational School, Cappadocia University, Nevsehir, Türkiye

²Faculty of Dentistry, Cappadocia University, Nevsehir, Türkiye

³Department of Medical Services and Techniques, Vocational School of Health Services, Sinop University, Sinop, Türkiye

⁴Department of Anatomy, Faculty of Medicine, Erciyes University, Kayseri, Türkiye

Objective: The aim of this study was to examine the anatomical and morphometric features of crista galli (CG) and to emphasize the clinical importance of CG in surgical treatments to be applied to the region by determining the CG types.

Methods: This study was carried out on 5 preserved, unknown adult crania interna in the laboratory of the Department of Anatomy, Faculty of Medicine, Erciyes University. Subjects with fractures, deformations and pathologies in pediatric skull bones, ethmoid bone and CG were excluded from the study criteria. Measurements were made with a Mitutoyo 500-181 150 mm Digital Caliper. CG length (anteroposterior), height (superoinferior) and width (laterolateral) were measured and recorded in mm. The determination of CG types was made according to Moss and those who were “clubbing” by expanding upwards were converted to Type 1; those that rose subtly upwards and were not “clubbing” were categorized into Type 2.

Results: The mean value of CG anteroposterior measurement analyses of the subjects was 15.63 mm (min 13.48 mm, max 18.51 mm); The mean value of laterolateral measurement analyses was 77 mm (min 3.98 mm, max 5.92 mm); The mean value of superoinferior measurement analysis was 9.26 (min 6.91 mm, max 11.16 mm). The percentile values of the CG anteroposterior measurement analyses of the subjects were 17.2%, 23.4%, 18.3%, 23.6% and 17.2% (mean 19.94%), respectively; The percentile values of CG laterolateral measurement analyses were 17.9%, 18.7%, 16.6%, 21.8% and 24.7% (mean 19.94%), respectively, and the percentile values of CG superoinferior measurement analyses were 14.9%, 16.7%, 21.4%, 24.1% and 22.8% (mean 19.98%), respectively. Of the 5 subjects, 1 was in the Type 1 group and 4 were in the Type 2 group.

Conclusion: In this study, CG types, anatomy and morphometry were examined in order to help clinicians in diagnosis and treatment. As a result of our study, it was seen that the CG anteroposterior, laterolateral and superoinferior measurement analyses were compatible with the literature. It was concluded that the medial orbital wall is thicker in Type 1 CG compared to Type 2 CG, which may be especially important during operation. It is thought that continuing the study by increasing the number of subjects will be beneficial to clinicians for the future.

Keywords: crista galli, anatomy, morphometry, treatment

P74 - Case report: High originated deep brachial artery accompanying the brachial plexus variation

İbrahim Kaan Özer¹, Erencan Begiç¹, Turan Koç¹, Zeliha Kurtoğlu Olgunus¹

¹Department of Anatomy, Faculty of Medicine, Mersin University, Mersin, Türkiye

Objective: Prevalence of the deep brachial artery originating from the axillary artery is reported between 2% and 16.6% in some studies. However, knowledge about the accompanied brachial plexus variations are very limited in literature.

Case: During routine right upper extremity dissection of 74 year old female 10% formalin fixed cadaver in Mersin University laboratory, it was determined that the deep brachial artery was originated from the axillary artery as a common trunk with some other arteries, instead of the brachial artery. Deep brachial, anterior circumflex humeral, posterior circumflex humeral and circumflex scapular arteries were originated as a common trunk from the third region of the axillary artery. The fascicles of the brachial plexus were located around this trunk instead of axillary artery. On the other hand, lateral thoracic, thoracodorsal and thoracoacromial arteries were originated as a common trunk in the second region of the axillary artery. The accompanied veins were also showed variation in the case.

Conclusion: It is recommended that such case including the coexistence of vein and nerve variations accompanying the high originated deep brachial artery, should be taken into consideration during axillary nerve block, arterial or venous thrombectomies and lymphadenectomy in cancer surgery related to the axillary fossa.

Keywords: deep brachial artery, axillary artery, brachial plexus, variation, axillary nerve block

P76 - Morphometric description for an unnamed anterior compartment fat pad located subfascially in the mid-lower leg

İnci Kesilmiş^{1,2}, Zeliha Kurtoğlu Olgunus¹

¹Department of Anatomy, Faculty of Medicine, Mersin University, Mersin, Türkiye

²Department of Coaching Education, Faculty of Sports Science, Mersin University, Mersin, Türkiye

Objective: The aim of this study was to morphometrically describe the fat pad, which was found in the anterior compartment of all legs dissected in the anatomy laboratory and was not named although it was present in a dissection atlas in the literature, and to evaluate its possible supportive role to the crural fascia.

Methods: During our another study about the biomechanics of the crural fascia in 20 cadaveric legs (13 male, 7 female, 9 bilateral) fixed with 10% formalin, a fat pad of similar location and varying sizes was encountered deep in the fascia in the anterior compartment of each leg. After the skin was dissected, the fascia was released along the entire leg through a longitudinal incision, following the septum intermusculare cruris anterioris, and deviated medially. The presence of a longitudinally-oriented fat pad, situated superficially between the extensor digitorum longus and tibialis anterior muscles, and located beneath the fascia, was observed in all examined legs. In order to define the location and size of the fat pad, length, width at the widest point, the distance from the lowest point to the intermalleolar line, and the distance of the lower end to the tibia were measured with a digital micrometer. In addition, total limb and leg lengths and skin thickness at the fat pad level were measured. The correlations between these measurements were evaluated by Pearson correlation coefficient.

Results: The location of the fat pad was almost constant for all cadavers and generally similar appearance. The widest part of the fat pad was always in the lower-middle part of the compartment and it was tapering upwards to a flattened shape. The mean length of the fat pad was 107.13 mm, the mean length of the widest part was 11.34 mm, the mean distance from the lowest point to the intermalleolar line was 74.50 mm, and the mean distance from the distal end to the anterior border of the tibia was 13.05 mm. There was no significant correlation between these measurements and limb/leg length or skin thickness.

Conclusion: Considering its location, this structure was named as “subfascial anterior compartment fat pad”. When considered together with the information in our unpublished fascia biomechanics data that the elasticity of the crural fascia decreases distally, it was suggested that this fat pad may have a traction force absorbing function in terms of the force transmitted by the fascia to the bone tissue.

*This study is supported by Mersin University Scientific Research Projects Unit (Protocol number: 2023-1-TP2-4903).

Keywords: fat pad, crural fascia, anterior compartment of the leg, extensor digitorum longus muscle, tibialis anterior muscle

P83 - Anterior and posterior tibial recurrent artery exit patterns and pathways

Mehmet Yilmaz¹, Ali Firat Esmer¹

¹Department of Anatomy, Faculty of Medicine, Ankara University, Ankara, Türkiye

Objective: Anterior and posterior tibial recurrent artery provide part of the nutrition in the inferolateral region of the knee joint. Determining the exit patterns and pathways of these arteries will guide both the approach to condylar fractures and the protection of the artery during trocar entries in knee arthroscopy.

Methods: In our study, 8 cadaver lower extremities fixed with 10 percent formaldehyde were used. In our study, the main arteries from which the recurrent arteries originate, their relationship with the membranous interossea, their exit levels, and their relationships with other arteries that contribute to the inferolateral vascularization of the knee joint were examined.

Results: Anterior tibial recurrent artery emerged from the lower level of the head of fibula, on average -27.48 mm. After its exit point, it gave its branches to the regional structures and proceeded by approaching the inferolateral patella at an average angle of 38 degrees. Posterior tibial recurrent artery emerged from the lower level of the head of fibula, on average -26.28 mm. After the exit point, turned towards the superior tibiofibular joint and made anastomosis in this area.

Conclusion: With our study, the routes and exit patterns of the arteries were better understood and provided guidance for their protection in interventions in this region.

Keywords: anterior tibial recurrent artery, posterior tibial recurrent artery, inferior lateral genicular artery, knee joint

P89 - The relationship between leg length and performance tests of amateur athletes aged 15-18

Nisanur Atlı¹, Fatih Atlı², Ayla Kürkçüoğlu¹

¹Department of Anatomy, Faculty of Medicine, Kırıkkale University, Kırıkkale, Türkiye

²Department of Physical Education and Sports, Faculty of Sports Sciences, Hitit University, Çorum, Türkiye

Objective: Football, which is a universal sport, is a team and contact sport focused on sportive performance and control such as high-level endurance, strength, durability, speed and strategy. Anatomical and physiological characteristics are effective in the athlete's performance. In this context, anthropometric measurements provide very important benefits in terms of clinical and basic research. The purpose of this study is to determine the relationship between leg length and performance tests in amateur athletes.

Methods: 15 female and 15 male athletes, aged between 15 and 18 years, playing amateur football with an average age of 16.70 ± 11.12 (15-18) years, were included in the study. Physical fitness levels of the participants; Body composition, height, weight, waist circumference and leg length were measured. Physical fitness levels related to performance are measured with 100 meter dash, side step 10 meter, T, corioca, slalom and zigzag tests. Statistical analysis of the data we obtained from the data collection tools in our research was carried out using the SPSS Version 22.0 (SPSS Inc Chicago, IL, USA) package program.

Results: Various correlation values were obtained between anthropometric leg length and performance variables. Leg length showed a significant ($p < 0.05$) negative correlation with some performance tests. That is, it has been determined that corioca, T, zigzag and side step 10 meter performances decrease with increasing leg length.

Conclusion: In the light of the findings obtained from the study, the effect of leg length on performance was determined. The training program of athletes need to be planned by evaluating data. Useful that the programs prepared in this context will not only have positive effects on the athlete's performance, but will also be useful in preventing injuries and in the athlete's rehabilitation and return to the field process.

Keywords: anthropometry, football, leg length, performance test

P100 - Evaluation of the course and morphologic features of the mandibular incisive canal and mental foramen in the Turkish population

Neslihan Yuzbasioglu¹, Selva Sen¹, H. Emir Yuzbasioglu², B. Ufuk Sakul¹

¹Department of Anatomy, School of Medicine, İstanbul Medipol University, İstanbul, Türkiye

²Prosthetic Dentistry Specialist

Objective: The aim of this study was to determine the course and morphologic features of the mental foramen (MF) and mandibular incisive canal (MIC) in the Turkish population.

Methods: In this study, 96 Cone Beam Computed Tomography images were retrospectively analyzed. The width and length of the MF, the distance from the MF to the alveolar bone crest, the lower border of the mandible, the angulation of the mental canal to the buccal bone surface, the length of the MIC, the angle of the MF and MIC between a horizontal plane parallel to the lower border of the mandible and the height of the angle were measured. At the endmost point of the MIC, the distance between the mandibular canal and the inferior, labial and lingual borders of the mandible was measured.

Results: The most common sites of MF were along the second premolar (23.4%). MIC was absent in 24.4% of the cases. The most common location of the endmost point of the MIC was along the first incisor (35.8%) and the length of the MIC was significantly longer in males.

Conclusion: Although the structures show variation among individuals, the mean values in Turkish society are similar to the mean values in the literature.

Keywords: mandibular incisive canal, mental foramen, anatomy, CBCT

P102 - Compatibility of anatomical images generated by artificial intelligence with real images

Mert Nahir¹, Bünyamin Şahin²

¹Department of Anatomy, Faculty of Medicine, Tokat Gaziosmanpaşa University, Tokat, Türkiye

²Department of Anatomy, Faculty of Medicine, Ondokuz Mayıs University, Samsun, Türkiye

Objective: Artificial intelligence has widespread applications today, including the ability to generate images through commands. However, there have been very few studies on the feasibility of generating anatomical images through commands using artificial intelligence. This study aims to investigate the compatibility of anatomical images generated by artificial intelligence with real images.

Methods: In this study, commands were given to the Midjourney, Bing, and CapCut programs to generate anatomical images. The same commands were applied to all three artificial intelligence tools. The results were evaluated in terms of the compatibility of the generated images with real images and the resemblance of anatomical structures to reality.

Results: All three artificial intelligence tools were unable to generate the desired images according to the given commands. Drawings such as the isolated skeletal system, muscles, isolated liver, and digestive organs showed very little similarity to anatomical images.

Conclusion: The findings obtained indicate that artificial intelligence tools capable of generating images through commands are not yet ready to produce anatomical images.

Keywords: anatomical illustration, artificial intelligence, Midjourney, Bing, CapCut

P103 - Term definition study (Turkish and Latin) for the hand area of the cardiac massage practitioner in contact with the patient's chest

Ismihan Ilknur Uysal¹, Abdullah Taha Talan¹, Ummuhan Yagmurkaya²

¹Department of Anatomy, Faculty of Medicine, Necmettin Erbakan University, Konya, Türkiye

²Department of Anatomy, Faculty of Medicine, Ankara Medipol University, Ankara, Türkiye

Objective: The area where power is transferred from the practitioner's hand to the patient's chest, known to be important for an effective heart massage, is defined as the "heel of the hand" in English guidelines. There is no standard term for this region in both Terminologia Anatomica and Turkish guidelines. This study, aims to standardize the definitions used in the manuals to propose a term (Turkish/Latin) and raise awareness in order to better understand the correct position of the hand.

Methods: An online survey was shared with healthcare professionals and medical school students via various applications of social media from February to May 2023. In the survey, 3 questions were asked about the unit in which the participants actively worked and the Turkish and Latin naming options of the hand area used in heart massage.

Results: 444 people participated in the survey. 2% of the participants were emergency medicine specialists, 6% were general practitioners, 10% were anatomy specialists, 15% were physicians working in other specialties, and 67% were students. The distribution of physicians in other specialties was as follows; 48% internal medical sciences, 23% surgical medical sciences, 29% basic medical sciences. For the Turkish term for the hand area used in heart massage, the definitions were palm (51%), heel of the hand (31%) and root of the hand (18%), respectively. For the Latin term for the hand area used in heart massage, the definitions eminentia palmare (44%), tuber palmare (35%) and radix palmare (21%) were preferred, respectively.

Conclusion: When the participants' answers are evaluated, we believe that it would be beneficial for healthcare professionals to create Latin and Turkish terms for the correct understanding of the defined hand area in order to increase the effectiveness of heart massage and minimize possible misapplications.

Keywords: heel of hand, palm, heart massage

P108 - Do anatomists neglect the middle hepatic artery?

Tuğçe Taşkindere Abbasoğlu¹, Ayşegül Fırat¹

¹Department of Anatomy, Faculty of Medicine, Hacettepe University, Ankara, Türkiye

Objective: The middle hepatic artery (MHA) is the principal artery for liver segment 4. This segment has a peculiar pattern of arterial supply that is distinct due to its earlier branching in comparison with the portal vein supply. There is relatively little information on the MHA compared with the left and right hepatic arteries (LHA and RHA). The aim of this study was to revisit the clinical importance of MHA.

Methods: A comprehensive literature review was performed using Pubmed and Google Scholar websites.

Results: Michels classified the hepatic arteries and argued that MHA originates equally from LHA and RHA. In the field of anatomy, this artery has been referred to as A4 and has been observed to originate from LHA in 54-61.5% of cases. However, MDCT studies have shown that 62.5% of cases are originated from RHA. Variants originating from the proper hepatic artery, from LHA in the presence of replace RHA, from RHA in the presence of replace LHA, from a replaced artery in the case of being replaced of both arteries and also from the pancreaticoduodenal artery in one case report were shown. Injuries to MHA during living donor liver transplantation (LDLT) can lead to a decrease in the functional volume of the left hepatic lobe and a reduced blood supply to the bile ducts. The extended right lobe graft may threaten the safety of the donor if ischemic damage occurs. The A4s variant originating from the right anterior hepatic artery is considered the most dangerous, due to its potential to cause ischemic changes in the reserve portion of the liver after right hepatectomy.

Conclusion: Although the middle hepatic artery is not discussed in many anatomy textbooks, the clinical implications of this artery have been extensively discussed in the literature. It is not unusual to encounter MHA variants, and the assessment of anatomical variants is crucial when considering potential donors and recipients for LDLT and split liver transplantation.

Keywords: middle hepatic artery, segment 4 artery, left hepatic artery, right hepatic artery, LDLT, split liver transplantation

P109 - Examination of brain volumes of individuals who applied to the hospital with complaints of headache or dizziness

Nuriye Öz¹, Kamil Karaali², Nigar Keleş-Çelik¹

¹Department of Anatomy, Faculty of Medicine, Akdeniz University, Antalya, Türkiye

²Department of Radiology, Faculty of Medicine, Akdeniz University, Antalya, Türkiye

Objective: In recent years, automatic segmentation methods for brain segmentation have been described as fast, reliable and economical methods. Automatic segmentation methods can be used for the detection or early diagnosis of diseases that affect some small-volume structures in the brain. In our study, we aimed to examine some small-volume brain regions of individuals who were admitted to the hospital with complaints of headache or dizziness but did not receive any diagnosis, with MRICloud software.

Methods: Magnetic resonance images (1mm) of healthy individuals without any neurological or psychiatric diseases were included in our study by retrospectively scanning them. Dizziness (N:8, Mean age: 61.6) and Headache (N:8, Mean age: 58.7) groups were selected according to their complaints at the time of application. The volumes of brain structures were measured with MRICloud software, an automatic segmentation method. Both groups were compared.

Results: Right gyrus parahippocampalis and right entorhinal cortex volumes were found to be significantly smaller in the headache group than in the dizziness group ($p < 0.05$). Right thalamus and right nucleus ruber volumes were found to be significantly smaller in the dizziness group than in the headache group ($p < 0.05$).

Conclusion: We concluded that in the headache group, significant shrinkage in structures related to the limbic system may affect mood and manifest as headache symptoms, while in the dizziness group, significant shrinkage in gray matter structures such as thalamus and nucleus ruber may cause problems with motor control and coordination. We think that MRICloud software can contribute to the early diagnosis process by detecting changes in some structures before individuals show any major findings (depression, vertigo, etc.).

Keywords: MRICloud, magnetic resonance imaging, volume

P117 - Evaluation of reliability and quality of YouTube videos about larynx anatomy

Songul Cuglan¹

¹Department of Anatomy, Faculty of Medicine, İstanbul Beykent University, İstanbul, Türkiye

Objective: This study aims to evaluate the content, quality and functionality of YouTube videos on the anatomy of larynx and to measure educational usefulness of the videos.

Methods: In this cross-sectional study, searches were made using the keywords “larynx anatomy” in the YouTube search tab. The quality and content of the videos were evaluated using the Anatomical Content Score (ACS), modified DISCERN scale, JAMA score and Global Quality Scale (GQS). SPSS 26.0 software was used for statistical analysis.

Results: According to GQS criteria, videos were divided into two groups as useful and not useful for education. 13 (46.5%) of the videos were in the useful group and 15 (53.5%) were in the not useful group. The length of the videos in the useful group was determined to be statistically higher ($p=0.001$). There was no statistically significant difference between the two groups in terms of the number of comments on the videos ($p>0.05$). It was determined that the ACS evaluation in the useful group was significantly higher ($p = 0.001$). There was no statistically significant difference between the useful or not useful of the videos examined in modified DISCERN and JAMA evaluations ($p>0.05$). A strong statistically positive correlation was determined between GQS and ACS evaluations ($r=0.959, p<0.001$). A statistically significant correlation ($r=0.123, p>0.05$) was detected between modified DISCERN and JAMA evaluations. Additionally, a strong statistically positive correlation were determined between modified DISCERN and GQS evaluations ($r=0.880, p<0.001$).

Conclusion: The majority of YouTube videos have insufficient information on larynx anatomy in the medical school curriculum. Anatomists should be aware of the contents of video sharing platforms and direct students to accurate and reliable e-information sources. We also think that it would be beneficial for anatomists to prepare and present YouTube videos with evaluation systems such as modified DISCERN, JAMA, GQS, ACS.

Keywords: YouTube, anatomy, medicine education, evaluation

P122 - Demonstration of the therapeutic effect and mechanism of action of basil (ocimum gratissimum) in acute (acetyl salicylic acid) and chronic (stz-streptozocin) experimental tinnitus models created experimentally in rats with its anti-glutaminergic effect and monitoring of tinnitus in rats with EEG

Mehmet Bülent Özdemir¹, Ahmet Kutluhan², Semin Fenkçi³, Gülçin Abban Mete⁴

¹Department of Anatomy, Faculty of Medicine, Pamukkale University, Denizli, Türkiye

²Department of NTE, Faculty of Medicine, Pamukkale University, Denizli, Türkiye

³Department of Endocrinology, Faculty of Medicine, Pamukkale University, Denizli, Türkiye

⁴Department of Histology and Embrology, Faculty of Medicine, Pamukkale University, Denizli, Türkiye

Objective: Tinnitus is defined as the perception of sound in the absence of an external source. It can be objective or subjective. Objective tinnitus is a perception of sound that can also be heard by the examiner and is often dependent on blood flow or muscle movement. There is no standard procedure for the diagnosis or treatment of tinnitus. Because the pathways in its pathophysiology have not been fully elucidated. The presence of excitotoxic effects in auditory pathways has increased interest in its potential to treat tinnitus by blocking glutamate binding sites. Glutamate receptor antagonists are therefore a potentially useful and sensible approach to drug therapy for tinnitus. Our aim in the planned study is to create experimental acute and chronic tinnitus models in rats, monitor them with EEG and show the therapeutic effect of Basil with antiglutaminergic effect.

Methods: For this, control, sham and experimental groups, each consisting of 6 rats, will be created. In the experimental groups, the experimental acute Tinnitus group will be formed with acetyl salicylic acid. Chronic Tinnitus group will be created with STZ. Both groups will be given basil extract therapeutically. Changes in glutamate and GABA parameters will be monitored and these will be correlated with EEG results. ANOVA will be used to evaluate the statistical significance of the experimental results.

Conclusion: Excessive glutamate production and overexpression and overexpression of NMDA glutamate receptors in the cochlea cause excitotoxicity when inner hair cells are damaged, for example as a result of noise exposure, ototoxic drugs, or disease. This triggers excessive calcium entry into primary auditory neurons, followed by osmotic swelling and cell lysis. There is currently no standard treatment for tinnitus. In fact, current practice guidelines advise against the routine use of any medication, such as antidepressants or anxiolytics for tinnitus. A drug that affects the change in neural activity that produces tinnitus is required. This could be basil.

Keywords: tinnitus, basil, acetyl salicylic acid, streptozotosin

P127 - Do the morphological characteristics of the canalis carpi during the embryological period differ according to gender and hand side?

Mehtap Kondak¹, Nevnihal Akbayturk², Mehmet Haluk Uluutku³

¹Vocational School of Health Services, Avrasya University, Trabzon, Türkiye

²Department of Anatomy, Faculty of Medicine, Giresun University, Giresun, Türkiye

³Department of Anatomy, Faculty of Medicine, Uşak University, Uşak, Türkiye

Objective: In this study, in order to investigate the development of morphological characteristics of canalis carpi in embryological period, it was aimed to determine the area covered in the wrist, wrist ratio, and canalis carpi ratio.

Methods: The wrists of 26 fetal cadavers with a mean intrauterine age of 28.2 weeks were dissected, the level of canalis carpi was determined. Transverse sections were obtained from the determined level and photographed. The cross-sectional area of the wrist, cross-sectional area of canalis carpi, height and width of the wrist, and height and width of canalis carpi were measured with ImageJ. The ratio of the area of canalis carpi within the wrist, wrist ratio, and canalis carpi ratio were calculated. The data were statistically compared according to gender and hand side.

Results: The area of canalis carpi in the wrist was 5.208 ± 0.832 and 4.963 ± 1.027 ($p:0.363$); wrist ratio was 0.606 ± 0.095 and 0.637 ± 0.096 ($p:0.287$); canalis carpi ratio was 0.401 ± 0.074 and 0.392 ± 0.087 ($p:0.360$) for female and male fetuses, respectively. The difference between male and female fetuses in terms of obtained rates wasn't statistically significant ($p>0.05$). The area of canalis carpi within the wrist was 5.075 ± 0.948 and 5.180 ± 0.862 ($p:0.680$); wrist ratio was 0.618 ± 0.098 and 0.615 ± 0.095 ($p:0.925$); canalis carpi ratio was 0.398 ± 0.085 and 0.398 ± 0.071 ($p:0.988$) for right and left sides, respectively. No statistically significant difference was found when the data were compared according to hand sides ($p>0.05$).

Conclusion: The values obtained in the study were similar to the values reported in the literature for healthy adult individuals; however, unlike the literature, there wasn't significant difference between male and female. We think that the data obtained from fetal cadavers not exposed to environmental factors and using will contribute to the literature on the morphology and development of canalis carpi in embryological period.

Keywords: cadaver, carpal tunnel syndrome, hand, wrist

P129 - Evaluation of arteria mesenterica inferior and its branching pattern by magnetic resonance angiography

Necmi Keskin¹, Belgin Bamac¹, Ozgur Cakir², Tuncay Colak¹, Abdullah Ors¹, Cagatay Barut³

¹Department of Anatomy, Faculty of Medicine, Kocaeli University, Kocaeli, Türkiye

²Department of Radiology, Faculty of Medicine, Kocaeli University, Kocaeli, Türkiye

³Department of Anatomy, Faculty of Medicine, Istanbul Medeniyet University, Istanbul, Türkiye

Objective: The aim of this study was to determine the position, angle of origin and location of the inferior mesenteric artery (IMA) using magnetic resonance angiography (MRA).

Methods: 185 patients were retrospectively analyzed for the sagittal origin angle (OA), distance to other major branches of the abdominal aorta (AA) and level of origin of the IMA according to vertebral column on MRA images. The data obtained were analyzed in relation to age and gender using SPSS 25.0. Independent sample t test was used for independent two-group comparisons of normally distributed variables and Mann Whitney U test was used for non-normally distributed variables. Spearman correlation test was used to determine the relationship between continuous variables. Chi-square test was used to compare categorical variables. For all statistical comparisons, $p < 0.05$ was accepted as statistical significance.

Results: IMA-celiac trunk (CT), IMA-right renal artery (RRA), IMA-left renal artery (LRA) and IMA-aorta bifurcation (AB) parameters were compared according to gender. It was found that the values obtained from males were larger than females and the differences between them were statistically significant ($p < 0.05$). A low level of positive correlation was found between age and IMA-OA in males ($r = 0.296$, $p = 0.002$). A low level of positive correlation was found between age and IMA-OA in the whole group ($r = 0.296$, $p = 0.003$). The most common origin level of IMA in both sexes was found to be L3 middle. When the distribution of the origin level of IMA according to gender was evaluated, it was found that the difference between genders was not statistically significant ($X^2 = 12,573$, $p = 0,250$).

Conclusion: The fact that the angle of origin of IMA and its relationship with other branches of AA differ according to age and gender, emphasises the importance of individual assessment before interventions related to this structure.

Keywords: inferior mesenteric artery, mr angiography, origin angle, abdominal aorta

P136 - Association of Klippel-Feil syndrome and Duane syndrome: Case report

Sevdenur Bekam¹, Burak Karip², Sevim Yener³, Nurullah Yucel²

¹Anatomy Master's Program with Thesis, Hamidiye Health Sciences Institute, Sağlık Bilimleri University, Istanbul, Türkiye

²Department of Anatomy, Faculty of Medicine, Sağlık Bilimleri University, Istanbul, Türkiye

³Clinic of Pediatric Urology, Umraniye Training and Research Hospital, Sağlık Bilimleri University, Istanbul, Türkiye

Objective: Klippel-Feil syndrome is a rare genetic syndrome that occurs in approximately 1/40,000 newborns when we look at its worldwide prevalence and causes bone anomalies and limitation of movement in the cervical region. Although many symptoms are mentioned in the reviewed sources, the defined and visible classical triad of this disease is; a very short neck, low hairline, and limited neck movements. It is observed that congenital disorders of organs and extraskelletal structures accompany these anomalies. Our study aims to reveal the findings, especially regarding anatomical structures, of a case diagnosed with Klippel-Feil Syndrome.

Case: Our case is a 9-year-old boy. He was admitted to the hospital with complaints of short stature and suspected scoliosis. In addition, lateral gaze paralysis was detected in the patient, and various examinations were performed to identify vertebral anomalies. Magnetic resonance (MR) imaging, one of the examinations performed, revealed images thought to be fusion in some cervical vertebrae (especially the corpus). Orthopedic examinations revealed cervicothoracic scoliosis. These findings of Klippel-Feil syndrome were accompanied by pathologies such as kyphosis, syringomyelia and very short neck (common in recessive inheritance) detected on radiographs from different angles. In other examinations, Duane syndrome, which is associated with hearing disorders and especially visual impairment, was also detected. A narrowing of the anterior subarachnoid space was also observed due to hypertrophy of the transverse ligament of the atlas as well.

Conclusion: The examinations performed, the patient's findings, and the patient's genetic test result; It fully confirm that our case is a patient with Klippel-Feil syndrome. It seems that the symptoms and pathologies of the syndrome, which are rarely detected in the literature, are compatible with the case we examined. The most striking of these is that the disease is accompanied by Duane syndrome.

Keywords: Klippel-Feil syndrome, Duane syndrome, scoliosis, anatomy

P137 - The effect of pes equinovarus on the myotonometer characteristics of leg surface muscles, calcaneal tendon, and plantar fascia: A preliminary study

Rabia Taşdemir¹, Rukiye Çiftçi¹, Nevzat Gönder², Ömer Faruk Cihan³, Zeynep Şencan³, Cansu Öztürk¹, Ebru Sena Çalışır¹

¹Department of Anatomy, Faculty of Medicine, Gaziantep Islam Science and Technology University, Gaziantep, Türkiye

²Department of Orthopedics and Traumatology, Faculty of Medicine, Gaziantep Islam Science and Technology University, Gaziantep, Türkiye

³Department of Anatomy, Faculty of Medicine, Gaziantep University, Gaziantep, Türkiye

Objective: Pes equinovarus, anomalies in muscle and tendon development resulting in one of the most common congenital deformities of the foot. There is no valid, reliable, and practical tool available in the clinical setting to record muscle tone. Muscle Stiffness is caused by the deformation of actin-myosin cross-bridges and the associated force. Therefore, muscle stiffness can be used as an indicator that replaces changes in muscle strength production. MyotonePRO measures the tone, stiffness, and elasticity of the muscle. Considering that all muscles in the leg, including those responsible for foot movement, may be affected by pes equinovarus, we aimed to evaluate the leg muscles, tendons, and foot fascia structure using the MyotonePRO device. When a single muscle, synergistic or antagonistic muscle is stimulated between a single or adjacent limb segment, and considering the direction of specific movement and the transmission of force between muscles, we hypothesized that all muscles in the leg, including those responsible for foot movement, could be affected by pes equinovarus and aimed to evaluate the leg muscles, tendons, and foot fascia structure using the MyotonePRO device.

Methods: In this study, we measured the stiffness, tone, and elasticity of tibialis anterior, soleus, gastrocnemius muscles, calcaneal tendon, and plantar fascia using the MyotonePRO device in children aged 0-2 years diagnosed with pes equinovarus who presented to the Orthopedics and Traumatology clinic of İnyet Topçuoğlu Municipal Hospital before undergoing Achilles tendon release surgery (tenotomy), as well as in a control group, while in a lying position.

Results: As preliminary findings of the planned study, data were obtained from 14 children (7 females, 7 males). Among these children, 9 were diagnosed with pes equinovarus, while 5 had no pathology related to the lower extremity musculoskeletal system. Among the children, 7 had bilateral pes equinovarus, while 2 had it only on the right side. When tone was examined from myotonometer measurements, it was observed that in the patient group, tibialis anterior, gastrolateral muscles, and calcaneal tendon had higher measurements, while gastromedial and soleus muscles had higher measurements in the healthy group. In the analysis of dynamic stiffness, it was determined that all parameters except the right plantar fascia were higher in the patient group. In elasticity measurements, values of gastrolateral muscle and calcaneal tendon on the right side and soleus muscle and plantar fascia on the left side had higher values in the patient group, while other values were measured higher in the healthy group.

Conclusion: Since the success of conservative treatment depends on the patient's morphology, morphometric measurements should be taken from the patient before and after treatment. The results obtained may provide insights into the effective treatment of pes equinovarus in the future.

Keywords: pes equinovarus, myoton, calcaneal tendon, plantar fascia, superficial leg muscles

P139 - Retrospective evaluation of age, gender and side differences of acromial index using three-dimensional reconstruction method

Gülnur Diner¹, Ender Uzabacı², Gökhan Gökalp³, Senem Turan Özdemir¹

¹Department of Anatomy, Faculty of Medicine, Uludag University, Bursa, Türkiye

²Department of Biometry, Faculty of Veterinary Medicine, Uludag University, Bursa, Türkiye

³Department of Radiology, Faculty of Medicine, Uludag University, Bursa, Türkiye

Objective: Acromial index (AI) is a scapular morphological parameter emphasized as a determinant of rotator cuff tear. AI is defined as the ratio of the distance from the glenoid plane to the lateral border of the acromion to the distance from the glenoid plane to the most lateral aspect of the humeral head. The aim of the study is to measure AI on images obtained from shoulder CTs with the 3D reconstruction method, taking into account gender and side differences and taking into account age-related changes.

Methods: This study was conducted with a total of 58 patients ((18-80, mean age: 37.79), 41 men and 17 women, who presented with shoulder pain and/or fracture suspicion and whose glenohumeral joint and acromioclavicular joint were reported to be normal. AI measurement was made on the images obtained from shoulder CTs with the 3D reconstruction method, taking into account gender and side differences. Independent samples t test and Spearman correlation analysis were used in statistical evaluation.

Results: In the study, the AI was determined to be 0.62 in men and women. Acromial index did not show a significant difference between both gender and sides (right-left) ($p = 0.747$) ($p = 0.205$). When both genders were examined separately and regardless of the gender variable, no significant relationship was found between AI and age. When the side variable was taken into account and the evaluation was made without considering the side difference, no significant relationship was found between AI and age.

Conclusion: This study investigated AI in a sample of the Turkish population and the results were found to be consistent with those reported in the literature. Evaluation of AI is important in revealing inter-population differences, clarifying its relationship with shoulder pathologies, and appropriate prosthesis design and placement in shoulder arthroplasty.

Keywords: acromial index, shoulder, acromion, acromial morphology

P140 - Frequency of nonmetric variations in late Byzantine period (13th century AC) atlases

Gizem Çetin¹, Nilgün Tuncel-Çini², Gülnur Diner¹, Senem Turan Özdemir¹

¹Department of Anatomy, Faculty of Medicine, Bursa Uludag University, Bursa, Türkiye

²Department of Anatomy, Faculty of Medicine, Bilecik Seyh Edebali University, Bilecik, Türkiye

Objective: Nonmetric variations reflect the population characteristics of osteological formations and guide for anthropological evaluations and approaches; they are nonmetric, observational predictors that provide information about genetic relatedness and evolutionary process. Arcuate foramen, divided superior facet, posterior cleft of atlas, incomplete foramen transversarium are some nonmetric variations defined on the atlas. The aim of the study is to determine the variations and their frequency of occurrence on atlases from the Byzantine period through observation.

Methods: In this study, the frequency of occurrence of nonmetric variations on a total of 54 atlases from the Late Byzantine Period (13th century AD) in the bone collection of Bursa Uludag University was evaluated by observation, and the detected variations were photographed.

Results: Arcuate foramen 10 (18.51%), posterior cleft of C1 1 (1.85%), incomplete foramen transversarium 1 (1.85%), posterior arch foramen 1 (1.85%), incomplete posterior arch foramen was detected 1 (1.85%) and divided superior facet 1 (1.85%) on atlas. While the arcuate foramen was found bilaterally in 6 of the atlases, it was found unilaterally in 4 of them, 3 of them on the right and 1 of them on the left. On an atlas, arcuate foramen and divided superior articular facet were observed together.

Conclusion: Nonmetric variations are markers that provide information about populations. Knowing the variations is also important for differential diagnosis in some clinical situations. Posterior cleft of C1 can easily be confused with a fracture. In patients suffering from neck pain, shoulder pain, vertigo and headache, clinicians should be aware of these abnormal bone formations.

Keywords: atlas, nonmetric variations, arcuate foramen, foramen transversarium, anatomic variation, Byzantine period

P145 - Bibliometric analysis of doctoral theses in the field of anatomy

Gülay Madan¹

¹Orthopedic Prosthesis Orthosis Program, Atatürk Health Services Vocational School, Afyonkarahisar Health Sciences University, Afyonkarahisar, Türkiye

Objective: The main aim of this study is to examine the content of doctoral and medical specialization theses conducted in the field of anatomy between the years 2019-2023 based on various variables.

Methods: The data were obtained through a search conducted in the National Thesis Center Archive of the Council of Higher Education. During this search, the methods used in doctoral and medical specialization theses under the anatomy department, universities involved, and their status over the years were meticulously examined.

Results: A total of 193 theses were identified in the field of anatomy between 2019 and 2023, consisting of 161 doctoral theses. The distribution of theses by year was as follows: 2019 (33), 2020 (29), 2021 (47), 2022 (58), and 2023 (33). It was observed that the theses were conducted in 36 different universities. The universities with the highest number of theses published were Erciyes (22), Inonu (12), Istanbul Medipol (10), Ondokuz Mayıs (10), Selcuk (10), Ankara (9), Ege (9), Akdeniz (8), Cukurova (8), Kocaeli (8), Hacettepe (7), Eskisehir Osmangazi (7), and Istanbul-Cerrahpasa (7). Six different main methods were identified as primarily used in the relevant thesis studies. The most commonly used methods were radiological studies at 89, animal experiments at 39, cadaver studies at 36, and anthropometric measurements at 26. Cellular studies were used in 4 of the studies, and survey studies were found in 4. It was observed that the majority of radiological studies used in the theses were conducted using Computerized Tomography in 39 (43.8%) and Magnetic Resonance Imaging in 33 (37.1%) methods.

Conclusion: This research has examined the current status of doctoral and medical specialization theses conducted in the field of anatomy in Turkey. The study is believed to contribute to the planning and direction of new studies in the field of anatomy.

Keywords: bibliometric analysis, anatomy, doctoral theses

P148 - Evaluation of distance and formal anatomy education in vocational school of health services students

Özge Coşkun¹, Özgü Kesmezacar², Fatih Kesmezacar³

¹Department of Anatomy, Faculty of Medicine, Istanbul Arel University, Istanbul, Türkiye

²Istanbul Provincial Health Directorate, Kartal District Health Directorate, Istanbul, Türkiye

³Cerrahpaşa School of Health Services, Istanbul University, Istanbul, Türkiye

Objective: In this descriptive study, the effectiveness of formal and online education for associate degree students taking anatomy courses was examined. In the 2020-2021 academic year; it was aimed to evaluate anatomy course's efficiency among first-year students who took anatomy course online and second-year students who took the course as formal education the previous year, to determine problems they experienced in anatomy courses and raise awareness about future of online education.

Methods: Online survey form regarding anatomy education was distributed to students. To ensure the reliability of feedback, students were asked not to write their names. Survey consisted of questions regarding the understandability of anatomy course, the course's importance, and problems experienced by students. Answers given were collected and recorded electronically. Descriptive statistics (number, percentage) and Chi-square test were used to analyze data.

Results: Difficulty in learning anatomy course despite the same resources and course hours was 82.8% in online education students and 59.4% in formal education students and the difference between them was statistically significant($p<0,05$). To the removal of anatomy course from compulsory courses, 51,7% of the students receiving online education and 81.2% of the students receiving formal education answered no($p<0,05$). Of the online education students, 37.1% didn't have computer, smartphone or tablet, 19.8% had internet connection problems and 12.1% didn't have suitable study environment.

Conclusion: The study found that online education, which was implemented in our country after the earthquake disaster and pandemic and is thought to be more on the agenda in the near future, made learning for the anatomy course difficult. Limited face-to-face interaction hindered students' comprehension of the course's significance, impeded active participation, and disrupted course flow due to technical issues. Issues like infrastructure shortcomings, restricted resources, and unequal access to opportunities were identified as problems within distance education.

Keywords: online education, anatomy education, covid-19

P149 - Subarachnoid cisterns: Is there a difference between anatomical and clinical descriptions?

Gizem Serpil Balyemez¹, Çağatay Barut¹

¹Department of Anatomy, School of Medicine, Istanbul Medeniyet University, Istanbul, Türkiye

Objective: Subarachnoid cisterns are important structures for neurosurgery and radiology, where cerebrospinal fluid and important nerves and vessels are located, and they are also important in anatomy. Similarities and disparities in anatomy, radiology and neurosurgery sources were investigated in terms of definitions, naming and synonymous uses of cisterns.

Methods: Manuscripts and books containing the term “subarachnoid cistern” were searched using Google Scholar, Pubmed and Web of Science. Seven anatomy and nine clinical sources published in English were evaluated. The names, definitions and synonymous uses of cisterns were evaluated. Categorical variables were evaluated with the Chi-square test.

Results: A total of 48 cisterns were encountered. 11 cisterns (“superior cistern”, “prechiasmatic cistern”, “postchiasmatic cistern”, “supracallosal cistern”, “cerebellopontine angle cistern/angle cistern”, “peripineal cistern”, “pineal cistern”, “perimesencephalic cistern”, “cisterna hypophysialis”, “cisterna sulci centralis”, “cisterna meati acustici interni”) were not stated in clinical sources; 8 cisterns (“callosal cistern”, “lateral mesencephalic cistern”, “oculomotor cistern”, “supracerebellar cistern”, “medullary cistern”, “posterior communicating cistern”, “PICA cistern”, “cistern of corpus callosum”) were not mentioned in anatomy sources. The frequency of “cistern of the lateral fossa”, “cistern of the great cerebral vein” and “superior cistern” were higher in anatomy resources with statistical significance ($p < 0.05$). The synonymous uses of “cisterna magna” and “cerebellomedullary cistern”; “cistern of the lateral fossa” and “sylvian cistern”; “quadrigeminal cistern”, “superior cistern”, “vein of Galen cistern”, “peripineal cistern” and “pineal cistern” were more common in anatomy sources with statistical significance ($p < 0.05$).

Conclusion: Detected disparities in anatomy and clinical resources could be explained by differences in the topographic definitions of anatomy and the terms that provide ease of use in clinical practice. The terminological difference between anatomy and clinical branches needs to be fixed to prevent possible improper usage. An agreement between the basic and clinical sciences considering clinical definitions is suggested to be crucial to name the cisterns properly.

Keywords: subarachnoid cistern, arachnoid trabeculae, definition, terminology

P150 - Round ligament varices as a cause of inguinal swelling during pregnancy

Gamze Uyanık Yılmaz¹, Bilge İpek Torun², Mehtap Balaban³

¹Obstetrics and Gynecology Clinics, Ankara City Hospital, Ankara, Türkiye

²Department of Anatomy, School of Medicine, Ankara Yıldırım Beyazıt University, Ankara, Türkiye

³Department of Radiology, School of Medicine, Ankara Yıldırım Beyazıt University, Ankara, Türkiye

Objective: Round ligament varices (RLV) are a rare condition and almost always occur during pregnancy. It is important to diagnose so that the patient is not subjected to surgery unnecessarily, as it can be confused with inguinal hernia, lymphadenopathy, cystic lymphangioma, and endometriosis, which cause swelling in the groin and require surgical treatment, and can resolve on their own. We aimed to describe the sonographic features of RLV.

Case: Two pregnant women, who applied to the hospital with complaints of pain and a soft swelling in the groin that increased during the day, were followed up with the preliminary diagnosis of small-sized inguinal hernia, or lymphadenopathy. Radiological examinations of the patients were performed using ultrasound (US). No obvious hernia was detected in the physical examination of either patient. With the Valsalva maneuver, increase in the size of the swelling was detected in both patients. In inguinal US in both patients, heterogeneous hypo-anechoic lesions and intramural slow flow were observed, consisting of multiple dilated varicose vessels with diameters ranging from 12.5 to 17mm at the widest point, extending into the canal. It was observed that lymphadenopathy or bowel loops did not accompany the swelling. In the color Doppler US (CDUS), the presence of venous flow was observed within the vascular structures.

Conclusion: RLV is an important entity that should be kept in mind because they are rarely seen during pregnancy, can go away on their own after pregnancy without treatment, but are located in the same location and can sometimes be confused with inguinal hernia or lymphadenopathy, which sometimes need to be treated surgically. Characteristic US findings are a slowdown in intramural flow accompanied by dilated veins and the presence of smaller varices observed on CDUS. Shape change with positional and Valsalva maneuver are diagnostic.

Keywords: inguinal hernia, lymphadenopathy, Doppler ultrasound, groin swelling, pelvic anatomy

P151 - Auricular types in normal and anomalous fetuses

Evrım Güneş¹, Özlem Elvan², Alev Örs³

¹Department of Anatomy, Institute of Health Sciences, Mersin University, Mersin, Türkiye

²Mersin University, İçel Health College, Mersin, Türkiye

³Department of Anatomy, Faculty of Medicine, Mersin University, Mersin, Türkiye

Objective: The research goal is to examine the auricular types in fetal groups with normal and anomalous (limb anomalies like polydactyly, syndactyly, facial anomalies like cleft lip and palate) in terms of morphological appearances.

Methods: In this study, a total of 98 auricles from 55 fetal cadavers (16-40 gestational week) were examined. Auricles were classified based on deformations described in the literature (Stahl's, Lidding, Cup, Constricted, Conchal Crus, Inverted Conchal Bowl).

Results: Out of the 55 fetuses, 50 were normal, 5 were anomalous. Auricles of 2 anomalous fetuses were bilaterally normal. 1 fetus had normal auricle in a side and deformity in the other. 2 of the anomalous fetuses had only one auricle due to prior dissections, with one being normal and the other exhibiting deformity. In 4 of the normal fetuses, one auricle was normal while the other had a deformity. Ten of the normal fetuses had only one auricle, with 6 being normal and 4 exhibiting deformities. In normal fetuses, 32 auricles had no deformity. Among the auricles with deformities, some exhibited a single type of deformity, while some had two different deformities on the same side. Helix deformities were observed in 2 auricles and a 3rd crus was seen in the antihelix of 3.

Conclusion: In anomalous fetuses, normal auricles were observed in 75%, while, it was 35.5% in normal fetuses. Deformities were found in 25% among 5 anomalous fetuses, whereas it was 64.4% among the 50 normal fetuses. Multiple auricular deformities at the same side were not observed anomalous fetuses, while, this constituted 13.79% of auricular deformities in normal fetuses. The most commonly observed deformity in normal fetuses was Conchal Crus, with a rate of 25.86% while the least observed was Constricted auricle, with a rate of 5.17%.

Keywords: fetus, auricle, morphology, anomaly

P152 - Absence of the right coronary artery: a rare coronary artery anomaly

Yusuf Güler¹, Yeşim Eroğlu¹, Pınar Demir Gündoğmuş²

¹Department of Radiology, Faculty of Medicine, Firat University, Elazığ, Türkiye

²Department of Anatomy, Faculty of Medicine, Hacettepe University, Ankara, Türkiye

Objective: Absence of the right coronary artery (RCA) is a rare coronary artery anomaly. The absence of RCA has been reported as a benign anomaly. However, early diagnosis is important as it may cause serious complications such as myocardial ischemia and sudden death. Coronary computed tomography (CT) angiography is a successful imaging method due to its high resolution in detecting coronary artery anomalies. In this report, we aimed to present the coronary CT angiography findings of a case with congenital RCA absence.

Case: The 52-year-old female patient, who applied with the complaint of chest pain, did not have any comorbidities. The physical examination was unremarkable. Electrocardiography and echocardiography were normal. Coronary CT angiography was performed on the patient whose exercise test was suspicious. Coronary CT angiography revealed the absence of RCA. The left main coronary artery was seen to arise normally from the left sinus of valsalva. It was observed that the left anterior descending artery and the left circumflex artery originated from the left main coronary artery normally. It was observed that the left circumflex artery distal branches extended towards the right atrioventricular groove and fed the RCA irrigation areas.

Conclusion: The prevalence of coronary artery anomalies in the general population is 1-2%. Since most of them are asymptomatic, they are detected incidentally. Coronary artery anomalies are classified as those that are hemodynamically important and those that are not. Absence of RCA is considered a benign congenital coronary artery anomaly. However, serious complications ranging from myocardial ischemia to sudden death can occur. Therefore, early diagnosis of coronary artery anomalies is extremely valuable in order to direct treatment. Coronary CT angiography is an effective imaging method in its diagnosis.

Keywords: right coronary artery, anomaly, coronary CT angiography

P153 - Lumbar spine visualization: An algorithmic approach to 3D printing for training and surgical planning

Aya Aldashash¹, Eda Sağıroğlu², Fatema Shaaban¹

¹Pi Health Technologies, Ankara, Türkiye

²Department of Anatomy, Faculty of Medicine, Lokman Hekim University, Ankara, Türkiye

Objective: Medical imaging modalities such as the Computer Tomography (CT), Magnetic Resonance Imaging (MRI) give us the opportunity to obtain 3D models of scanned data. 3D printed anatomical structures have been widely employed in a number of medical fields over the past 20 years, including orthopedics, cardiology, maxillofacial surgery, and forensic medicine. Additionally, transportation of cadavers is quite difficult due to high cost, transportation problems and legal difficulties. For these reasons, in this study, an algorithm for lumbar spine segmentation was created using MRI and CT scans. The segmented 3D models were then printed with a 3D printer in order to be used in education, training and surgical planning.

Methods: In this work, MRI images acquired from an open-source dataset on the internet were used. The developed hybrid method consists of using open-source software platforms such as ITK-Snap, 3D Slicer and OsiriX along with python programming language. The result of this method, was a 3D volume which could be saved in formats like Stereolithography (STL), Wavefront OBJ (OBJ) or Polygon File Format (PLY). The printing technique Fused Deposition Modeling (FDM) was employed, as it is one of the most prevalent and accessible 3D printing technologies.

Results: In the study, segmentation method was used to successfully identify the anatomical structure of the lumbar spine in MRI scans. Anatomical structures were visualized using 3D printing technology with the 3D volumes obtained. Visualization and 3D printing were performed for 5 vertebrae in the lumbar region.

Conclusion: The 3D lumbar vertebrae models obtained are an additional material that has the potential to be used together with atlases and digital resources in education. It is thought that this multidisciplinary study will be a source of inspiration for students and researchers.

Keywords: Magnetic resonance imaging, segmentation, 3D Printing

P154 - Digitalization of bone materials with 3D mobile scanning program and adaptation to anatomy education

Zehra Çelik¹, Mehmet Ülkir¹, Hasan Barış Ilgaz¹

¹Department of Anatomy, Faculty of Medicine, Hacettepe University, Ankara, Türkiye

Objective: In anatomy, 3D perception is a basic and important part of education, but the fact that the materials used are only accessible in the anatomy laboratory is a limiting factor for education. Creating an online library by making the 3D materials used in the anatomy laboratory will make anatomy education more accessible.

Methods: In this study, talus, calcaneus and patella dry bones were used, which were obtained from our laboratory. They were scanned with a mobile phone and tablet using a 3D scanning application (Qlone®, EyeCue Vision Technologies Ltd., 2017 - 2022 Version: 5.0.4) that combines multiple 2D video images and converts them into 3D models. 3D images were created by manually or automatically combining the repeated scan data. The 3D models were suitable for exporting, editing and freely moving the image. High-resolution 3D models in video, 3D sticker, GIF and various formats were exported and collected in a common cloud account. In addition, the models could be transferred to the external environment with the augmented reality option. The created online library was made available to those who studied anatomy.

Results: We tried to create a new and easily accessible 3D personal library, which was obtained in a short time with a limited number of models. In addition to the applications and materials used in anatomy education, the 360-degree 3D formats of the models used in the laboratory can provide an opportunity both for ease of access and to create their own database for anatomy laboratories. It can enable to make the laboratory education easily accessible from mobile devices.

Conclusion: New ideas and methods are included every day in anatomy education. With this easy and simple method, laboratories can share their cadaver, plastination materials and models can be made 3D shareable. In addition, the availability of augmented reality can enable almost the same laboratory environment to be moved to another environment.

Keywords: anatomy education, 3D model, augmented reality, Qlone®.

P158 - Does the radial groove really exist?

Nimet Ebrar Demircan¹, Mislina Utlu¹, Mehmet Ali Güner¹, Necdet Kocabıyık¹

¹Department of Anatomy, Gulhane Faculty of Medicine, University of Health Sciences, Ankara, Türkiye

Objective: The existence of radial groove in the humerus has been a subject of debate in the literature. The aim of this study was to examine the radial groove on bone and cadaver and to define its relationship with the radial nerve (RN).

Methods: Our study included 22 dry humerus and 11 cadavers. The radial groove in the posterior aspect of the humerus was examined. Cadavers were dissected. Relationship of the RN with the humeral periosteum and triceps muscle fibers was examined. The presence or absence of a visible groove on the humerus was evaluated. The groove was classified as palpable, slightly palpable and non-palpable.

Results: Of the 22 humerus, 31.8%(n=7) had a visible groove and 68.2%(n=15) did not have a visible groove. While the groove was slightly palpable in 40.0%(n=6) of the humerus without a visible groove, there was no finding that could be considered a groove in 60.0%(n=9). While 90.9%(n=10) of the RN in 11 cadavers were in direct contact with the humerus, 27.3%(n=3) had a muscle fiber between the RN and the humerus. When the RN was removed, only 18.2%(n=2) had a visible groove on the humerus, while 81.8%(n=9) didn't have a visible groove. Of those without a visible groove, 44.4%(n=4) had a slightly palpable groove, while 55.6%(n=5) had non-palpable groove. When the data obtained were analyzed statistically, no significant difference was found in terms of gender and side.

Conclusion: When the dry humerus and cadavers were examined, no obvious groove structure was observed in most of them. In addition, the RN was not always in direct contact with the humerus, and muscle fibers belonging to the triceps muscle were found in between. In conclusion, our study will contribute to a better understanding of the anatomy of the RN on the humerus for anatomists and surgeons.

Keywords: radial groove, radial nerve, humerus

P159 - The effect of using a smartphone on walking and balance

Metehan Pehlivan¹, Bülent Sabri Cıçalı¹

¹Department of Anatomy, Faculty of Medicine, Trakya University, Ankara, Türkiye

Objective: In this study, we aimed to reveal with objective criteria how much and in what direction using a smartphone affects walking and balancing while walking and standing, by using gait analysis and static balance analysis methods in selected healthy individuals.

Methods: This study was conducted with the participation of 30 healthy volunteers, 15 men and 15 women, aged between 18-25. After the volunteers' normal gait and balance measurements were recorded, they were asked to only read a predetermined text on their smartphones in one measurement, and in the other measurement, they were asked to only write the predetermined text. The volunteers' walking and balance analysis patterns were obtained using the force platform Zebris ©, DM System Type FDM 1.5 and the WinFDM computer program.

Results: The average age of the volunteers participating in the study was 24.3 ± 0.65 years. When the results were examined, significant differences were observed in many parameters of walking and static balance analysis between "normal" data and "reading" and "writing" measured using a smartphone. While significant differences were detected in some parameters of the gait analysis between the "reading" and "writing" data, no significant differences were observed in the static balance parameters.

Conclusion: The data we obtained in our study show that changing visual focus and divided attention changes walking and static balance in healthy individuals. We observed that the volunteers unknowingly tried to maintain their balance, especially in the medial-lateral direction, by widening their steps, taking shorter and slower steps, and extending the time they put both feet on the ground. The fact that these results change the most, especially during writing, shows that the degree of concentration of attention and the different tasks added have a more profound effect on walking.

Keywords: smartphone, gait analysis, balance analysis, proprioception

P160 - Morphometric features of the lateral plate of pterygoid process: A clinical correlation study

Ümmühan Yağmurkaya¹, Dilara Patat¹, Berin Tuğtağ Demir¹, Mehtap Nisari², Burak Bilecenoğlu¹

¹Department of Anatomy, Faculty of Medicine, Ankara Medipol University, Ankara, Türkiye

²Department of Anatomy, Faculty of Medicine, Erciyes University, Kayseri, Türkiye

Objective: The lateral plate of the pterygoid process (LPP) is located medial to the jaw joint, deep to the infratemporal fossa. The LPP plays a vital role in the coordination of jaw movements by attaching the masticatory muscles. In addition to its involvement in Le Fort fractures, it is reported to be affected in sphenotemporal buttress fractures, temporal bone fractures, zygomaticomaxillary complex fractures, displaced mandible and nasal bone fractures. Because of the close neighborhood of the LPP with the facial nerve and mandibular nerve, we aimed to evaluate its relationship with the points thought to affect these nerves (stylomastoid foramen [SMF], styloid process [SP]).

Methods: The study was performed on 41 skulls from the anatomy laboratories of Ankara Medipol University and Erciyes University Faculty of Medicine. Skulls with deformed skull base and missing reference points (LPP, SMF, SP, mastoid process [MP]) were excluded from the study. The shape of the SMF was determined; the distances between the SMF-LPP, SP-LPP and the two MPs were measured. Measurements were analyzed with SPSS for Windows 22.00.

Results: The FSM shape was found to be mostly round (59.53%). Right-side SMF-LPP distance was 33.98 ± 3.12 mm (minimum 27.84 mm, maximum 40.85 mm), SP-LPP distance was 28.33 ± 4.03 mm (minimum 18.19 mm, maximum 36.80 mm) and the distance between two MPs was 93.8 ± 4.73 mm (minimum 85.81 mm, maximum 107.63 mm).

Conclusion: Today, the frequent use of transpterygoid approaches for access to the fossa infratemporal fossa and parapharyngeal space has made it important to know the LPP and its distance to the surrounding structures. We believe that the knowledge of the distance of the LPP to the SMF and SP will shed light on the surgeons in terms of performing healthy access to the relevant region and minimizing the vascular-nerve interference during this access.

Keywords: lateral plate of the pterygoid process, styloid process, stylomastoid foramen

P161 - Morphometric evaluation of sagittal curvature in dry tibia bones

Merve Küçükler¹, Nazlı Ateş¹, Mehmet Ali Malas¹

¹Department of Anatomy, Faculty of Medicine, İzmir Katip Çelebi University, İzmir, Türkiye

Objective: The main purpose of our study is to investigate the sagittal curvature in the tibia bones morphometrically.

Methods: Our study included 48 dry tibia bones (21 right, 27 left) in our laboratory. The tibia bones were positioned proximally parallel to the transverse axial plane, passing through the midpoints of the upper surfaces of tibial condyles. Then, medial photographs of the tibia were taken. In the photographs, total tibia length, sagittal distances of the proximal, median, and distal regions of the tibia sagittal curvature to the coronal plane (H1-H7) and angles to the coronal plane (A1-A7) were measured with the Image J program.

Results: On average, the tibia length was 300 ± 31 mm, and there was no difference between the left and right sides ($p>0.05$). There was a significant difference between the sagittal distances of H1 and H7, H2 and H6, H3 and H5, which were the mirror image of the sagittal distances described for the proximal (H1, H2, H3) and distal tibia (H7, H6, H5) regions according to the median line ($p<0.001$). Sagittal distances were greater in the proximal region than in the distal region. The angles A1 and A7, A2 and A6, and A3 and A5 were mirror images of the angles described for the proximal and distal tibia regions; compared to the median line, a significant difference was found ($p<0.001$). Additionally, there were no differences between the sides in terms of sagittal distances and angular parameters.

Conclusion: Our study demonstrated the significant statistical difference, especially between the proximal and distal regions, in detail. Knowing the details of the tibial sagittal curvature will contribute positively to the treatment and healing process, especially in proximal tibia fractures and pathologies and in prosthetic and surgical applications applied to the tibia.

Keywords: tibia, sagittal curvature, morphometry, anatomy, tibial curvature

P162 - The parameters of Turkish population's tibial plateau

Didem Dönmez Aydın¹, Seher Mehmed¹, Sıdıka Akran¹, İlayda Şafak¹, Oğuz Taşkinalp¹

¹Department of Anatomy, Faculty of Medicine, Trakya University, Türkiye

Objective: The knee joint, a vital joint in the human body, enables us to perform various movements and activities and plays a crucial role in maintaining joint stability and facilitating proper movement. Tibial plateau refers to the upper surface of the tibia bone that articulates with the femur to form the knee joint. During weight transfer, it acts as a foundation that supports the weight of the body and efficiently distributes forces across the joint. In addition to the biomechanical importance of this region, morphometric parameters are very important in terms of prosthesis use. In our study, tibial plateau and morphometric measurements were performed.

Methods: In accordance with anatomical posture, the dry bones were separated into right and left. The study included 20 tibiae with normal morphologic characteristics. A digital caliper was used to measure 10 different parameters in mm. There is no information about the genders. Antero-posterior diameters and right-left diameters of medial and lateral epicondyles, tibial plateau width and length, width and length of anterior and posterior intercondylar areas were measured.

Results: The average measurements are as follows: lateral epicondyle right left diameter 22.76mm, lateral epicondyle anterior posterior diameter 34.27mm, medial epicondyle anterior posterior diameter 41.40mm, tibial plateau width 69.09mm, tibial plateau anterior posterior diameter 43.55mm, anterior and posterior intercondylar areas' width 22.50mm, and length 420.08mm. Our findings are in line with earlier research. There are some variations among other populations, though. More information is required at this time in order to compare results.

Conclusion: For medical professionals and potential patients, it's crucial to comprehend the morphometry of the tibial plateau and the injuries that can happen here. By adding more parameters and bones, the study will be expanded. These measurements are also crucial for enhancing the quality of life in studies on orthotics and prosthetics.

Keywords: tibia, tibial plateau, Turkish population, morphometry, prosthesis

P167 - Morphological investigation of the importance of incisive foramen in maxillary surgery

Hilal Melis Altıntaş¹, Simge Eşme¹, Berin Tuğtağ Demir¹, Mehtap Nisari², Burak Bilecenoğlu¹

¹Department of Anatomy, Faculty of Medicine, Ankara Medipol University, Ankara, Türkiye

²Department of Anatomy, Faculty of Medicine, Erciyes University, Kayseri, Türkiye

Objective: Incisive foramen is the lower opening of the canal connecting the oral cavity to the nasal cavity. Placing an implant in the anterior region of the maxilla is a challenging procedure for clinicians because this region is an important region in terms of functional and aesthetics. It is extremely important to evaluate the position and shape of the Incisive foramen before placing an implant. Therefore, in our study, we aimed to evaluate the morphometric properties, location and relationship of incisive foramen with other anatomical structures.

Methods: The study was conducted at Ankara Medipol University and Erciyes University Faculty of Medicine, Department of Anatomy. 32 dry skulls were used in the study. In the research, the width, length, height and shape of the incisive foramen; the distance between the incisive foramen and posterior nasal spine, the distance between the front incisors and the incisive foramen, and the distance between the incisive foramen and the greater palatine foramen and lesser palatine foramens were measured.

Results: The highest distance value between incisive foramen and posterior nasal spine was found to be 45 mm. The maximum linear distance value between the incisive foramen and the front incisors was measured as 10 mm on the right side and 9 mm on the left side. The average distance between greater palatine foramen and incisive foramen on the right side was calculated as 35.29 mm and on the left side was 33.14 mm.

Conclusion: There are concerns about the long-term consequences of implants that are in contact with structures passing through the incisive foramen. It is necessary to determine the bone morphology and the position and dimensions of the hole and determine the correct placement before implantation. Anatomical variability in dimensions may be clinically important during surgical procedures, particularly immediate implant placement.

Keywords: incisive foramen, dry skull, clinical correlation

P169 - Coexistence of Seckel syndrome and neurogenic bladder: Case report

Elif Sena Ozcan¹, Sevim Yener², Metin Esen³, Nurullah Yucel⁴

¹Department of Anatomy, Institute of Health Sciences, University of Health Sciences, Istanbul, Türkiye

²Department of Pediatric Urology, Istanbul Umraniye Training and Research Hospital, Istanbul, Türkiye

³Department of Medical Genetic, Istanbul Umraniye Training and Research Hospital, Istanbul, Türkiye

⁴Department of Anatomy, Hamidiye Faculty of Medicine, University of Health Sciences, Istanbul, Türkiye

Objective: Seckel syndrome is a rare autosomal recessive disease without any gender. Microcephaly, short stature and mental retardation are most common symptoms. In this study, relevant patient's symptoms diagnosed with Seckel syndrome were examined.

Case: The case is a female patient who was born on 19.09.2005, was diagnosed with neurogenic bladder, underwent bilateral VUR (Vesicourethral Reflux) operation, and followed up by urology and nephrology. Patient has mental motor retardation, malnutrition, difficulty swallowing. There isn't consanguineous marriage in his family history. According to DMSA (Dimercaptosuccinic acid) result, right kidney is functioning at 3% and compatible with atrophic kidney tissue. Abdominal USG performed upon examinations requested from patient, a normal kidney appearance wasn't detected in right kidney area, and a suspicious appearance for atrophic kidney draws attention. There is an appearance consistent with compensatory hypertrophy in left kidney. Widespread millimetric calcifications are observed in liver. Uterus is observed variably in left pararectal area. Rotoscoliosis is observed in shape of "S" with opening in thoracic axis facing left and in lower lumbar region facing right. Loss of ventilation and sclerosis were detected in both mastoid cells, it appeared obliterated with soft tissue. Erosion was observed in ossicles on left. There is enlargement of lateral and third ventricle consistent with hydrocephalus. Herniation of cerebellar tonsils from foramen magnum towards inferior was observed. Corpus callosum looks thin. Findings are significant in terms Chiari's malformation.

Conclusion: Examinations, patient's findings and genetic test result show that our case is a patient with Seckel syndrome. Syndrome, which are rarely detected in literature, focus is mostly on short stature, microcephaly, characteristic facial shape, dental diseases, neurological findings. In our case, in addition to neurological findings, other symptoms such as urology and nephrology findings, liver diseases, scoliosis were also observed.

Keywords: Seckel syndrome, rare syndromes, pediatric diseases, urology, nephrology

P171 - Bibliometric analysis of anatomy doctoral theses in Türkiye

Bedrettin Çinpolat¹, Meltem Açar Güdek¹

¹Department of Anatomy, Faculty of Medicine, Tokat Gaziosmanpaşa University, Tokat, Türkiye

Objective: This study aimed to analyze doctoral thesis research conducted in the Department of Anatomy at higher education institutions in Turkey. The data collected included the distribution of studies by year, the gender of the authors, the titles of the advisors, the universities where the studies were conducted, the general topics and research methods preferred in the studies.

Methods: This study investigated doctoral and specialization theses in the Department of Anatomy at higher education institutions in Turkey between 1969 and 2023, using keywords to access the theses on the official website of the Council of Higher Education's National Thesis Center. It was found that a total of 716 doctoral theses (510 doctoral, 206 specialization in medicine) were prepared. However, only 530 anatomy doctoral theses that were accessible were included in the study. The data related to the theses (university where they were prepared, year of publication, gender of the authors and advisors, field of study of the thesis, etc.) were recorded in the Microsoft Office Excel computer program and evaluated numerically.

Results: According to the data obtained as of September 2023, 384 of the 530 anatomy doctoral theses published and publicly accessible are doctoral theses, while 146 are specialization theses in medicine. The authors consist of 282 male and 248 female authors. Of the thesis advisors, 392 are male and 132 are female, and no advisor information was given in 6 theses. When the titles of the advisors are examined, 375 are professors, 126 are associate professors, and 23 are assistant professors. The first five universities with the highest number of doctoral theses are Hacettepe (49), Erciyes (39), Ankara (34), Istanbul (32), and Selcuk (24), respectively. The research areas of the theses are mainly radiological studies (141), followed by cadaver studies (133), experimental animals (114), clinical studies (66), and anthropometric studies (41).

Conclusion: Findings showed that the majority of authors and supervisors of anatomy doctoral theses in Turkey were male, and the majority of supervisors were professors. Digital image recordings were the most frequently used data collection tool in theses. Based on the findings, we believe that it would be beneficial to make all theses uploaded to the National Thesis Center fully accessible, to investigate similar theses conducted abroad, and to follow current topics.

Keywords: bibliometric research, anatomy thesis topics, anatomy doctoral thesis

P172 - Anatomical structures in the rare genetic disease Wolfram syndrome: A case report

Rabia Solak Döner¹, Sevim Yener², Papatya Keleş³, Nurullah Yücel³

¹Department of Anatomy, Faculty of Medicine, Istanbul Aydin University, Istanbul, Türkiye

²Department of Pediatric Urology, Umraniye Training and Research Hospital, University of Health Sciences, Istanbul, Türkiye

³Department of Anatomy, Hamidiye Faculty of Medicine, University of Health Sciences, Istanbul, Türkiye

Objective: Wolfram syndrome is a rare neurodegenerative disease transmitted in an autosomal recessive manner. It is a rare disease that affect approximately 1 in 160,000-770,000 people. This syndrome is characterized by diabetes insipidus (DI), diabetes mellitus (DM), optic atrophy (OA), and sensorineural hearing loss (D) (DIDMOAD). The clinical picture may be complicated by other symptoms such as urinary tract, endocrinological, psychiatric and neurological abnormalities. The aim of our study is to reveal the findings regarding the anatomical structures of a case diagnosed with this rare genetic disorder.

Case: The case is a 19-year-old girl. There is no consanguinity between their parents. Type 1 diabetes mellitus, optic atrophy and a significant increase in bladder wall thickness and trabeculation have been observed. Hearing ability was normal and diabetes insipidus was not observed. No abnormality was observed in cardiological examinations and magnetic resonance (MR) imaging results. This case is interesting due to the absence of consanguineous relationships within the family and the absence of hearing loss and diabetes insipidus. Additionally, the fact that the patient has epilepsy makes the clinical picture even more complicated.

Conclusion: Patients with Wolfram syndrome are usually affected by symptoms in this order: diabetes mellitus and optic atrophy in the first, diabetes insipidus and sensorineural hearing loss in the second, and urinary tract and neurological abnormalities in the third decade. Patients with Wolfram syndrome usually die in the early third or fourth decade due to central respiratory failure due to brainstem atrophy. It is noteworthy that in this case, although the patient reached the end of the second decade, hearing loss and diabetes insipidus were not observed. This case highlights the complex clinical presentation of Wolfram Disease, demonstrating the importance of multidisciplinary evaluation in its diagnosis. More research is needed to better understand the genetic and pathophysiological mechanisms of Wolfram Disease.

Keywords: Wolfram syndrome, diabetes mellitus, optic atrophy, diabetes insipidus, sensorineural deafness.

P173 - Evaluation of foramen lacerum morphometry on brain computed tomography images with 3D slicer method

Merve Muslu¹, Ömür Karaca¹

¹Department of Anatomy, Faculty of Medicine, Balıkesir University, Balıkesir, Türkiye

Objective: The foramen lacerum (FL) at the base of the skull is the safest way to approach the internal carotid artery and pterygoid canal in cases requiring surgical intervention. In our study, we aimed to reveal the FL and its relationship with the related surrounding structures by morphologic and morphometric measurements.

Methods: In this study, image series of 77 patients (42 females, 35 males) who underwent 3D brain computed tomography (CT) for various reasons at Balıkesir University Faculty of Medicine, Department of Radiology were used. FL types were determined and measurements were made on the images with 3D Slicer computer software program.

Results: The mean age of the women was 46.79 ± 14.60 years and the mean age of the men was 47.60 ± 17.61 years. Right and left FL types were determined. Accordingly, four types of FL were identified as Type 1 (normal FL), Type 2 (canal FL), Type 3 (bridged FL) and Type 4 (absence of FL). Right FL types were found to be 70.1%, 15.6% and 14.3% in the above order. Left FL type rates were 72.7%, 11.7% and 15.6%. Type 4 was not observed in our study. Right FL length was 9.76 ± 1.52 cm in women and 10.62 ± 1.53 cm in men, and left FL length was 9.97 ± 1.36 cm in women and 10.69 ± 1.34 cm in men. Right FL width was 8.44 ± 1.23 cm in women and 8.63 ± 1.34 cm in men, and left FL width was 8.09 ± 1.12 cm in women and 8.70 ± 1.30 cm in men. Right and left FL length and left FL width were higher in men than in women ($p < 0.05$).

Conclusion: In the field of medicine, it is important to be aware of individual variations rather than generalizations in order to make accurate diagnoses and direct patients to the right treatments. Therefore, morphometric analysis of FL will contribute to anatomists, clinicians and the literature in terms of determining safe interventional routes in cases requiring surgical intervention in these regions.

Keywords: foramen lacerum, pterygoid canal, internal carotid artery, morphometry

P174 - The relationship between the infraorbital nerve and the periorbita

Elif Çelik¹, Necati Salman², Simel Kendir¹, Nihal Apaydın¹, S. Tuna Karahan¹

¹Department of Anatomy, Faculty of Medicine, Ankara University, Ankara, Türkiye

²Department of Anatomy, Faculty of Medicine, Sağlık Bilimleri University, Ankara, Türkiye

Objective: The periosteum, also known as the periorbita, covers the orbit. This layer serves as an attachment point for tendons, ligaments, and muscles as well as support for blood supply to the orbital bones. Different descriptions of this link between the periorbita and the infraorbital nerve can be found in the literature. The degree of the infraorbital nerve participation in inflammation and tumor spread depends on this relationship. Additionally, it also determines the iatrogenic spread of inflammation to the periorbital region in interventions to the infraorbital nerve. This study's objectives are to identify the infraorbital foramen's position for interventions and to demonstrate the association between the infraorbital nerve and the periorbita from this perspective.

Methods: The study was performed bilaterally on three cadavers. The relationship of the infraorbital nerve with the periorbita from the superior orbital fissure to the infraorbital foramen was analyzed. To determine the position of the infraorbital foramen, the vertical distance between the margo infraorbitalis, the infraorbital foramen and the horizontal distance between the mid-sagittal line passing through the radix nasi and the infraorbital foramen were measured. Additionally, the infraorbital foramen's diameter, the angle between the infraorbital nerve and the mid-sagittal line at its departure were measured. A digital caliper was used to measure distances in millimeters (mm).

Results: The morphometric characteristics of the infraorbital nerve and infraorbital foramen were examined in this anatomical investigation. The margo infraorbitalis and infraorbital foramen were separated by a mean vertical distance of 6.4 mm, a mean horizontal distance of 30.1 mm, respectively. Between the orbit and the surrounding periorbita, the infraorbital nerve moved.

Conclusion: Because it is located outside the periorbita, we think that the infraorbital nerve will be better protected against inflammation or tumor invasion that may develop inside the periorbita.

Keywords: infraorbital nerve, periorbita, infraorbital foramen

P184 - The contribution of 3D tibia modeling to anatomy education: How successful is it?

Aslı Beril Karakaş¹, Figen Gökmen², Mehmet Asım Özer²

¹Department of Anatomy, Faculty of Medicine, Kafkas University, Kars, Türkiye

²Department of Anatomy, Faculty of Medicine, Ege University, İzmir, Türkiye

Objective: Anatomy education is a fundamental component of medical and healthcare curricula, providing students with a foundational understanding of human anatomy. Traditional teaching methods often rely on two-dimensional illustrations and cadaveric dissections. However, recent advancements in technology have introduced innovative approaches to anatomy education, including the use of three-dimensional (3D) modeling. This study aims to investigate the efficacy of 3D tibia modeling in enhancing anatomy education.

Methods: The study included 104 medical students who were randomly assigned to two groups: the control group (n=52) and the experimental group (n=52). The control group received traditional anatomy education on the tibia using textbooks, two-dimensional illustrations, and cadaveric dissections. The experimental group, on the other hand, was provided with specially printed 3D tibia models designed for this study. To assess the effectiveness of 3D tibia modeling, both groups underwent a pre-test and a post-test focusing on questions related to tibia anatomy, requiring the identification of various structures and their functions.

Results: Before any intervention, both groups displayed a similar baseline knowledge of tibia anatomy, with no statistically significant differences ($p > 0.05$). However, after the intervention, the experimental group, which practiced with 3D tibia models, exhibited significantly higher scores on the post-test compared to the control group ($p < 0.01$). Students appreciated the ability to manipulate the model, explore anatomical structures from different angles, and engage in self-assessment.

Conclusion: This study demonstrates that integrating 3D tibia modeling into anatomy education significantly enhances students' understanding of tibia anatomy compared to traditional teaching methods. The interactive and dynamic nature of 3D modeling engages students and promotes active learning. Additionally, it allows for repetitive practice, which is crucial for reinforcing anatomical knowledge. However, while 3D models contribute to anatomy education, traditional methods such as observing structures on cadavers still hold significant value.

Keywords: three-dimensional modeling, tibia, anatomy education, survey.

P186 - Bardet-Biedl syndrome: Case report

Cansu Kibar¹, Ozge Coskun¹, Sevim Yener², Papatya Keles³, Nurullah Yucel³

¹Department of Anatomy, Faculty of Medicine, Istanbul Arel University, Istanbul, Türkiye

²Clinic of Pediatric Urology, Umraniye Training and Research Hospital, Sağlık Bilimleri University, Istanbul, Türkiye

³Department of Anatomy, Faculty of Medicine, Sağlık Bilimleri University, Istanbul, Türkiye

Objective: Bardet-Biedl syndrome (BBS) is characterized by obesity, polydactyly, visual disturbances, renal malformation, learning disabilities and hypogonadism. BBS is an autosomal recessive disorder. It is usually diagnosed in childhood. The prevalence is between 1/125,000 and 1/175,000 in Europe. One fourth of BBS cases are caused by mutations in the BBS1 gene and 20 percent in the BBS10 gene. In this study, we aimed to present the findings of anatomical structures related to this rare syndrome in the clinic.

Case: A 6-year-old boy was born by cesarean section weighing 3190 g. He had polydactyly of both toes and fingers at birth. Rapid weight gain started at the age of 3 years and was diagnosed as obesity. Hypogonadism was diagnosed as a result of micropenis. Retinal dystrophy, myopia and astigmatism were detected. Echocardiography revealed patent foramen ovale and mild hypertrophy of the interventricular septum. Urinary system ultrasonography revealed normal size and parenchymal thickness of both kidneys. Kidney contours are lobulated. Medullary calcinosis was found in both kidneys. He is behind his age in language-cognitive skills and fine motor development. Gross motor, general development and social skills are age appropriate.

Conclusion: The findings of the examinations indicate that the patient is a patient with the rare Bardet-Biedl syndrome. BBS should be considered in cases of obesity and polydactyly and renal function should be closely monitored after the diagnosis is made because it is responsible for mortality.

Keywords: Bardet-Biedl syndrome, polydactyly, anatomy

P187 - Anatomy and functional effects of the human microbiota; an examination related to the vagus nerve

Hüseyin Güzey¹, Rukiye Öncel¹, Zehra Çelik¹, M. Mustafa Aldur¹

¹Department of Anatomy, Faculty of Medicine, Hacettepe University, Ankara, Türkiye

Objective: This research aims to comprehend the intricate relationships within the human microbiota and the mechanisms by which it communicates signals to the brain, primarily via the vagus nerve. Furthermore, the study focuses on how this interaction influences cognitive processes and its potential links with specific neurological ailments.

Methods: While formulating this comprehensive review, articles published over the past 15 years on the platforms of PubMed, Scopus, and Web of Science were considered. Our research is based on specific keywords. Notably, invaluable information obtained from the second phase of the Human Microbiome Project, which focuses on the microbiota and associated diseases, was also utilized.

Results: The human body plays host to a vast and diverse microbial community, most densely populated within the intestines, notably the colon. These microbial communities are also found on our skin, within our oral cavity, respiratory tracts, and urogenital regions. These microorganisms, primarily through the vagus nerve, establish a bridge between the enteric and central nervous systems, enabling communication with the brain. Contemporary studies have elucidated the association of dysbiosis with depression, anxiety, multiple sclerosis and neurodegenerative diseases such as Alzheimer's. It has been demonstrated that these microbial imbalances have overarching effects on our physiological learning capacities, memory retention, and stress responses.

Conclusion: Research has clearly illustrated the profound impacts of the gut-brain axis, facilitated majorly through the vagus nerve, on brain functions and overall health trajectories. This bi-directional communication presents a promising avenue for therapeutic interventions, especially for neurological and mental health challenges. A holistic understanding of the neural pathways influenced by microbiota with established neurological repercussions will undeniably steer future research directions.

Keywords: human microbiota, vagus nerve, gut-brain axis, dysbiosis

P190 - The importance of the anatomical neighborhoods of the cervix and upper vagina to avoid colpotomy complications due to the increased V-NOTES surgery: A case report

Ali Can Gunes¹, Burcu Ercakmak Gunes²

¹Department of Obstetrics and Gynecology, Mamak State Hospital, Ankara, Türkiye

²Department of Anatomy, Faculty of Medicine, Hacettepe University, Ankara, Türkiye

Objective: Colpotomy practice in the old era of gynecological surgery (mostly posterior colpotomy); It is limited to a few case types such as tubal ligation, salpingectomy or vaginal hysterectomy. One of the most important developments in gynecological surgery, which has entered a new era with the introduction of endoscopic surgery, is V-NOTES surgery. V-NOTES (Vaginal-Natural Orifice Endoscopic Surgery) has made it possible to perform laparoscopy through the vaginal route. Recently, with the widespread use of V-NOTES surgery, the number of colpotomy required to reach the pelvic organs has also increased. This increases the importance of the anatomical neighborhoods of the cervix and upper vagina required to avoid colpotomy complications. In this case report, it is aimed to emphasize the importance of the anatomical neighborhoods of the cervix and upper vagina during colpotomy with a case in which bilateral tubal ligation was performed with V-NOTES.

Case: A 38-year-old patient with gravida 3 parity 3 living 3 applied to our clinic with a request for tubal ligation. The pelvic and abdominal examinations were normal. The patient's preoperative preparations were completed and the abdomen was entered via posterior colpotomy and bilateral tubal ligation was performed using V-NOTES. The patient was discharged without complication at the 6th post-operative hour.

Conclusion: V-NOTES technique has become a widely used method day by day due to reasons such as no scar on the anterior abdominal wall, surgery being performed through the vagina, which is a natural opening, and rapid recovery. Since in this technique, the abdomen is entered through colpotomy, mostly from the posterior, it has become more important to know the anatomical neighborhoods of the cervix and upper vagina well in order to avoid complications such as bowel, bladder and large vessel damages.

Keywords: case report, V-NOTES, colpotomy, cervix, upper vagina, anatomical neighborhood

P191 - Examination of distal femur morphometry in various parameters

Hilal Kıran¹

¹Department of Anatomy, Faculty of Medicine, Eskişehir Osmangazi University, Eskişehir, Türkiye

Objective: The femur, the human body's largest bone, connects the hip joint at its upper end and forms part of the knee joint at its lower end. In biological and forensic anthropology studies, the researcher presented quantitative and qualitative data to identify femur differences based on factors like population, gender, and age. In orthopedic research, understanding the distal femur's morphometry is crucial for designing knee joint prostheses, including total knee arthroplasty. The intercondylar notch within the knee joint, a vital anatomical structure, plays a pivotal role in knee stability, particularly in ligament function, and is associated with knee injuries like ACL tears.

Methods: This study used 79 femurs of unknown age and gender from Eskişehir Osmangazi University's anatomy laboratory. Measurements included femoral length (FL), intercondylar notch width (NW), intercondylar notch depth (ND), and bicondylar width (BW). The intercondylar notch was classified into three types: type A, type U, and type M. All measurements were taken by a single person using a digital caliper accurate to 0.1 mm. Data were analyzed using the JAMOV program.

Results: Measurements revealed an average FL of 428 mm, average NW of 20.5 mm, average ND of 28.5 mm, and average BW of 80 mm. Among the notch shapes, 24 were type A (30.4%), 28 type U (35.4%), and 27 type M (34.2%). Strong correlations were observed among all metric measurements ($p < 0.01$, $p < 0.001$). Type A had a significantly smaller NW value compared to the other types ($p < 0.01$ for type M, $p < 0.001$ for type U).

Conclusion: Understanding distal femur shape and morphometric characteristics is crucial for comprehending knee joint mechanics. This study highlighted variations in distal femur morphology, with implications for knee prosthesis design, osteoarthritis diagnosis, and cruciate ligament surgeries.

Keywords: distal femur, morphometry, fossa intercondylaris

P192 - Endoscopic transorbital approach to the skull base: Anatomical landmarks and clinical applications

Hilal Akdemir Aktaş¹

¹Department of Anatomy, Faculty of Medicine, Hacettepe University, Ankara, Türkiye

Objective: Endoscopic transorbital approach (ETA) has become increasingly popular in recent years because it allows access to various parts of the skull base through orbit. This approach can be used alone or in combination with other approaches in skull base surgeries. It is frequently preferred in treatment of meningioma, schwannoma, dermoid cyst and chondrosarcoma pathologies. The aim of this study was to determine the important anatomical landmarks in ETA and to review the clinical applications of this approach.

Methods: Google scholar, Pubmed and Web of science databases were used to search recent articles about ETA and the articles were analysed in detail.

Results: ETA can start from 4 different regions of orbit: 1. Superior eyelid crease, 2. Precaruncular, 3. Lateral retrocanthal, 4. Preseptal lower eyelid. Superior eyelid crease approach is the commonest approach used in ETA. Superior orbit, frontal sinus, anterior cranial fossa and anterior skull base can be reached by this route. In precaruncular approach, a direct and avascular route is followed through the medial part of orbit. Medial orbital roof, orbital plate of ethmoid bone, ethmoidal arteries, cavernous sinus, internal carotid artery, optic nerve and anterior skull base can be reached by this approach. In lateral retrocanthal approach, deep lateral orbit, lateral part of anterior cranial fossa, middle cranial fossa, infratemporal fossa and temporal fossa can be reached. The preseptal approach is a route commonly used to reach the inferior orbit. Orbital floor, maxillary sinus, inferior orbital fissure and foramen rotundum can be reached in this approach. Important anatomical landmarks frequently used for craniectomy in ETA are superior orbital fissure, inferior orbital fissure and greater sphenoidal wing. The other anatomical landmarks are temporalis muscle, medial orbital wall, lateral orbital wall, ethmoidal arteries, lesser wing, meningo-orbital band, frontozygomatic suture, anterior clinoid process, optic canal and optic nerve.

Conclusion: ETA may be preferred to reach the skull base because it requires less soft tissue dissection and provides a shorter corridor.

Keywords: endoscopy, orbit, transorbital, skull base, anatomy

P193 - Anatomical landmarks for craniomaxillofacial deformities and cleft lip and palate

Ceren Günenç Beşer¹

¹Department of Anatomy, Faculty of Medicine, Hacettepe University, Ankara, Türkiye

Objective: Cleft lip and palate (CLP) is caused by a defect in the primary fusion of the craniofacial protrusions that form the primary and secondary palates at 5th-12th weeks. CLP may include the lip, alveolus, primary and/or secondary palate. It may be unilateral, bilateral or at the median plane. It can be subdivided as complete, incomplete or submucous. In this article, the types of CLP and which anatomical structures are affected by each type are explained.

Methods: Using Google Scholar, Pubmed and Web of Science databases, articles on cleft palate and lip were evaluated and a review was prepared, focusing on important anatomical structures.

Results: Philtrum, columella, cupid's bow are the main structures that can be interrupted in the cleft lip. Buccolabial muscle group, especially orbicularis oris and direct lip tractors are of particular importance. In cleft palate, alveus, primary and secondary palate, soft palate muscles may be affected at different levels in different types. Incisive foramen is a landmark in separating primary and secondary palate. The most affected muscles in cleft palate are levator veli palatini, tensor veli palatini and uvula and velopharyngeal insufficiency and middle ear pathologies may occur. The face is formed by the union of a frontonasal protrusion at midline and lateral nasal, maxillary and mandibular protrusions on both sides. While the infranasal depression, forehead, middle part of the nose and the upper lip, philtrum, septum, primary palate are developed from the frontonasal protrusion, nasal wings are developed from lateral nasal prominences. The upper cheek, lateral upper lip, maxilla and secondary palate are developed from maxillary protrusions, and the lower cheek, lower lip, jaw and submental area, a part of the middle ear and the front 2/3 of the tongue are developed from the mandibular prominences.

Conclusion: CLP can be seen as overt, submucous or occult. Clinicians should be careful about submucous (triple defect is observed) and occult types, which are common but can be missed in the clinic. It is essential that plastic surgeons have detailed knowledge of the anatomy of this region for CLP repair.

Keywords: cleft lip palate, submucous, levator veli palatini, velopharyngeal insufficiency